



THE UNIVERSITY *of* EDINBURGH

Edinburgh Research Explorer

Retrospective analysis of esophageal imaging features in brachycephalic vs. non-brachycephalic dogs based on videofluoroscopic swallowing studies

Citation for published version:

Eivers, CR, Chicon, R, Liuti, T & Salavati, S 2019, 'Retrospective analysis of esophageal imaging features in brachycephalic vs. non-brachycephalic dogs based on videofluoroscopic swallowing studies', *Journal of Veterinary Internal Medicine*. <https://doi.org/10.1111/jvim.15547>

Digital Object Identifier (DOI):

[10.1111/jvim.15547](https://doi.org/10.1111/jvim.15547)

Link:

[Link to publication record in Edinburgh Research Explorer](#)

Document Version:

Publisher's PDF, also known as Version of record

Published In:

Journal of Veterinary Internal Medicine

General rights

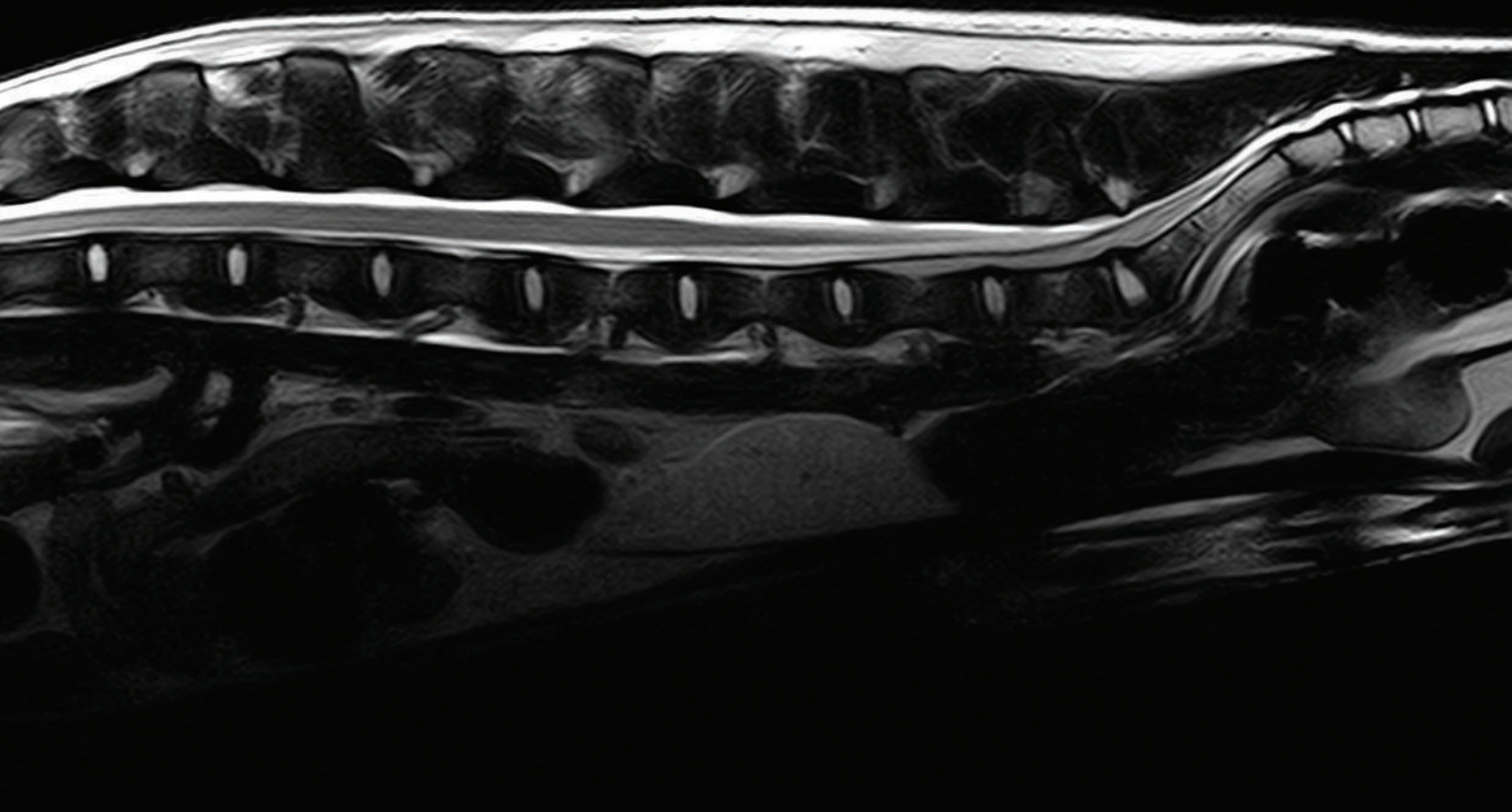
Copyright for the publications made accessible via the Edinburgh Research Explorer is retained by the author(s) and / or other copyright owners and it is a condition of accessing these publications that users recognise and abide by the legal requirements associated with these rights.

Take down policy

The University of Edinburgh has made every reasonable effort to ensure that Edinburgh Research Explorer content complies with UK legislation. If you believe that the public display of this file breaches copyright please contact openaccess@ed.ac.uk providing details, and we will remove access to the work immediately and investigate your claim.



/// Sagittal T2W Canine Spine ///



MRI THAT FITS YOUR PATIENTS AND YOUR PRACTICE.

Veterinary specific coils and sequences deliver superior images.

Learn more at hallmarq.net or contact us on petvet@hallmarq.net

The PetVet 1.5T high field MRI is affordable and always ready for clinical use.

- Virtually no downtime
- No routine helium refills
- No RF shielded room required

STANDARD ARTICLE

Retrospective analysis of esophageal imaging features in brachycephalic versus non-brachycephalic dogs based on videofluoroscopic swallowing studies

Caroline Eivers  | Rocio Chicon Rueda | Tiziana Liuti | Silke Salavati Schmitz 

Hospital for Small Animals, Royal (Dick) School of Veterinary Studies and The Roslin Institute, University of Edinburgh, Midlothian, UK

Correspondence

Silke Salavati Schmitz, University of Edinburgh, Royal (Dick) School of Veterinary Studies and The Roslin Institute, Hospital for Small Animals, Easter Bush, Midlothian, UK.
Email: silke.salavati@ed.ac.uk

Abstract

Background: Idiopathic esophageal dysmotility (ED) is increasingly recognized in young dogs of brachycephalic breeds. Few studies have objectively associated specific videofluoroscopic swallowing study (VFSS) features with brachycephaly, leading to under-recognition of ED in brachycephalic breeds.

Hypothesis/objectives: To describe and compare VFSS in brachycephalic dogs versus non-brachycephalic dogs presented for dysphagia or regurgitation, and to investigate associations between these imaging findings and patient signalment.

Methods: Retrospective analysis of VFSS of dogs presented for dysphagia or regurgitation (not megaesophagus) from 2006 to 2017. Cases were divided into brachycephalic and mesaticephalic breeds. The VFSS were reviewed using a standardized protocol by 2 examiners. Esophageal motility was assessed using specific criteria, and particular imaging features were noted and graded. Fisher's exact test was used to determine associations among signalment (including brachycephaly), final diagnosis, outcomes, and ED features.

Results: Thirty-six dogs were included (n = 10 normal, n = 26 presumed ED). Twenty dogs (77%) with presumed ED were brachycephalic with a median age of 1 year (range, 0.2-10.5 years). Most common were prolonged esophageal transit time (ETT; n = 21/26), decreased propagation of secondary peristaltic waves (n = 20/26), and gastroesophageal reflux (GER; n = 18/28). Eight dogs (all brachycephalic) had hiatal herniation (HH). Morphological esophageal variations were only observed in brachycephalic dogs. Brachycephaly was significantly associated with ED ($P = .005$), prolonged ETT ($P = .41$), GER ($P = .02$), and HH ($P = .03$).

Abbreviations: BOAS, brachycephalic obstructive airway syndrome; ED, esophageal dysmotility; ETT, esophageal transit time; GER, gastroesophageal reflux; GERD, gastroesophageal reflux disease; GEJ, gastroesophageal junction; GI, gastrointestinal; HH, hiatal herniation; HRE, hyper-regenerative esophagopathy; LES, lower esophageal sphincter; VFSS, videofluoroscopic barium swallowing studies.

This is an open access article under the terms of the Creative Commons Attribution-NonCommercial License, which permits use, distribution and reproduction in any medium, provided the original work is properly cited and is not used for commercial purposes.

© 2019 The Authors. *Journal of Veterinary Internal Medicine* published by Wiley Periodicals, Inc. on behalf of the American College of Veterinary Internal Medicine.

Conclusions and Clinical Importance: The majority of dogs with presumed ED was young and brachycephalic and had specific abnormalities that were less frequent in mesocephalic dogs with regurgitation or dysphagia.

KEYWORDS

barium sulfate, brachycephalic obstructive airway syndrome, esophageal dysmotility, gastroesophageal reflux disease, hiatal hernia

1 | INTRODUCTION

Esophageal motility disorders in dogs are poorly defined and infrequently reported, largely in part because of limited quantitative and qualitative data on normal esophageal function in this species. Esophageal dysmotility (ED) has been described as secondary to congenital or acquired luminal obstruction, esophagitis (often caused by gastroesophageal reflux [GER]), hiatal herniation (HH), diverticula, or fistulas.¹⁻⁶ It can be present in combination with or possibly caused by idiopathic or immune-mediated conditions such as laryngeal paralysis⁷ or muscular dystrophy in the bouvier des Flandres.⁸ There also are reports of idiopathic or “primary” forms of ED, suspected to be caused by breed-specific variations, congenital pathology, or familial disease.^{3,5,6,9} Disturbed motor function or delayed maturation have been proposed as possible causes in these dogs.^{5,9} Imaging findings in dogs with ED are variable, based on the underlying disease, and include morphological abnormalities such as a redundant esophagus, stenosis, stricture, or diverticula as well as functional abnormalities such as ineffective peristaltic waves, bolus retention, prolonged transit time, retrograde esophageal contractions, and GER.^{1,10}

We have noted subjectively an increase in the number of young brachycephalic dogs presenting for investigation of regurgitation, dysphagia, or both without overt megaesophagus, and with and without overt signs of airway disease. In addition to a high prevalence of endoscopic gastrointestinal (GI) tract lesions previously reported in brachycephalic dogs with brachycephalic obstructive airway syndrome (BOAS),¹¹ delayed esophageal transit time (ETT), GER, HH, and redundant esophagus also have been reported to be associated with these breeds.⁶ Sliding HH has been reported previously in several brachycephalic dogs, including the Bulldog, French Bulldog, Pug, Chow Chow, and Chinese Shar Pei.^{2,3,6,11-14}

Videofluoroscopic barium swallowing studies (VFSS) are considered the gold standard diagnostic tool for the assessment of esophageal motility and HH in people¹⁵ and in small animals.^{1,10} Limited information is available about VFSS in dogs, particularly in brachycephalic breeds, which is likely a result of limited availability in nonreferral centers and cost.¹⁰ When VFSS are performed in conscious dogs in an upright position, normal airway pressures are maintained which provides a physiologically accurate representation of swallowing function.¹⁶ Videofluoroscopic barium swallowing studies allow both real-time and post-acquisition evaluation (eg, assessment in slow motion or by individual frames) by multiple observers, which likely increases diagnostic accuracy.

Our purpose was to analyze VFSS performed at the Hospital for Small Animals (University of Edinburgh, United Kingdom) to report the quantitative and qualitative findings in dysphagic dogs, particularly assessing and comparing features found in brachycephalic versus non-brachycephalic dogs. Secondary aims were to describe differences in signalment or presenting complaints as well as potentially specific fluoroscopic features of presumed ED in brachycephalic dogs, to compare these with previous studies,^{6,17,18} and to describe any concurrent diseases and clinical outcomes.

2 | MATERIALS AND METHODS

2.1 | Patient data acquisition

The digital image database of the Hospital for Small Animals at the University of Edinburgh was searched retrospectively for all VFSS performed in dogs between January 2006 (when digital archiving of VFSS started) and May 2017. Patient signalment data were collected including breed, age, and sex. Dogs were classified as brachycephalic or non-brachycephalic based on breed, and furthermore as Bulldog or non-Bulldog breed. Other relevant clinical data (final diagnosis, concurrent diseases or comorbidities, histological diagnosis of an esophageal biopsy specimen if available, treatments administered, and outcomes) also were collated for descriptive purposes.

2.2 | Analysis of VFSS

The VFSS were included if the animal was presented with clinical signs of regurgitation, dysphagia or both, and both the upper and lower esophageal sphincter (LES) were visible during VFSS. Studies were excluded if radiographic signs of generalized megaesophagus were present.

The VFSS all were performed on the same fluoroscopy unit (Apollo EZ, Villa Sistemi Medicali, Buccinasco, Italy). They were reviewed separately by 2 independent examiners: 1 a diagnostic imaging Diplomate (C.E.) and 1 a trained veterinary rotating intern (R.C.). Investigators were blinded to the signalment, presenting signs, and clinical outcome of each case. Objective assessment, based on criteria described in a previous study,⁵ was performed on each VFSS. A presumptive diagnosis of ED was made if the primary peristaltic waves propagated the bolus <5 cm into the proximal esophagus, if contrast material from >2 swallowed boluses accumulated in a portion of the esophagus causing

focal dilatation before the stimulation of additional secondary peristaltic waves or both. The location of any bolus retention was recorded. A presumptive diagnosis of ED also was made if retrograde esophageal contractions were identified, if ETT was prolonged, if GER occurred more than once per swallowed bolus, if HH occurred or some combination of these. A retrograde esophageal contraction was defined as a bolus transported orally for ≥ 10 cm. Esophageal transit time was considered prolonged if a bolus took > 5 seconds to reach the LES from the initiation of the primary wave. Deviation of the esophagus was recorded when visible. Lastly, HH was defined as cranial displacement of the LES beyond the diaphragmatic silhouette and into the thoracic cavity. All assessments and measurements were performed on a dedicated reporting station with calibrated liquid crystal display monitors (Mac Pro, Apple Inc, Cupertino, California) using Digital Imaging and Communications viewer software (OsiriX v5.8.5 64-bit, Geneva, Switzerland).

Studies first were viewed at a frame rate matched to "real time" and then were adjusted in terms of pauses and frame rate and repeated as deemed necessary by the reviewer. Independent of how many boluses were observed, 1 abnormal feature resulted in classification of that parameter as abnormal. Where disagreement occurred between examiners, studies were reviewed together and discussed to reach consensus.

2.3 | Statistical analysis

Data distribution was tested for normality using histograms. Comparison of data between brachycephalic and mesaticephalic dysphagic dogs was performed using *t* tests or Mann-Whitney *U* tests, according to normality assessment. Associations between patient signalment variables and the diagnosis of presumed ED were investigated using Fisher's exact tests. This statistical test also was utilized to evaluate associations between each defined fluoroscopic criterion and brachycephaly. Analyses were performed using a commercially available statistics software package (Minitab 18 Statistical software). A *P*-value of $< .05$ was considered significant.

3 | RESULTS

Thirty-six dogs met the inclusion criteria, including 8 neutered males, 14 intact males, 7 neutered females, and 7 intact females. Breeds included French Bulldog ($n = 11$), Boston Terrier ($n = 3$), English Bulldog ($n = 2$), Border Terrier ($n = 3$), Cocker Spaniel ($n = 3$), Staffordshire Bull Terrier ($n = 2$), Pug ($n = 2$), English Bull Terrier ($n = 2$), mixed breeds ($n = 2$), and $n = 1$ of each of the following breeds: Chihuahua, Cavalier King Charles Spaniel, Maltese, Labrador, Jack Russell Terrier, and Irish Wolfhound. In total, 22/36 (61%) of these dogs were classified as brachycephalic breeds, with 13 of these (36% overall) being bulldog breeds.

All brachycephalic dogs included in the study had clinical signs of regurgitation which had been ongoing for at least 2 weeks. The non-brachycephalic dogs had clinical signs of regurgitation and dysphagia of variable duration, both $>$ and $<$ 2 weeks, and these data were not

consistently available for all dogs. Concurrent clinical signs, apart from regurgitation and dysphagia, were present in 26/36 (72%) dogs and included coughing, retching, vomiting, collapse, exercise intolerance, hypersalivation, nasal discharge, and lip smacking. No dog had been presented primarily for respiratory signs, but 17 concurrently were diagnosed with BOAS based on physical examination findings.

All dogs had been fasted for at least 6 hours (most for ≥ 12 hours) for the VFSS procedure. All dogs were conscious, and imaging was performed with the dogs in a standing position with minimal restraint. In all cases, undiluted liquid barium sulfate was administered by syringe first, followed by barium mixed with wet food, followed by barium mixed with kibble (the latter 2 eaten freely from a bowl). Bolus size and the number of deglutition events were not standardized, but all studies included at least 4 swallowed boluses. Manual abdominal pressure was applied only when a HH was not seen. This maneuver was performed once the stomach was relatively full.

Ten VFSS were classified as normal (27%), whereas 26 (73%) displayed features of presumed ED. Overall, the most commonly observed feature consisted of prolonged ETT ($n = 21/26$; 80%), followed by ineffective secondary peristaltic waves ($n = 20/26$; 77%) and GER occurring more than once per swallowed bolus (18/26; 69%; Figure 1). Subjectively, GER in brachycephalic dogs often seemed to occur during entry of the bolus into the stomach, rather than after entering the stomach. It occurred spontaneously in both groups. Other findings included a < 5 cm propagation distance of the primary peristaltic wave ($n = 6/26$; 23%), bolus retention within the cervical region ($n = 4/26$; 15%), bolus retention within the thoracic inlet ($n = 9/25$; 35%) or mid-thoracic cavity ($n = 7/26$; 27%), retrograde esophageal contractions ($n = 7/26$; 27%), and sliding HH of the abdominal esophagus and stomach ($n = 8/26$; 31%; Figure 2). Because of the retrospective nature of this study, it unfortunately was not possible to determine which dogs had HH only after abdominal pressure was applied. However, our subjective observation was that applying pressure usually did not result in the visualization of a hernia.

Twenty dogs with presumed ED were brachycephalic (77%), 12 of which (60%) were bulldog breeds, and 6 dogs (23%) were non-brachycephalic breeds. In brachycephalic dysphagic dogs, the most common VFSS findings were ineffective secondary peristaltic waves (15/20), prolonged ETT (15/20), and GER occurring more than once per swallowed bolus (15/20).

All 8 dogs in which HH was observed were brachycephalic. These included 4 French Bulldogs, 2 Boston Terriers, 1 Chihuahua, and 1 Staffordshire Bull Terrier (Figure 2). Three dogs had a "U-shaped" deviation of the esophagus at the level of the thoracic inlet consistent with redundant esophagus (1 English Bulldog, 1 French Bulldog, and 1 Pug). Two of these dogs had ED and 1 was classified as normal. In addition, 12 dogs had deviation of the esophagus at the level of the carina; all of these were brachycephalic, and 2 of them had normal esophageal motility. This deviation was in the form of a prominent dorsally directed arc.

Based on Fisher's exact test, brachycephalic dogs were significantly more likely to have features of presumed ED compared to non-brachycephalic dogs in this cohort ($P = .005$). Despite

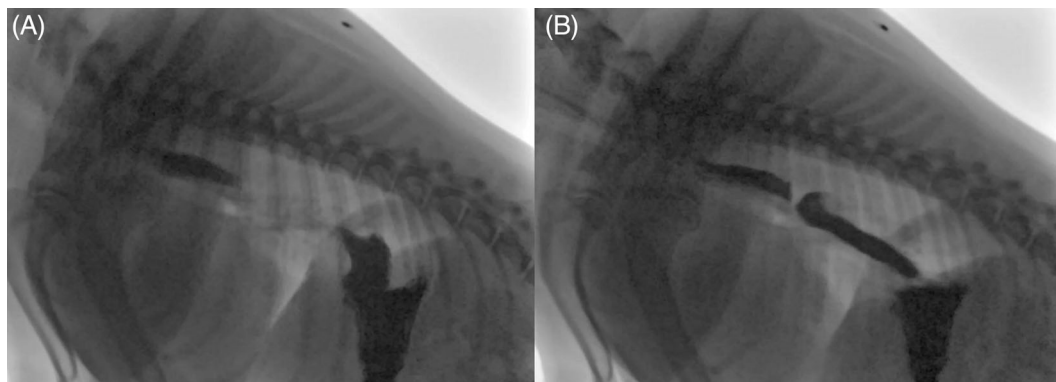


FIGURE 1 Sequential fluoroscopic still images of gastroesophageal reflux (GER). A, A slurried barium bolus has just entered the stomach. A second slurried barium bolus is present within the mid-thoracic esophagus. B, Subsequently, gastric content is refluxed into the distal esophagus

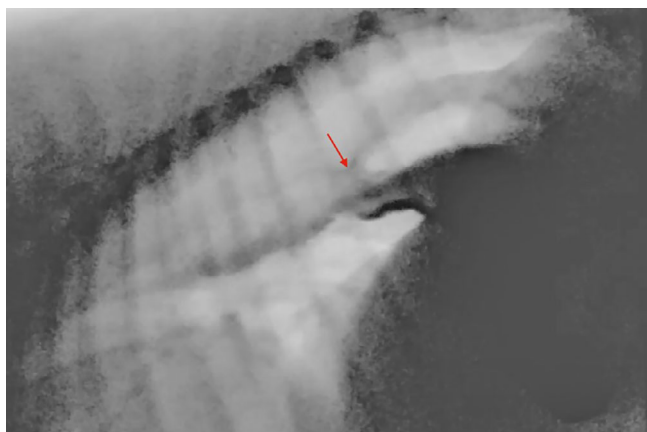


FIGURE 2 Fluoroscopic still image of a hiatal hernia. The red arrow denotes the gastroesophageal junction (GEJ), which is cranially displaced into the thoracic cavity

overrepresentation, the bulldog breed was not significantly associated with these features ($P = .06$). The median age of brachycephalic dysphagic dogs was 1.2 years (range, 0.2-10.5 years), whereas the median age of non-brachycephalic dysphagic dogs was 1.1 years (range, 0.2-7.5 years), which was not significantly different ($P = 1.0$), and hence age (<3 years) was not associated with presumed ED ($P = .23$). No effect of sex on the likelihood of suffering from presumed ED was identified ($P = .71$).

Significant associations were identified between brachycephaly and prolonged ETT ($P = .04$), GER ($P = .02$), and HH ($P = .01$). Primary wave features, ineffective secondary waves, and retrograde esophageal contractions were found to be independent of breed group ($P = .37$, $.09$, and $.68$, respectively).

Fifteen dogs underwent an endoscopic procedure, with biopsy specimens taken of the esophagus ($n = 4$), stomach ($n = 14$), and duodenum ($n = 14$). Esophageal mucosal pathology was identified in 3 of 4 dogs including changes compatible with Barrett's esophagus ($n = 1$) in a Boston terrier and chronic active ulcerative esophagitis with submucosal hemorrhage ($n = 1$) in an English Bulldog, both of which displayed features of presumed ED. Esophageal mucosal hyperplasia was identified in a Border Terrier ($n = 1$) without features of presumed

ED. Eight dogs had gastritis (lymphofollicular, eosinophilic, or chronic atrophic) and duodenitis (lymphoplasmacytic or eosinophilic), all of which were brachycephalic breeds with presumed ED. Three dogs had gastritis only, all of which were non-brachycephalic, 1 of which had features of presumed ED, and 2 of which were normal. Three dogs had duodenitis only, all of which were brachycephalic, 2 of which had features of presumed ED, and 1 of which was normal.

The underlying causes of presumed ED in the mesaticephalic dogs included gastritis ($n = 4$), gastric ulceration ($n = 1$), and severe esophagitis caused by reflux under general anesthesia ($n = 1$). Other final diagnoses included presumed inflammatory bowel disease ($n = 6$), pharyngeal dysphagia ($n = 3$), bronchitis ($n = 1$), and aspiration pneumonia ($n = 1$). Presumed ED in all brachycephalic dogs ($n = 20$) was thought to be a result of breed-related changes (ie, BOAS), gastritis, or was idiopathic. Concurrent conditions in dogs with BOAS included a redundant pyloric mucosal fold identified on ultrasound examination or endoscopy ($n = 3$), gastritis ($n = 8$), primary esophagitis from GER caused by previous general anesthetic ($n = 1$), LES insufficiency ($n = 1$), and persistent right aortic arch with an esophageal diverticulum as a cause for dysphagia ($n = 1$).

Of the non-brachycephalic dogs with presumed ED, 2 were managed medically for gastritis and responded well, 1 was treated medically for a gastric ulcer and responded well, 1 died from complications arising from aspiration of refluxed material, and 2 were lost to follow-up. Of the brachycephalic dogs with ED, 15 were managed medically with some combination of a hypoallergenic diet, omeprazole, sucralfate, cisapride, and feeding from an elevated position. Of these patients, 7 dogs improved clinically in terms of the frequency of regurgitation according to the owner, 4 failed to improve, and 4 were lost to follow-up. Eight dogs underwent surgery for BOAS as well as medical management. Of these patients, 7 dogs improved clinically by 4 weeks after surgery, whereas 1 dog died shortly postoperatively. One dog underwent surgery for persistent right aortic arch and 1 dog had a gastropexy performed, with both reported to be clinically improved at the last reevaluation.

4 | DISCUSSION

Brachycephalic dogs, particularly bulldogs, with a final diagnosis of presumed idiopathic ED were overrepresented in this clinical

population of dogs presented for dysphagia, regurgitation, or both. The most common imaging features of presumed ED were prolonged ETT, prolonged secondary peristaltic waves, and GER occurring more than once per swallowed bolus. The latter 2 were significantly associated with brachycephaly. We also identified a relatively high prevalence of HH in brachycephalic dogs with presumed dysmotility, which has been documented previously.⁶ In addition, 17/20 (85%) brachycephalic dogs diagnosed with presumed ED were affected concurrently by BOAS.

Prolonged ETT previously has been reported as a common feature of ED in dogs with BOAS, where 31 of 36 dogs presented primarily for the treatment of BOAS had delayed ETT.⁶ Our study provides evidence that this imaging feature also is common in a population of dogs presented primarily for dysphagia, regurgitation, or both. Studies were performed with the dogs in a standing position with a horizontal X-ray beam because of the proven effects of recumbent positioning on ETT.¹⁶ Delayed maturation of the esophagus has been suggested as an underlying cause of delayed transit time in young terrier dogs, because the esophagus of dogs can continue to mature up to 1 year of age.^{5,19} Eleven dogs affected by presumed ED in our study however were >1 year of age, therefore esophageal maturation would not account for delayed transit in these older dogs. In addition, a recent study found no significant difference in swallowing metrics with respect to age.²⁰ Esophagitis is more likely as the cause of both ineffective secondary peristalsis and delayed transit in these patients considering the high frequency of GER. Deglutitive inhibition has been described in humans and animal models, whereby esophageal motility is inhibited during active swallowing.²¹ The same physiological effects may occur in dogs, therefore future studies could consider assessing primary peristaltic waves and measuring ETT when the dog is not actively swallowing for more accurate evaluation of this parameter. Recent studies in human patients have identified a significantly lower secondary peristaltic response rate in patients with GER disease (GERD) and it seems likely that this effect also occurs in dogs. Inherently, ineffective secondary peristalsis also would contribute to prolonged ETT.²²

Gastroesophageal reflux has been reported previously and diagnosed by endoscopy in 18/61 dogs presented for BOAS²³ and by fluoroscopy in 27/36 dogs presented for BOAS.⁶ Our findings are very similar to those of the previous fluoroscopic study, suggesting that VFSS has a higher sensitivity for the detection of this abnormality than does endoscopy. This improved detection rate is clinically important because early recognition of reflux allows management to minimize mucosal damage to the esophagus and allows for preventative measures to be taken against potential postoperative aspiration, a risk that is already increased in dogs undergoing surgery of the upper airway.²⁴ Infrequent GER involving small volumes that are rapidly returned to the stomach has been reported as a normal feature of swallowing in the dog.^{20,25} Pathologic GERD in the dog has yet to be objectively classified, making its diagnosis on the basis of a fluoroscopic study challenging. We deemed GER abnormal when it occurred more than once per bolus because this feature has not been described in normal dogs. In humans, GER is considered clinically relevant if the refluxed ingesta are not returned to the stomach within 2 seconds.

The horizontal orientation of the esophagus in dogs, the substantial size discrepancies, and variability compared to humans make this reference parameter of unknown suitability. Further studies in dogs perhaps could investigate this parameter. In humans, chronic reflux causes changes in the esophageal squamous epithelium termed hyperregenerative esophagopathy (HRE) which is considered pathognomonic for GERD.²⁶ It has been reported that 70% of human patients with GERD had no endoscopically visible lesions.²⁷ The same histopathological changes have been found to occur in dogs and, similarly, the majority of dogs with confirmed HRE and clinical signs of GERD had minimal or no mucosal changes visible on esophagoscopy.²⁸ In our study, only 4 dogs had endoscopic esophageal mucosal biopsies performed because of gross abnormalities of the mucosa, and the difficulty in obtaining meaningful esophageal biopsy specimens in this species. Three of these dogs had histopathological features of inflammation or esophageal metaplasia, similar to Barrett's esophagus, which typically is secondary to chronic reflux.²⁹ Esophageal biopsy specimens were not taken in dogs with a grossly normal esophagus in part because of the difficulties associated with the biopsy procedure, and it is possible that more dogs in our study may have been affected by HRE.

In humans, obesity is well established as being correlated with GERD symptoms.³⁰ Brachycephalic dogs have a smaller airway size relative to their body weight compared to non-brachycephalic dogs, creating a similar situation to that of overweight people. A recent study assessing GERD in anesthetized dogs with BOAS found that dogs with GERD had significantly higher body weight compared to those without GERD, but body condition score was not associated with GERD.³¹ Further study is warranted to investigate the role of body weight relative to airway dimensions in the etiology of GER in brachycephalic dogs.

Hiatal herniation was recognized in 36% of French Bulldogs in our study population. It also was observed in a Boston Terrier, Chihuahua, and Staffordshire Bull Terrier, breeds in which this condition has not previously been reported. In brachycephalic dogs, HH may occur secondary to abnormally decreased intrathoracic pressure as a result of increased respiratory effort.^{17,32-35} The increased transdiaphragmatic pressure gradient induces an axial separation of the LES from the hiatus, thereby weakening the gastroesophageal junction (GEJ) barrier pressure and allowing HH and possibly GERD to develop.^{18,36} Once the GEJ has been pulled into the thoracic cavity, the pressure barrier is weakened, allowing GER and subsequent esophagitis. This may further decrease LES pressure, resulting in a self-perpetuating cycle. Aerophagia and delayed gastric emptying also could increase intra-abdominal pressure, which may induce cranial displacement of the GEJ and hence HH.¹¹ Gastroesophageal reflux disease in the absence of sliding HH also may occur by a similar mechanism. Our study identified HH in 40% of the brachycephalic dogs with BOAS. A previous study reported HH in 76% of brachycephalic dogs with BOAS.⁶ Potential reasons for this discrepancy include relatively small sample sizes, differences in referral populations, technical factors, and length of image capture. Studies that used endoscopy to diagnose HH in dogs with BOAS identified a prevalence of only 5%-6%.^{11,23} Endoscopy may fail to diagnose some cases of GER because of the effects

of anesthesia.³⁷ Therefore, it is likely that these endoscopic studies have underestimated the prevalence of this condition in brachycephalic breeds. Fluoroscopy is a more sensitive technique that is more physiologically representative and does not require anesthesia.

Manual application of abdominal pressure to aid in the recognition of an HH is used in humans and has been reported in the veterinary literature.^{6,38} In our study, many dogs would hold their breath and tense their abdominal wall when pressure was applied, rendering this technique unhelpful, similar to what was observed in a previous study.⁶

Association and correlation between BOAS and GI disease have been identified previously.^{18,23} This correlation could explain the reported improvement of GI signs after surgical correction of BOAS.²³ Seven of 8 dogs (88%) in our study showed clinical improvement in the frequency and severity of dysphagia, regurgitation or both after upper respiratory tract surgery with concurrent medical management, and 7/15 dogs (47%) treated by medical management alone clinically improved. Similarly, a previous study found improvement in GI signs after upper respiratory tract surgery and medical management of GI signs in 91.4% of cases.²³ These results support the role of increased transdiaphragmatic pressure in the etiology of pathological reflux and HH. Surgical management of HH and GER in dogs using hiatal plication, esophagopexy, and gastropexy has been described, with variable outcomes and persistent GER and sliding HH postoperatively in some patients.³⁹ Airway surgery therefore could be more effective in resolving these conditions because it targets the cause rather than the clinical signs. Further exploration is warranted in a larger population of dogs with BOAS monitored postoperatively.

A major limiting factor for our study was the lack of robust quantitative and qualitative esophageal swallowing parameters in brachycephalic dogs to which our study population could be compared. Some standardized swallowing metrics, including ETT, retrograde flow, and GER have recently been described, but all brachycephalic breeds were excluded from that study.²⁰ Without a clear basis for what denotes normal swallowing function in brachycephalic dogs, it is impossible at this time to accurately and quantitatively define ED. A large-scale study of brachycephalic dogs without clinical signs, ideally coupled with esophageal manometry, would be required to define normal esophageal function in these breeds. Exposing personnel to radiation for the sake of obtaining swallow studies from clinically healthy dogs, however, is not warranted ethically. The criteria described in our study were adopted from the limited available literature.^{5,20,25} Despite this hindrance to interpretation, we believe it is important to report the current findings in order to share information with the veterinary community regarding a thus far poorly described disorder.

All VFSSs were reviewed by 2 observers, adhering to recently published protocols to increase objective interpretation but there remains a substantial amount of subjectivity in assessment. There was some difficulty in interpretation of herniation and reflux versus reflux alone in some dogs because of image quality and patient movement. Importantly, HH and GER occur intermittently, and may not occur during the acquisition of a VFSS. For this reason, it is possible that

some dogs classified as normal in our study may in fact be affected by HH, GER, or both but our study did not capture these processes occurring. The methodology used in our study was non-standardized in terms of contrast liquidity, bolus size, total number of boluses followed, duration of the study, and manual application of abdominal pressure. Magnification also was not taken into account, which inevitably would produce some measurement error. We suggest a more standardized approach for future studies.

5 | CONCLUSION

Our study confirmed the clinical suspicion of a high prevalence of presumed ED in young brachycephalic dogs presented for dysphagia, regurgitation, or both. Typical findings included prolonged ETT, ineffective secondary peristaltic waves, and GER occurring more than once per swallowed bolus. Although further prospective and more standardized studies are needed, clinicians should be alert to this high prevalence and its association with BOAS. Videofluoroscopic barium swallow studies remain the gold standard for detection of ED. Surgical management of BOAS may be an effective treatment for ED in brachycephalic dogs, and further research on clinical outcomes post-surgery will provide information on the prognosis of this condition.

ACKNOWLEDGMENTS

The authors thank Rona Rae and Lynn Grant from the Royal (Dick) School of Veterinary Studies for their contribution in the acquisition of the fluoroscopic studies. The authors also thank Darren J. Shaw from the Royal (Dick) School of Veterinary Studies for his support in the statistical analyses involved in this project. This paper was presented in parts at the Annual Scientific Meeting of the American College of Veterinary Radiology, October 18-21, 2017, in Phoenix, Arizona.

CONFLICT OF INTEREST DECLARATION

Authors declare no conflict of interest.

OFF-LABEL ANTIMICROBIAL DECLARATION

Authors declare no off-label use of antimicrobials.


INSTITUTIONAL ANIMAL CARE AND USE COMMITTEE (IACUC) OR OTHER APPROVAL DECLARATION

There is institutional Veterinary Ethics Review Committee (VERC) approval for the retrospective analysis of these data from the hospital's patient management system (VERC no #9.17).

HUMAN ETHICS APPROVAL DECLARATION

Authors declare human ethics approval was not needed for this study.

ORCID

Caroline Eivers  <https://orcid.org/0000-0002-8095-2671>Silke Salavati Schmitz  <https://orcid.org/0000-0003-1084-7013>

REFERENCES

- Pollard RE, Marks SL, Cheney DM, Bonadio CM. Diagnostic outcome of contrast videofluoroscopic swallowing studies in 216 dysphagic dogs. *Vet Radiol Ultrasound*. 2017;58(4):373-380.
- Gaskell CJ, Gibbs C, Pearson H. Sliding hiatus hernia with reflux oesophagitis in two dogs. *J Small Anim Pract*. 1974;15(8):503-509.
- Callan MB, Washabau RJ, Saunders HM, Kerr L, Prymak C, Holt D. Congenital esophageal hiatal hernia in the Chinese shar-pei dog. *J Vet Intern Med*. 1993;7(4):210-215.
- Han E. Diagnosis and management of reflux esophagitis. *Clin Tech Small Anim Pract*. 2003;18(4):231-238.
- Bexfield NH, Watson PJ, Herrtage ME. Esophageal dysmotility in young dogs. *J Vet Intern Med*. 2006;20(6):1314-1318.
- Reeve EJ, Sutton D, Friend EJ, Warren-Smith CMR. Documenting the prevalence of hiatal hernia and oesophageal abnormalities in brachycephalic dogs using fluoroscopy. *J Small Anim Pract*. 2017;58(12):703-708.
- Stanley BJ, Hauptman JG, Fritz MC, Rosenstein DS, Kinns J. Esophageal dysfunction in dogs with idiopathic laryngeal paralysis: a controlled cohort study. *Vet Surg*. 2010;39(2):139-149.
- Peeters ME, Ubbink GJ. Dysphagia-associated muscular dystrophy: a familial trait in the bouvier des Flandres. *Vet Rec*. 1994;134(17):444-446.
- Stickle R, Sparschu G, Love N, Walshaw R. Radiographic evaluation of esophageal function in Chinese Shar Pei pups. *J Am Vet Med Assoc*. 1992;201(1):81-84.
- Pollard RE. Imaging evaluation of dogs and cats with dysphagia. *ISRN Vet Sci*. 2012;2012:1-15.
- Poncet CM, Dupre GP, Freiche VG, Estrada MM, Poubanne YA, Bouvy BM. Prevalence of gastrointestinal tract lesions in 73 brachycephalic dogs with upper respiratory syndrome. *J Small Anim Pract*. 2005;46(6):273-279.
- Cornell K. Stomach. In: Tobias K, Johnston S, eds. *Veterinary Surgery Small Animals*. 1st ed. St. Louis, MO: Elsevier Ltd; 2012:1500-1512.
- Keeley B, Puggioni A, Pratschke K. Congenital oesophageal hiatal hernia in a pug. *Ir Vet J*. 2008;61(6):389-393.
- Guiot LP, Lansdowne JL, Rouppert P, Stanley BJ. Hiatal hernia in the dog: a clinical report of four Chinese Shar Peis. *J Am Anim Hosp Assoc*. 2008;44(6):335-341.
- Martin-Harris B, Jones B. The videofluorographic swallowing study. *Phys Med Rehabil Clin N Am*. 2008;19(4):769-785.
- Bonadio CM, Pollard RE, Dayton PA, Leonard CD, Marks SL. Effects of body positioning on swallowing and esophageal transit in healthy dogs. *J Vet Intern Med*. 2009;23(4):801-805.
- Lecoindre P, Richard S. Digestive disorders associated with the chronic obstructive respiratory syndrome of brachycephalic dogs: 30 cases (1999-2001). *Revue Vet Med*. 2004;155:144-146.
- Broux O, Clercx C, Etienne A-L, et al. Effects of manipulations to detect sliding hiatal hernia in dogs with brachycephalic airway obstructive syndrome. *Vet Surg*. 2018;47(2):243-251.
- Diamant N, Szczepanski M, Mui H. Idiopathic megaesophagus in the dog: reasons for spontaneous improvement and a possible method of medical therapy. *Can Vet J*. 1974;15(3):66-71.
- Harris RA, Grobman ME, Allen MJ, et al. Standardization of a videofluoroscopic swallow study protocol to investigate dysphagia in dogs. *J Vet Intern Med*. 2017;31(2):383-393.
- Sifrim D, Jafari J. Deglutitive inhibition, latency between swallow and esophageal contractions and primary esophageal motor disorders. *J Neurogastroenterol Motil*. 2012;18(1):6-12.
- Schoeman MN, Holloway RH. Integrity and characteristics of secondary oesophageal peristalsis in patients with gastro-oesophageal reflux disease. *Gut*. 1995;36:499-504.
- Poncet CM, Dupre GP, Freiche VG, Bouvy BM. Long-term results of upper respiratory syndrome surgery and gastrointestinal tract medical treatment in 51 brachycephalic dogs. *J Small Anim Pract*. 2006;47(3):137-142.
- Ovbey DH, Wilson DV, Bednarski RM, et al. Prevalence and risk factors for canine post-anesthetic aspiration pneumonia (1999-2009): a multicenter study. *Vet Anaesth Analg*. 2014;41(2):127-136.
- Watrous B, Suter P. Normal swallowing in the dog: a cineradiographic study. *Vet Radiol Ultrasound*. 1979;20:99-109.
- Ismail-Beigi F, Horton PF, Pope CE. Histological consequences of gastroesophageal reflux in man. *Gastroenterology*. 1970;58(2):163-174.
- Tytgat GNJ. Recent developments in gastroesophageal reflux disease and Barrett's esophagus: ANNO 2012. *J Dig Dis*. 2012;13(6):291-295.
- Münster M, Hörauf A, Lübke-Becker A, Grest P, Rütten M. Idiopathic esophagopathies resembling gastroesophageal reflux disease in dogs. *Tierarzt Prax Ausg K Kleintiere Heimtiere*. 2013;41(3):173-179.
- Gibson CJ, Parry NMA, Jakowski RM, Cooper J. Adenomatous polyp with intestinal metaplasia of the esophagus (Barrett esophagus) in a dog. *Vet Pathol*. 2010;47(1):116-119.
- Eusebi LH, Fuccio L, Bazzoli F. The role of obesity in gastroesophageal reflux disease and Barrett's esophagus. *Dig Dis*. 2012;30(2):154-157.
- Shaver SL, Barbur LA, Jimenez DA, et al. Evaluation of gastroesophageal reflux in anesthetized dogs with brachycephalic syndrome. *J Am Anim Hosp Assoc*. 2017;53(1):24-31.
- Bright R. Hiatal hernia. In: Monnet E, ed. *Small Animal Soft Tissue Surgery*. 1st ed. Ames, IA: Wiley-Blackwell; 2013:321-327.
- Pratschke KM, Bellenger CR, McAllister H, Campion D. Barrier pressure at the gastroesophageal junction in anesthetized dogs. *Am J Vet Res*. 2001;62(7):1068-1072.
- Sivacolundhu RK, Read RA, Marchevsky AM. Hiatal hernia controversies—a review of pathophysiology and treatment options. *Aust Vet J*. 2002;80(1-2):48-53.
- Hardie EM, Ramirez O, Clary EM, et al. Abnormalities of the thoracic bellows: stress fractures of the ribs and hiatal hernia. *J Vet Intern Med*. 1998;12(4):279-287.
- Kahrilas PJ, Lin S, Chen J, Manka M. The effect of hiatus hernia on gastro-oesophageal junction pressure. *Gut*. 1999;44(4):476-482.
- Vangrinsven E, Broux O, Claeys S, Billen F. Abstract ECVIM: endoscopic investigation of the gastroesophageal junction dynamics in dogs with brachycephalic syndrome. *J Vet Intern Med*. 2015;30:379.
- Suter P, Lord P. Abnormalities of the diaphragm. In: Suter P, ed. *Thoracic Radiography: A Text Atlas of Thoracic Diseases of the Dog and Cat*. Switzerland: Wettswil; 1984:199-200.
- Mayhew PD, Marks SL, Pollard R, Culp WTN, Kass PH. Prospective evaluation of surgical management of sliding hiatal hernia and gastroesophageal reflux in dogs. *Vet Surg*. 2017;46(8):1098-1109.

How to cite this article: Eivers C, Chicon Rueda R, Liuti T, Salavati Schmitz S. Retrospective analysis of esophageal imaging features in brachycephalic versus non-brachycephalic dogs based on videofluoroscopic swallowing studies. *J Vet Intern Med*. 2019;1-7. <https://doi.org/10.1111/jvim.15547>