



THE UNIVERSITY *of* EDINBURGH

Edinburgh Research Explorer

Comparative analysis of c-kit gene expression and c-Kit immunoreactivity in horses with and without obstructive intestinal disease

Citation for published version:

Fintl, C, Pearson, GT, Mayhew, IG, Lowden, CS, Hopwood, PA, Palgrave, CJ, Proudman, CJ, Edwards, GB, Taylor, S & Hudson, NPH 2010, 'Comparative analysis of c-kit gene expression and c-Kit immunoreactivity in horses with and without obstructive intestinal disease', *Veterinary Journal*, vol. 186, no. 1, pp. 64-69. <https://doi.org/10.1016/j.tvjl.2009.07.015>

Digital Object Identifier (DOI):

[10.1016/j.tvjl.2009.07.015](https://doi.org/10.1016/j.tvjl.2009.07.015)

Link:

[Link to publication record in Edinburgh Research Explorer](#)

Document Version:

Early version, also known as pre-print

Published In:

Veterinary Journal

General rights

Copyright for the publications made accessible via the Edinburgh Research Explorer is retained by the author(s) and / or other copyright owners and it is a condition of accessing these publications that users recognise and abide by the legal requirements associated with these rights.

Take down policy

The University of Edinburgh has made every reasonable effort to ensure that Edinburgh Research Explorer content complies with UK legislation. If you believe that the public display of this file breaches copyright please contact openaccess@ed.ac.uk providing details, and we will remove access to the work immediately and investigate your claim.





Contents lists available at ScienceDirect

The Veterinary Journal

journal homepage: www.elsevier.com/locate/tvjl

Comparative analysis of *c-kit* gene expression and c-Kit immunoreactivity in horses with and without obstructive intestinal disease

Constanze Fintl^{a,*}, Geoff T. Pearson^b, Ian G. Mayhew^c, C. Stewart Lowden^d, Paul A. Hopwood^e, Christopher J. Palgrave^f, Christopher J. Proudman^g, G. Barrie Edwards^g, Sarah E. Taylor^h, Neil P.H. Hudson^b

^a Norwegian School of Veterinary Science, Department of Companion Animal Clinical Sciences, PO Box 8146 Dep., 0033 Oslo, Norway

^b Gastrointestinal Motility and Disease Laboratory, Royal (Dick) School of Veterinary Studies, University of Edinburgh, Summerhall, Edinburgh EH9 1QH, UK

^c Massey University Veterinary Teaching Hospital, Tennent Drive, Massey University, Private Bag 11-222, North Palmerston, New Zealand

^d Veterinary Health Research Pty. Ltd, Trevenna Rd. (Private Bag), West Armidale NSW 2350, Australia

^e Medical Microbiology, University of Edinburgh Medical School, Teviot Place, Edinburgh EH8 9AG, UK

^f Department of Population Health and Pathobiology, College of Veterinary Medicine, North Carolina State University, 4700 Hillsborough Street, Raleigh, NC 27606, USA

^g Equine Division, University of Liverpool, Leahurst, Neston, South Wirral CH64 7TE, UK

^h Division of Veterinary Clinical Sciences, University of Edinburgh, Easter Bush Veterinary Centre, Easter Bush, Roslin, Midlothian EH25 9RG, UK

ARTICLE INFO

Article history:

Accepted 6 July 2009

Keywords:

Interstitial cells of Cajal
c-Kit
Horse
Immunohistochemistry
PCR

ABSTRACT

Previous immunohistochemical studies targeting the receptor tyrosine kinase (c-Kit) have demonstrated an apparent reduction in the number of gastrointestinal pacemaker cells – the interstitial cells of Cajal (ICC) – in horses with intestinal motility disorders. This study compared the level of transcription of the *c-kit* gene encoding this receptor in horses with and without such motility disorders. Transcription levels of this gene were also compared to the density of ICC immunohistochemically positive for the c-Kit antigen. Intestinal samples were collected from 18 horses with intestinal disease and from 15 control animals. Following gene extraction and identification, real-time quantitative analysis of *c-kit* and a control gene, *ACTB* (β -actin), was carried out on all samples and the density of the c-Kit-positive ICC compared.

There was a significant reduction in c-Kit immunoreactivity in the ICC of horses with large intestinal obstructive disorders relative to controls but no significant difference in the transcription of the *c-kit* gene between normal and affected animals. Further studies will be required to elucidate the mechanisms regulating c-Kit expression and to assess the pathophysiological significance of these findings.

© 2009 Elsevier Ltd. All rights reserved.

Introduction

Equine gastrointestinal motility disorders constitute a significant problem in veterinary medicine in terms of morbidity and mortality as well as having a considerable economic impact on the horse industry (Traub-Dargatz et al., 2001). The gastrointestinal pacemaker cells, the interstitial cells of Cajal (ICC), are integral to the coordination of normal intestinal motility by initiating slow-wave activity (Ward et al., 1994; Torihashi et al., 1995). The ICC are also thought to mediate neurotransmission as well as facilitating the propagation of electrical events (Ward et al., 2004).

Equine ICC can be identified by the immunohistochemical labelling of a receptor tyrosine kinase, c-Kit, encoded by the proto-onco-

gene *c-kit* (Maeda et al., 1992; Hudson et al., 1999). This receptor is not only a convenient cell marker but is also essential for the development and function of the ICC phenotype through binding its natural ligand stem cell factor (SCF) (Ward et al., 1994; Torihashi et al., 1999; Ward et al., 1999). Alterations to ICC networks and numbers have been demonstrated in intestinal motility disorders in man and horses (Vanderwinden and Rumessen, 1999; Hudson et al., 2001; Fintl et al., 2004). Hudson et al. (2001) demonstrated a reduction in c-Kit-immunoreactive ICC in horses with grass sickness (equine dysautonomia) and proposed that this change contributed to the dysfunctional motility. Similar conclusions were drawn by Fintl et al. (2004) who demonstrated a reduction in the density of ICC in horses with an obstructive disorder of the large colon.

As part of further study of the role of ICC in equine intestinal motility disorders, *c-kit* transcription levels were compared between affected and normal animals. These findings were in turn compared to the degree of c-Kit expression as evidenced by immunohistochemical labelling of samples from the same horses.

* Corresponding author. Tel.: +47 22964920; fax: +47 22964761.
E-mail address: constanze.fintl@veths.no (C. Fintl).

Materials and methods

Animal selection

Full thickness intestinal samples from 15 control horses (median age 12.5 years, mean age 12.0 years, range 1–33 years) (Table 1) were collected immediately following euthanasia by intravenous administration of quinalbarbitone/cinchocaine (Somulose, Dechra). A segment of ileum (at a position level with the midpoint of the ileocaecal fold) was collected from eight animals (median age 11.5 years, mean age 15.6 years, range 1–33 years) and a pelvic flexure sample (located at the junction between the left ventral and left dorsal colon) was collected from seven horses (median and mean age 11 years, range 3–19 years). All animals were euthanased because of disease not involving the gastrointestinal tract and none of these horses had a known history of intestinal motility dysfunction.

Full thickness intestinal samples were also collected during surgery from 18 horses (median age 11.5 years, mean age 9.9 years, range 2–24 years) undergoing exploratory laparotomy to investigate and treat conditions associated with abdominal pain (colic). All animals had been anaesthetised using a standard protocol using an alpha-2 agonist (Sedivet, Boehringer Ingelheim), ketamine (Vetalar, Fort Dodge) and diazepam (Diazepam Injection, Hameln Pharmaceuticals) as induction agents, and were then maintained with halothane (Halothane Vet, Merial Animal Health) by inhalation.

Of these animals, eight (median age 13.0 years, mean age 14.0 years, range 8–24 years) had various obstructive lesions of the small intestine (SI) (Table 1). Samples collected from this group included jejunum or ileum from non-ischaemic, non-distended segments, to the obstructive lesion at the margin of affected, and therefore resected SI. Although samples were selected to match those of the controls as far as possible, this was sometimes not possible where the lesion involved jejunum only ($n = 5$). In the remaining 10 animals (median age 6.0 years, mean age 6.7 years, range 2–14 years), an obstructive disorder of the large intestine (LI) was diagnosed (Table 1). From these animals, a segment of pelvic flexure was sampled. This sample comprised surplus tissue following pelvic flexure biopsy for histopathological examination. All samples were collected with the owners' written consent.

Table 1
Details of cases included in the study.

Horse group	Age (years)	Sex	Sample	Reason for euthanasia/diagnosis
<i>Small intestine – normal group</i>				
Horse 1	31	M	IL	Chronic orthopaedic disorder
Horse 2	11	M	IL	Chronic orthopaedic disorder
Horse 3	1	M	IL	Chronic orthopaedic disorder
Horse 4	33	M	IL	Chronic orthopaedic disorder
Horse 5	8	M	IL	Chronic orthopaedic disorder
Horse 6	12	F	IL	Chronic orthopaedic disorder
Horse 7	11	M	IL	Chronic orthopaedic disorder
Horse 8	18	F	IL	Reproductive tract disorder
<i>Small intestine – colic group</i>				
Horse 1	8	F	IL	Mesenteric rent
Horse 2	12	M	JEJ	Epiploic foramen entrapment
Horse 3	19	M	JEJ	Strangulating lipoma
Horse 4	12	M	IL	Strangulating eosinophilic lesion
Horse 5	14	M	JEJ	Epiploic foramen entrapment
Horse 6	9	M	JEJ	Epiploic foramen entrapment
Horse 7	14	M	JEJ	Meckel's diverticulum
Horse 8	24	F	IL	Strangulating lipoma
<i>Large intestine – normal group</i>				
Horse 1	15	F	PF	Chronic respiratory disorder
Horse 2	19	M	PF	Chronic orthopaedic disorder
Horse 3	11	F	PF	Chronic orthopaedic disorder
Horse 4	3	M	PF	Chronic orthopaedic disorder
Horse 5	18	F	PF	Reproductive tract disorder
Horse 6	2	F	PF	Central neurological disorder
Horse 7	9	F	PF	Chronic orthopaedic disorder
<i>Large intestine – colic group</i>				
Horse 1	9	M	PF	Right large colon displacement
Horse 2	5	M	PF	Left large colon displacement
Horse 3	8	M	PF	Right large colon displacement
Horse 4	6	M	PF	Right large colon displacement
Horse 5	2	F	PF	Large colon torsion
Horse 6	3	F	PF	Left large colon displacement
Horse 7	6	M	PF	Right large colon displacement
Horse 8	9	F	PF	Left large colon displacement
Horse 9	5	F	PF	Left large colon displacement
Horse 10	14	F	PF	Large colon torsion

M, male; F, female; IL, ileum; JEJ, jejunum; PF, pelvic flexure.

Sample processing – RNA extraction and reverse transcription

Full thickness intestinal segments (0.5 cm × 0.5 cm) were immediately placed in an RNA-stabilising solution (RNA Later, Qiagen). RNA extraction was performed using the RNeasy kit (Qiagen) following removal of the mucosa and submucosa. RNA was extracted using phenol/guanidine HCl reagents (TriReagent, Sigma) and isolated (Clements et al., 2006). To each sample, 1 µg RNA and 1 µL of oligoDT primers were added at 65 °C for 5 min. Reverse transcription was performed using the Qiagen Omniscript Reverse Transcriptase kit (Qiagen) according to the manufacturer's instructions.¹ Samples were stored at –20 °C prior to quantification of gene expression.

Primer design

Transcript sequences were obtained from the National Centre for Biotechnology Information, Bethesda, USA. Equine sequences were aligned to human, bovine and canine sequences using online software² to predict equine exon boundaries. Primers were designed using the Primer 3 Output programme³ and were selected to span predicted exon boundaries where possible. BLAST searches were performed for all sequences to confirm gene specificity. Target and reference gene primers were synthesised by Invitrogen (Table 2).

Real-time quantitative PCR

The real-time PCR reaction comprised: LightCycler–FastStart DNA Master SYBR Green I master mix containing FastStart Taq DNA polymerase, reaction buffer, dNTP mix (200 µMol for each nucleotide with dTTP substituted for dUTP), SYBR Green I dye and 10 mMol MgCl₂. An additional 3.0 mMol MgCl₂ was added, as well as 10 pMol *c-kit* and *ACTB* internal primers, respectively, 13.4 µL PCR grade water and 2 µL of sample cDNA to give a total sample volume of 20 µL. An initial denaturation step lasting 10 min at 95 °C was followed by 45 cycles of denaturation for 10 s at 95 °C, annealing for 5 s at 57 °C (55 °C for *ACTB*) and extension for 10 s at 72 °C. Melting curve analysis was also performed to monitor the specificity of the PCR products generated and to allow detection of samples contaminated with genomic DNA.

Real-time PCR data analysis

Relative gene expression levels were calculated using the 3.5.3. Real time machine software programme of the LC 1.5 instrument package (Roche). The house-keeping gene *ACTB* was used to allow relative quantification of *c-kit* expression using the delta CT method (Livak and Schmittgen, 2001). Expression levels of *c-kit* were normalised against *ACTB* and compared with the standard curves for the actual quantification values. The specificity control data of the reaction were obtained following melting curve analysis using the same software.

Immunohistochemical examination for *c-Kit*

The immunohistochemical labelling procedure was as previously described (Hudson et al., 2001; Fintl et al., 2004). The remainder of the tissue samples were immediately placed in 10% phosphate-buffered formalin and fixed for at least 24 h and for <4 weeks. The tissues were rinsed in water and cryoprotected in graded sucrose solutions (10% and 30%, respectively) before being frozen rapidly in isopentane pre-cooled in dry ice. Frozen sections were cut sequentially at 10 µm thickness and mounted on Tespa (3-aminopropyltriethoxysilane)-coated slides (Sigma Aldrich) and allowed to air-dry overnight. The sections were then incubated for 30 min in 0.3% hydrogen peroxide in methanol to quench endogenous peroxidase activity. Non-specific antibody binding was blocked by 60 min incubation in 1% goat serum (Vector Laboratories) in phosphate-buffered saline (PBS).

Sections were incubated overnight at 4 °C in humid chambers using a purified rabbit polyclonal antibody (Ab-1, Oncogene Research Products) at a dilution of 1 µg/mL. This antibody was raised against a peptide at the carboxyterminus of the p145 human *c-Kit* protein. After washing with PBS, the sections were incubated for 60 min at room temperature with biotin-conjugated goat anti-rabbit immunoglobulin (Vector Laboratories) at a concentration of 1:200. Primary antibody binding was then revealed using the avidin–biotin (ABC) method (Vectastain Elite ABC Kit, Vector Laboratories) using a diaminobenzidine substrate (BDH Laboratory Supplies). Sections were dehydrated in ethanol, cleared in xylene and then mounted in Depex (Merck).

Negative controls were prepared in a similar manner except that the primary antibody was replaced with normal rabbit serum. Positive controls were performed using tissue from a normal control animal from a previous study that had abundant *c-Kit* immunoreactivity (Fintl et al., 2004).

All samples were stained by the haematoxylin and eosin (HE) method to assess

¹ See: www1.qiagen.com/HB/OmniscriptRTKit_EN.

² See: <http://www.ebi.ac.uk/Tools/clustalw/www.ensembl.org/>.

³ See: http://frodo.wi.mit.edu/cgi-bin/primer3/primer3_www.cgi.

Table 2

Oligonucleotides (listed in the 5' to 3' direction) for amplifying segments of equine *c-kit* and *ACTB* for real-time PCR analysis.

DNA segment	DNA sequence	Orientation	PCR annealing temperature (°C)	Amplicon length (bp)
Equine <i>c-kit</i>	CCC ACC AAG	Forward	55	293
	ACA GAC AAG AG			
	CGA GCA TTT CCT	Reverse	55	
Equine <i>β-actin</i>	TTG ACC AC	Forward	55	500
	TGG GCC AGA			
	AGG ACT CAT AC	Reverse	55	
	CTT GAT GTC ACC			
	CAC GAT TT			

Bp, base pairs.

tissue integrity. This assessment included an evaluation of villous height in the small intestinal samples, of mucosal integrity and of the presence of changes such as oedema, haemorrhage and inflammation in the submucosa and tunica muscularis.

Immunohistochemical data analysis

Immunohistochemical labelling was graded semi-quantitatively as previously described (Hudson et al., 2001; Fintl et al., 2004). Two independent observers (CF and NPHH) evaluated all sections. The grades allocated to each animal were based on the examination of six adjacent sections. The myenteric plexus region and circular muscle layer were graded separately. In addition, a combined myenteric plexus and circular muscle grade for each sample was obtained by adding these two grades together. The absence of c-Kit immunoreactivity was graded as '0', sparse labelling as '1', moderate as '2' and abundant as '3'. In the event of disagreement between the two observers, a consensus grade was assigned following a joint review of the sections. Inter-observer variability in the immunohistochemical grading of the samples was also assessed.

Statistical analyses

Real-time PCR data were transformed to the Log_{10} and presented as mean \pm the standard error of the mean (SE). Statistical analysis of differences in gene expression between control and affected animals was performed using a two sample Student's *t* test (Minitab v15).

A Mann-Whitney test was used to assess the statistical significance of the immunohistochemical data. The level of significance was set at $P \leq 0.05$.

Results

Real-time PCR analysis

The initial PCR reactions identified the two target genes, *c-kit* and *ACTB* (Fig. 1), by the identification and subsequent sequencing of the amplified products. The levels of gene expression of *c-kit* relative to the reference gene *ACTB* in the respective categories were 6.9053 (\pm SE 4.5820) for the small intestinal control group, 0.0006 (\pm 0.0001) for the small intestinal 'colic' group, 0.0022 (\pm 0.0005) for the large intestinal control group and 0.3480 (\pm 0.2525) for the large intestinal 'colic' group. The real-time PCR data demonstrated no significant difference in the normalised *c-kit* transcription values between the small intestinal control and colic groups ($P = 0.132$) (Fig. 2a). No significant difference was evident between the normalised *c-kit* transcription values in the large intestinal control and colic groups ($P = 0.142$) (Fig. 2b). The melting curve analysis verified amplification of only one product eliminating the possibility of contamination with genomic DNA.

Immunohistochemical analysis

A mild to moderate, predominantly monocytic inflammatory infiltrate with accompanying oedema was noted in the mucosa and submucosa in approximately half of the diseased intestinal samples. Mild mucosal erosion and villous stunting were observed

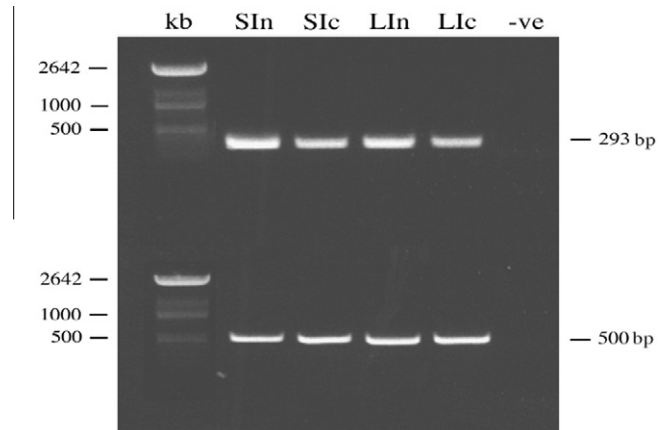


Fig. 1. Electrophoresis gel with the nested gene products *c-kit* (293 bp) (top row) and *β-actin* (*ACTB*) (500 bp) (bottom row) using the respective internal primers for one horse in each of the four groups. SIn, small intestine (normal group); SIc, small intestine (colic group); LIn, large intestine (normal group); LIc, large intestine (colic group); -ve, negative control; kb, kilobase; bp, base pairs.

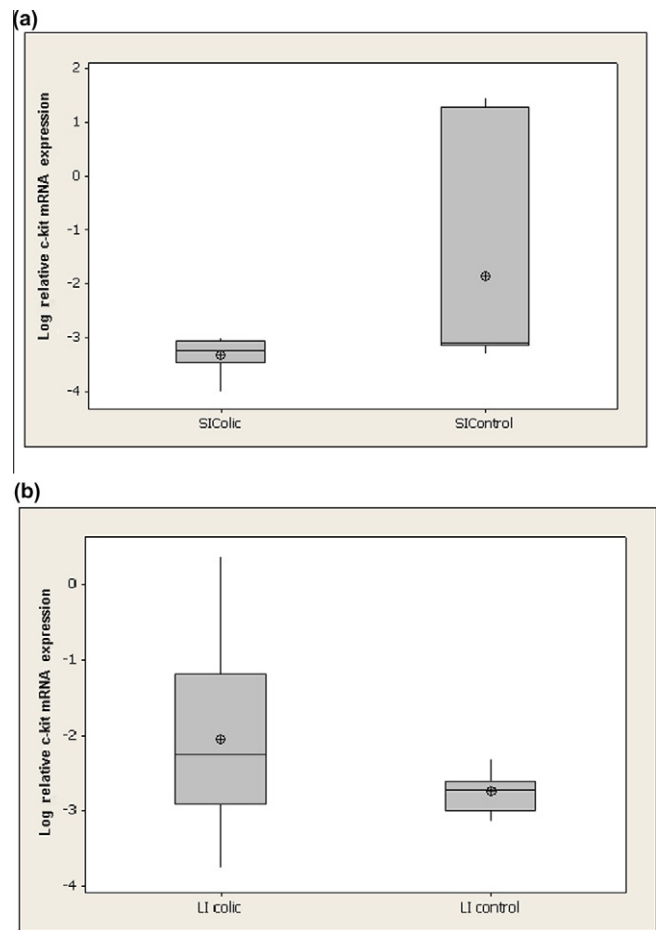


Fig. 2. (a) Log_{10} of relative *c-kit* mRNA expression in the small intestine of control horses (SIcontrol) and in horses with small intestinal colic (SIcolic); (b) Log_{10} relative *c-kit* mRNA expression in the large intestine of control horses (LI control) and in horses with large intestinal lesion (LI colic).

in all animals except for one from the small intestinal colic group. All samples (apart from those from this horse) were of satisfactory

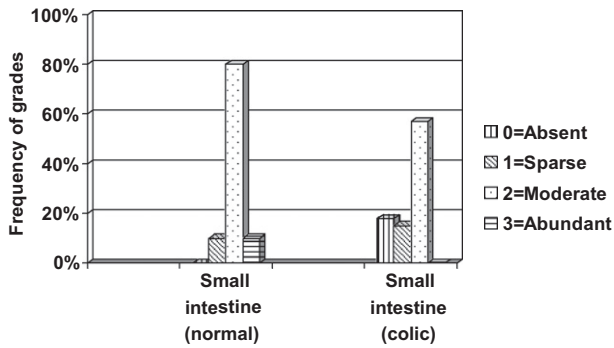


Fig. 3. Density of interstitial cells of Cajal in the myenteric plexus region of the small intestine of normal control horses ($n = 8$) and in those affected with colic ($n = 7$). Frequency grades (%) represent the proportion of specimens assigned the following immunohistochemical density grading: absent (0), sparse (1), moderate (2) and abundant (3).

quality for immunohistochemical assessment and were therefore included in the statistical analysis.

Interstitial cells of Cajal, positive for c-Kit protein, were detected in the SI and pelvic flexure samples with a morphology and distribution similar to that previously described (Hudson et al., 1999). There was no significant difference in the degree of c-Kit immunoreactivity in the myenteric plexus (MP) or circular muscle (CM) regions ($P = 0.298$ and $P = 0.183$, respectively) between normal and diseased SI samples (Figs. 3 and 4). The combined semi-quantitative c-Kit immunoreactivity grades for the MP and CM regions in the SI for the normal and affected groups were not significantly different ($P = 0.272$).

Although there was no significant difference in c-Kit immunoreactivity in the MP region between normal and affected large intestinal samples ($P = 0.067$) (Fig. 5), there was a significant reduction in the degree of labelling in the CM ($P = 0.043$) (Figs. 6 and 7). When the combined grades were examined, there was also a significant reduction between normal and affected cases in the LI ($P = 0.025$). There was no significant difference in inter-observer variability in the grades allocated to the samples ($P = 0.815$) demonstrating consistency in the grading system.

Discussion

Few studies have assessed *c-kit* transcription in the ICC. Tong et al. (2005) demonstrated a reduction in both *c-kit* mRNA and in c-Kit protein in the sigmoid colon of human patients with slow transit constipation and Nishimura et al. (2007) found reductions

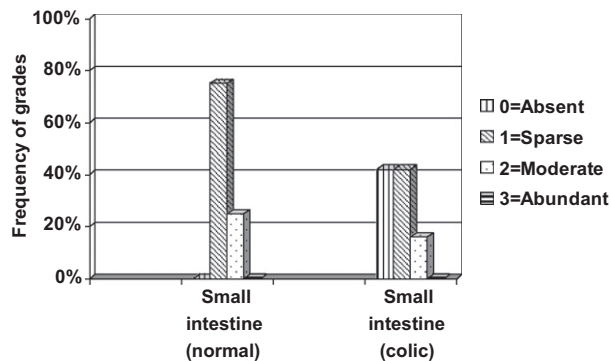


Fig. 4. Density of interstitial cells of Cajal in the circular muscle of the small intestine of normal control horses ($n = 8$) and in those affected with colic ($n = 7$). Frequency grades (%) represent the proportion of specimens assigned the following immunohistochemical density grading: absent (0), sparse (1), moderate (2) and abundant (3).

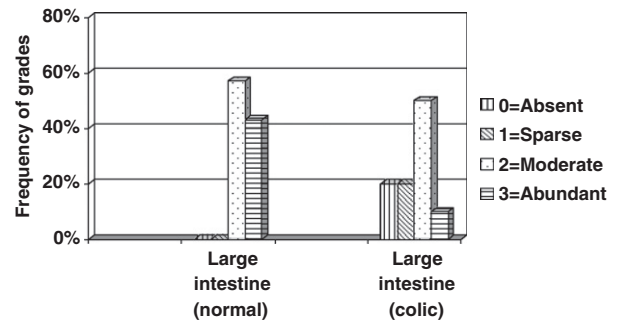


Fig. 5. Density of interstitial cells of Cajal in the myenteric plexus region of the large intestine of normal control horses ($n = 7$) and in those affected with colic ($n = 10$). Frequency grades (%) represent the proportion of specimens assigned the following immunohistochemical density grading: absent (0), sparse (1), moderate (2) and abundant (3).

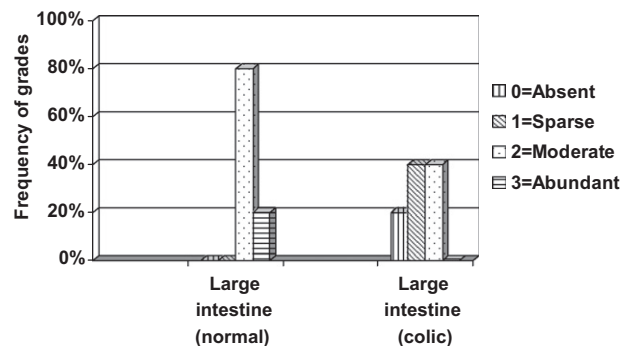


Fig. 6. Density of interstitial cells of Cajal in the circular muscle of the large intestine of normal control horses ($n = 7$) and in those affected with colic ($n = 10$). Frequency grades (%) represent the proportion of specimens assigned the following immunohistochemical density grading: absent (0), sparse (1), moderate (2) and abundant (3).

in both the *c-kit* transcription rate and in the number of c-Kit immunoreactive ICC in the distal colon of rats three months following mesenteric transection. Both studies suggested these changes were result of disruptions to *c-kit*/SCF signalling pathways (Tong et al., 2005; Nishimura et al., 2007).

The findings of the current study demonstrate that horses with obstructive disorders of the large intestine have significant reductions in c-Kit protein expression in their ICC but no alteration to *c-kit* gene transcription. This discrepancy is intriguing and may have a number of explanations. It is possible that the duration of the intestinal disease was a factor as the time interval between the first signs of colic and surgery (when samples were collected), ranged from 2 to 12 h. This finding is in contrast to previous studies that involved time intervals of weeks and months (Tong et al., 2005; Nishimura et al., 2007). If SCF signalling is key to *c-kit* transcription, it is possible that the time intervals in the current study were too short to result in a significant decline in SCF production by smooth muscle cells and enteric neurons. It is also possible that the intestinal insults were not severe enough to significantly alter SCF production. In a clinical study such as this, the degree of such insults may have varied considerably.

Failure to detect changes in *c-kit* transcription rates could also occur if regulation of protein production was post-transcriptional and if a pool of mRNA exists. Protein synthesis represents a key control point for gene regulation that enables cells to respond rapidly to changes in the extracellular environment by producing specific proteins from a stored pool of mRNA (Dever, 2002). Conversely, in response to cell starvation and stress, reductions in the rate of protein synthesis occurs which may protect against

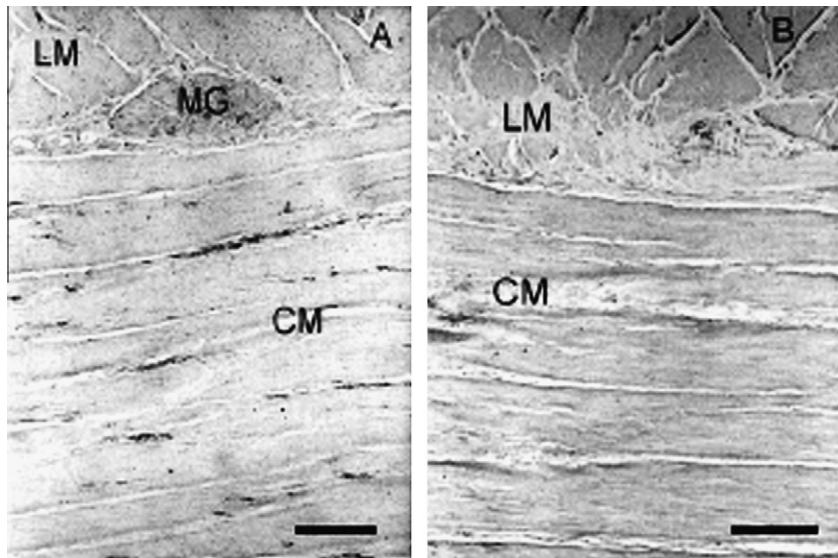


Fig. 7. Photomicrograph illustrating circular muscle of the pelvic flexure of a control animal (A) and of a horse with a large intestinal colic (B). There is a reduced (grade 1) c-Kit immunoreactivity in the affected animal relative to the control (grade 2). LM, longitudinal muscle; CM, circular muscle; MG, myenteric ganglion. Scale bar = 250 μ m.

the deleterious effects of toxins (Hinnebusch, 1994). Although the mechanism controlling translation of the c-Kit receptor of the ICC remains unknown, it seems reasonable to assume that such mechanisms respond similarly to cell stress.

It is possible that the reduced c-Kit immunoreactivity was caused by acute injury to the c-Kit receptor to a rate and extent that exceeded the rate of new protein synthesis. Previous studies have demonstrated ultrastructural changes to the ICC during experimentally-induced inflammation (Der et al., 2000; Suzuki et al., 2004). Suzuki et al. (2004) investigated the role of resident macrophages during intestinal inflammation and damage to the ICC in endothelin receptor-null rats. Through genetic modification, these rats have segmental aganglionosis of the intestine making them a model of Hirschsprung's disease in humans. Increased endotoxin in the intestinal tract of these animals following bacterial overgrowth is thought to lead to activation of resident macrophages with a subsequent increase in the expression of interleukin (IL)-1 β , IL-6 and CD14 (a lipopolysaccharide receptor) by these cells (Suzuki et al., 2004). These bioactive substances might then affect the number and function of adjacent ICC. It is possible that a similar process occurred in the current study with alterations in the colonic flora and the local release of endotoxin resulting in ICC injury and reduced c-Kit antigen.

Yanagida et al. (2004) demonstrated disruption to the ICC network 5 h after surgical manipulation of the intestinal tract in mice and suggested that this was due to the activation of tissue macrophages. The fact that such disruption can occur within hours lends support to the idea that the reduced c-Kit antigen labelling in the current study could be the result of the effect of inflammatory mediators rather than reduced c-Kit transcription or translation rates. Alternatively, one could speculate that reduced c-Kit immunoreactivity was not the result of direct injury but rather a consequence of receptor internalisation. In human mast cells, the c-Kit receptor is a rapidly cycling cell surface receptor that internalises upon binding the SCF ligand (Babina et al., 2006). This is an active process with c-Kit levels reduced to a minimum after 3 h and levels fail to return to normal within 24 h. Furthermore, it is not known if the antibody-binding site is affected by the binding of SCF. Both these points demonstrate the need for further functional, electrophysiological studies to be carried out in order to clarify whether reduced immunoreactivity is indicative of ICC loss if this is accompanied by alterations in slow-wave activity (Sakurai, 2003).

Another factor to be considered is that in the majority of large intestinal samples previously studied, the organ had been distended by gas or ingesta. We did not attempt to assess any possible influence of distension on ICC density. However, in the semi-quantitative grading, observers scanned full-thickness sections. In addition, we speculate that the elastic nature of the intestinal wall means it would likely return to its normal size quickly following surgical decompression. As all our samples were collected following such decompression we considered that the effect of distension on ICC density would have been minimal.

Ideally up to eight reference genes should have been run on all the samples in the current study to determine the optimum reference genes. Given limited cDNA and financial restrictions the use of *ACTB* was considered an acceptable 'housekeeping' gene. Furthermore, recent publications suggest *ACTB* would be an appropriate housekeeping gene for equine intestine (Solinger and Sonea, 2008).

In terms of clinical significance, other studies in various species including horses, have demonstrated that altered ICC are associated with changes in slow-wave activity and intestinal motility (Ward et al., 1994; Torihashi et al., 1995, 1999; Hudson et al., 2001, 2002; Yanagida et al., 2004). Thus disruption to the ICC network demonstrated in this study may also have had similar effects although functional electrophysiological studies would be required to verify this. Further studies will also be required to investigate the effect of inflammatory mediators on c-kit gene expression and of possible alterations in SCF production.

Conclusions

This study found a significant reduction in c-Kit immunoreactivity in the ICC of horses with large intestinal obstructive disorders relative to controls but no significant difference in the transcription of the c-kit gene between normal and affected animals. Further studies will be required to elucidate the mechanisms regulating c-Kit expression and to assess the pathophysiological significance of these findings.

Conflict of interest statement

None of the authors of this paper has a financial or personal relationship with other people or organisations that could inappropriately influence or bias the content of the paper.

Acknowledgements

Constanze Fintl was a Horserace Betting Levy Board Research Training Scholar. Neil Hudson was supported by The Dowager Countess Eleanor Peel Trust. The authors would like to thank Colin Warwick for the illustrations, Gordon Goodall and Neil MacIntyre for technical advice on sample processing and Drs Susan Rhind and Elspeth Milne for advice on tissue sections. We would also like to thank Janet Smith and the Liverpool Colic Survival Study supported by The Home of Rest for Horses for help with data retrieval.

References

- Babina, M., Rex, C., Thienmann, F., Artuc, M., Henz, B.M., Zuberbier, T., 2006. Baseline and stimulated turnover of cell surface c-Kit expression in different types of human mast cells. *Experimental Dermatology* 15, 530–537.
- Clements, D.N., Carter, S.D., Innes, J.F., Ollier, W.E., Day, P.J., 2006. Analysis of normal and osteoarthritic canine cartilage mRNA expression by quantitative polymerase chain reaction. *Arthritis Research and Therapy* 8, R158.
- Der, T., Bercik, P., Donnelly, G., Jackson, T., Berezin, I., Collins, S.M., Huizinga, J.D., 2000. Interstitial cells of Cajal and inflammation-induced motor dysfunction in the mouse small intestine. *Gastroenterology* 119, 1590–1599.
- Dever, T.E., 2002. Gene-specific regulation by general translation factors. *Cell* 108, 545–556.
- Fintl, C., Hudson, N.P.H., Mayhew, I.G., Edwards, G.B., Proudman, C.J., Pearson, G.T., 2004. The interstitial cells of Cajal (ICC) in equine colic: an immunohistochemical study of horses with obstructive disorders of the small and large intestines. *Equine Veterinary Journal* 36, 474–479.
- Hinnebusch, A.G., 1994. Translational control of *GCN4*: an *in vivo* barometer of initiation-factor activity. *Trends in Biochemical Sciences* 19, 409–414.
- Hudson, N.P.H., Pearson, G.T., Kitamura, N., Mayhew, I.G., 1999. An immunohistochemical study of interstitial cells of Cajal (ICC) in the equine gastrointestinal tract. *Research in Veterinary Science* 66, 265–271.
- Hudson, N.P.H., Mayhew, I.G., Pearson, G.T., 2001. A reduction in interstitial cells of Cajal in horses with equine dysautonomia (grass sickness). *Autonomic Neuroscience: Basic and Clinical* 92, 37–44.
- Hudson, N.P.H., Mayhew, I.G., Pearson, G.T., 2002. Presence of *in vitro* electrical activity in the ileum of horses with enteric nervous system pathology: equine dysautonomia (grass sickness). *Autonomic Neuroscience: Basic and Clinical* 9, 119–126.
- Livak, K.J., Schmittgen, T.D., 2001. Analysis of relative gene expression data using real-time quantitative PCR and the $2^{-\Delta\Delta C_T}$ method. *Methods* 25, 402–408.
- Maeda, H., Yamagata, A., Nishikawa, S., 1992. Requirement of c-kit for development of intestinal pacemaker system. *Development* 116, 369–375.
- Nishimura, M., Koda, K., Oda, K., Shimizu, K., Miyazaki, M., 2007. Mesenteric transection decreases expression of interstitial cells of Cajal in an experimental model. *British Journal of Surgery* 94, 483–490.
- Sakurai, S., 2003. Alterations of interstitial cells of Cajal and gastrointestinal motility disorders. *Journal of Gastroenterology* 38, 414–416.
- Solinger, N., Sonea, I.M., 2008. Distribution of the neurokinin-1 receptor in equine intestinal smooth muscle. *Equine Veterinary Journal* 40, 321–325.
- Suzuki, T., Won, K.-J., Horiguchi, K., Kinoshita, K., Hori, M., Torihashi, S., Momotani, E., Itoh, K., Hirayama, K., Ward, S.M., Sanders, K.M., Ozaki, H., 2004. Muscularis inflammation and the loss of interstitial cells of Cajal in the endothelin ETB receptor null rat. *American Journal of Gastrointestinal and Liver Physiology* 287, G638–G646.
- Tong, W.-D., Liu, B.-H., Zhang, L.-Y., Xiong, R.-P., Liu, P., Zhang, S.-B., 2005. Expression of *c-kit* messenger ribonucleic acid and *c-kit* protein in sigmoid colon of patients with slow transit constipation. *Intestinal Journal of Colorectal Disease* 20, 363–367.
- Torihashi, S., Ward, S.M., Nishikawa, S.-I., Nishi, K., Kobayashi, S., Sanders, K.M., 1995. C-kit-dependent development of interstitial cells and electrical activity in the murine gastrointestinal tract. *Cell and Tissue Research* 280, 97–111.
- Torihashi, S., Nishi, K., Tokutomi, Y., Nishi, T., Ward, S.M., Sanders, K.M., 1999. Blockade of kit signalling induces transdifferentiation of interstitial cells of Cajal to a smooth muscle phenotype. *Gastroenterology* 117, 140–148.
- Traub-Dargatz, J.L., Koprak, C.A., Seitzinger, A.H., Garber, L.P., Forde, K., White, N.A., 2001. Estimate of the national incidence of and operation-level risk factors for colic among horses in the United States, Spring 1998–1999. *Journal of the American Veterinary Medical Association* 219, 67–71.
- Vanderwinden, J.-M., Rumessen, J.J., 1999. Interstitial cells of Cajal in human gut and gastrointestinal disease. *Microscopy Research and Technique* 47, 344–360.
- Ward, S.M., Burns, A.J., Torihashi, S., Sanders, K.M., 1994. Mutation of the proto-oncogene *c-kit* blocks development of interstitial cells and electrical activity in the murine gastrointestinal tract. *Journal of Physiology* 480, 91–97.
- Ward, S.M., Ordög, T., Bayguinov, J.R., Horowitz, B., Epperson, A., Shen, L., Westphal, H., Sanders, K.M., 1999. Development of interstitial cells of Cajal and pacemaking in mice lacking enteric nerves. *Gastroenterology* 117, 584–594.
- Ward, S.M., Sanders, K.M., Hirst, G.D., 2004. Role of interstitial cells of Cajal in neural control of gastrointestinal smooth muscles. *Neurogastroenterology and Motility* 16, 112–117.
- Yanagida, H., Yanase, H., Sanders, K.M., Ward, S.M., 2004. Intestinal surgical resection disrupts electrical rhythmicity, neural responses, and interstitial cell networks. *Gastroenterology* 127, 1748–1759.