



THE UNIVERSITY *of* EDINBURGH

Edinburgh Research Explorer

Effect of IV alteplase on the ischemic brain lesion at 24-48 hours after ischemic stroke

Citation for published version:

IST-3 Collaborative Group, Mair, G, von Kummer, R, Morris, Z, von Heijne, A, Bradey, N, Cala, L, Peeters, A, Farrall, A, Adami, A, Potter, G, Sandercock, P, Lindley, RI & Wardlaw, J 2018, 'Effect of IV alteplase on the ischemic brain lesion at 24-48 hours after ischemic stroke', *Neurology*, vol. 91, no. 22, pp. e2067-e2077. <https://doi.org/10.1212/WNL.0000000000006575>

Digital Object Identifier (DOI):

[10.1212/WNL.0000000000006575](https://doi.org/10.1212/WNL.0000000000006575)

Link:

[Link to publication record in Edinburgh Research Explorer](#)

Document Version:

Publisher's PDF, also known as Version of record

Published In:

Neurology

Publisher Rights Statement:

This is an open access article distributed under the terms of the Creative Commons Attribution License 4.0 (CC BY), which permits unrestricted use, distribution, and reproduction in any medium, provided the original work is properly cited.

General rights

Copyright for the publications made accessible via the Edinburgh Research Explorer is retained by the author(s) and / or other copyright owners and it is a condition of accessing these publications that users recognise and abide by the legal requirements associated with these rights.

Take down policy

The University of Edinburgh has made every reasonable effort to ensure that Edinburgh Research Explorer content complies with UK legislation. If you believe that the public display of this file breaches copyright please contact openaccess@ed.ac.uk providing details, and we will remove access to the work immediately and investigate your claim.



Effect of IV alteplase on the ischemic brain lesion at 24–48 hours after ischemic stroke

Grant Mair, MD, Rüdiger von Kummer, MD, Zoe Morris, MBBS, Anders von Heijne, MD, Nick Bradey, MBBS, Lesley Cala, MD, André Peeters, MD, Andrew J. Farrall, MD, Alessandro Adami, MD, Gillian Potter, MD, Peter A.G. Sandercock, DM, Richard I. Lindley, MD, and Joanna M. Wardlaw, MD, for the IST-3 Collaborative Group

Correspondence

Prof. Wardlaw
joanna.wardlaw@ed.ac.uk

Neurology® 2018;00:1-11. doi:10.1212/WNL.0000000000006575

Abstract

Objective

To determine whether alteplase alters the development of ischemic lesions on brain imaging after stroke.

Methods

The Third International Stroke Trial (IST-3) was a randomized controlled trial of IV alteplase for ischemic stroke. We assessed CT or brain MRI at baseline (pretreatment) and 24 to 48 hours posttreatment for acute lesion visibility, extent, and swelling, masked to all other data. We analyzed associations between treatment allocation, change in brain tissue appearances between baseline and follow-up imaging, and 6-month functional outcome in IST-3. We performed a meta-analysis of randomized trials of alteplase vs control with pre- and post-randomization imaging.

Results

Of 3,035 patients recruited in IST-3, 2,916 had baseline and follow-up brain imaging. Progression in either lesion extent or swelling independently predicted poorer 6-month outcome (adjusted odds ratio [OR] = 0.92, 95% confidence interval [CI] 0.88–0.96, $p < 0.001$; OR = 0.73, 95% CI 0.66–0.79, $p < 0.001$, respectively). Patients allocated alteplase were less likely than controls to develop increased lesion visibility at follow-up (OR = 0.77, 95% CI 0.67–0.89, $p < 0.001$), but there was no evidence that alteplase reduced progression of lesion extent or swelling. In meta-analysis of 6 trials including IST-3 ($n = 4,757$), allocation to alteplase was associated with a reduction in ischemic lesion extent on follow-up imaging (OR = 0.85, 95% CI 0.76–0.95, $p = 0.004$).

Conclusion

Alteplase was associated with reduced short-term progression in lesion visibility. In meta-analysis, alteplase reduced lesion extent. These findings may indicate that alteplase improves functional outcome by reducing tissue damage.

Classification of evidence

This study provides Class II evidence that IV alteplase impedes the progression of ischemic brain lesions on imaging after stroke.

MORE ONLINE

→ Class of Evidence

Criteria for rating therapeutic and diagnostic studies

NPub.org/coe

From Edinburgh Imaging, and UK Dementia Research Institute at the University of Edinburgh and Centre for Clinical Brain Sciences (G.M., Z.M., A.J.F., J.M.W.), and Division of Clinical Neurosciences (P.A.G.S.), University of Edinburgh, UK; Department of Neuroradiology (R.v.K.), Dresden University Stroke Centre, Germany; Danderyd Hospital (A.v.H.), Stockholm, Sweden; Neuroradiology (N.B.), James Cook University Hospital, Middlesbrough, UK; School of Medicine (L.C.), University of Western Australia; Cliniques Universitaires St Luc (A.P.), Neurologie, Belgium; Stroke Center (A.A.), Department of Neurology, IRCCS Sacro Cuore Don Calabria Hospital, Negrar, Verona, Italy; Department of Neuroradiology (G.P.), Salford Royal NHS Foundation Trust, Manchester, UK; and Westmead Hospital Clinical School and The George Institute for Global Health (R.I.L.), University of Sydney, Australia.

Go to Neurology.org/N for full disclosures. Funding information and disclosures deemed relevant by the authors, if any, are provided at the end of the article.

IST-3 Collaborative Group coinvestigators are listed at links.lww.com/WNL/A749.

The Article Processing Charge was funded by RCUK.

This is an open access article distributed under the terms of the Creative Commons Attribution License 4.0 (CC BY), which permits unrestricted use, distribution, and reproduction in any medium, provided the original work is properly cited.

Glossary

ASPECTS = Alberta Stroke Program Early CT Score; **CI** = confidence interval; **DWI** = diffusion-weighted imaging; **ECASS** = European Cooperative Acute Stroke Study; **IQR** = interquartile range; **IST-3** = Third International Stroke Trial; **MCA** = middle cerebral artery; **NIHSS** = NIH Stroke Scale; **OR** = odds ratio.

In patients presenting acutely with ischemic stroke, brain imaging can demonstrate ischemia and infarction based on water shifts within brain tissue.¹ On CT, brain tissue becomes gradually more hypoattenuated as its water content increases.² Within the first few hours after stroke onset, there is a reduction in gray matter attenuation so that gray matter becomes of similar attenuation to normal white matter resulting in the well-described loss of visibility of the insular ribbon, basal ganglia, or affected cortex.^{3,4} These early attenuation changes of the brain are often not apparent immediately after symptom onset, but by 24 hours, affected brain is usually obviously hypoattenuated compared with normal brain,⁵ and is specific for infarction.⁶ On MRI, diffusion-weighted imaging (DWI) can show hyperintensity in ischemic tissue within minutes of stroke onset. Hours later, the lesion also becomes hyperintense on other T2-weighted sequences⁷ and, similar to hypoattenuation on CT, this later change usually indicates infarction.⁸ Both CT and MRI show brain tissue swelling as a secondary indicator of injury.

Treatment with IV alteplase within the first few hours after stroke improves long-term clinical outcome and accelerates disappearance of arterial obstruction.^{9–11} However, it is unclear whether IV alteplase modifies progression of the appearance of acutely affected brain tissue on imaging (i.e., the ischemic lesion) over the first 24 to 48 hours after stroke, or whether any short-term alteplase-related alteration in lesion progression might explain the long-term improvement in functional outcome.

The Third International Stroke Trial (IST-3) was a large multicenter, randomized controlled trial testing IV alteplase given within 6 hours of ischemic stroke.¹² In the present analysis, our aim was to assess the effect of alteplase on any change in ischemic lesion appearance on CT or MRI between pretreatment (baseline) and 24- to 48-hour posttreatment follow-up imaging. We investigated whether alteplase modified short-term progression of CT hypoattenuation or magnetic resonance T2-weighted hyperintensity (lesion visibility), lesion extent, or tissue swelling compared to control and tested whether alteration in short-term progression of the lesion appearance predicted long-term functional outcome after ischemic stroke. We set our results in the context of a meta-analysis of all available data from randomized controlled trials.

Methods

Standard protocol approvals, registrations, and patient consents

IST-3 was an international, multicenter PROBE (prospective, randomized, open-label, blinded endpoint) trial of

IV alteplase (recombinant tissue plasminogen activator) for ischemic stroke.¹² Ethical approval was granted by the Scotland A research ethics committee and by local ethics committees. IST-3 was registered with Current Controlled Trials (ISRCTN25765518). Enrollment, data collection, and CONSORT (Consolidated Standards of Reporting Trials) compliance have been described.^{12,13}

Briefly, adult patients with acute stroke of any severity (assessed with the NIH Stroke Scale [NIHSS]), with no upper age limit, were eligible if treatment could be started within 6 hours of symptom onset and brain imaging had excluded intracranial hemorrhage and structural stroke mimics. Informed consent for research was obtained for all patients. The full trial protocol is available: dcn.ed.ac.uk/ist3/. IST-3 primary results are published.¹²

Patients were randomly allocated to IV alteplase (0.9 mg/kg) or control. Treating clinicians used an automated telephone or online system to enter baseline data and obtain a randomized treatment allocation. Excepting the first 276 patients (double-blind phase), treatment was given open label. Patients were followed up at 6 months by postal or telephone questionnaire to assess functional status with the Oxford Handicap Scale¹⁴ by assessors who were masked to clinical and imaging findings and treatment allocation.

Brain imaging

The IST-3 imaging protocol has been described^{4,12,15}: CT or MRI was required pretreatment at baseline and follow-up. For CT, the maximum slice thickness was 5 mm through the posterior fossa and 10 mm for the cerebrum, but most CT was performed with thinner slices. MRI included T1, T2, DWI, fluid-attenuated inversion recovery, and T2*. DICOM (Digital Imaging and Communications in Medicine) was collated centrally and anonymized. We excluded patients from the present analysis if images were not received centrally.

Image analysis

A panel of 10 experienced neuroradiologists and neurologists assessed imaging with a secure online viewing tool, which was developed after extensive review of early ischemic signs³ and observer reliability testing.^{4,16,17} The Systematic Image Review System includes a validated data collection pro forma (available at ed.ac.uk/edinburgh-imaging/image-analysis-tools), which underwent extensive observer reliability testing^{16,17} to ensure there was satisfactory agreement ($\kappa > 0.7$) between readers for all imaging features assessed.⁴ Image assessors were masked to clinical data and treatment

allocation. We scored baseline imaging (prerandomization) separately and blindly to follow-up imaging (24–48 hours after stroke onset) and vice versa, although assessors were aware if imaging was acquired at baseline or follow-up.

We reviewed all baseline and follow-up imaging for evidence of acute ischemia/recent infarct (i.e., the acute lesion) using the validated visual scores to assess 3 features: (1) acute lesion visibility; (2) location and extent of the lesion; and (3) lesion swelling.

Acute lesion visibility

We graded acute lesion visibility on a 3-point ordinal scale to reflect the range of progressive tissue changes seen after ischemic stroke, i.e., increasingly more visible CT hypoattenuation or MRI T2-weighted hyperintensity (e.g., figure 1). This schema reflects well-described tissue changes^{3,4,16,17}:

- On CT, we defined acute lesion visibility as grade 0 (no acute lesion visible); subtle, or grade 1 (gray matter attenuation equal to that of normal white matter); and severe, or grade 2 (gray and/or white matter attenuation lower than normal white matter).

- On MRI, we defined lesions as grade 0 (no lesion); subtle, or grade 1 (hyperintense area on DWI but not on other T2-weighted sequences); and severe or grade 2 (hyperintense on T2-weighted sequences with or without DWI hyperintensity).⁴

Location and extent of acute lesion

We used the IST-3 Ischemic Lesion Score and ASPECTS (Alberta Stroke Program Early CT Score) to assess the location and extent of acute lesions.^{18,19}

The IST-3 Ischemic Lesion Score records the lesion extent according to common patterns of infarction in all major vascular territories (anterior, middle [MCA], and posterior cerebral arteries), the brainstem, or cerebellum, each with subdivisions. It includes an 8-point scale for the MCA territory.^{4,12,18} We condensed the detailed scores into fewer groups for analysis, as described previously^{4,12}: 0 = no acute lesion; 1 = small (e.g., lacunar or small cortical lesion); 2 = medium (e.g., striatocapsular lesion or superficial MCA territory); 3 = large (e.g., complete MCA territory); and 4 = very large (e.g., complete MCA plus anterior cerebral artery territories). See data available from Edinburgh DataShare (figure e-1, dx.doi.org/10.7488/ds/2367).

ASPECTS assesses lesion extent only in the MCA territory, in 10 sections, scoring a point for each area that is affected, and ranges from 10 = normal (no MCA territory lesion) to 0 = acute lesion affecting the entire MCA territory.¹⁹

Acute lesion swelling

We graded tissue swelling on a validated 7-point scale based on sulcal or ventricular effacement or midline shift, from none (0) to severe (6 = midline shift with effacement of the basal cisterns).¹⁸ See data available from Edinburgh DataShare (figure e-2, dx.doi.org/10.7488/ds/2367).

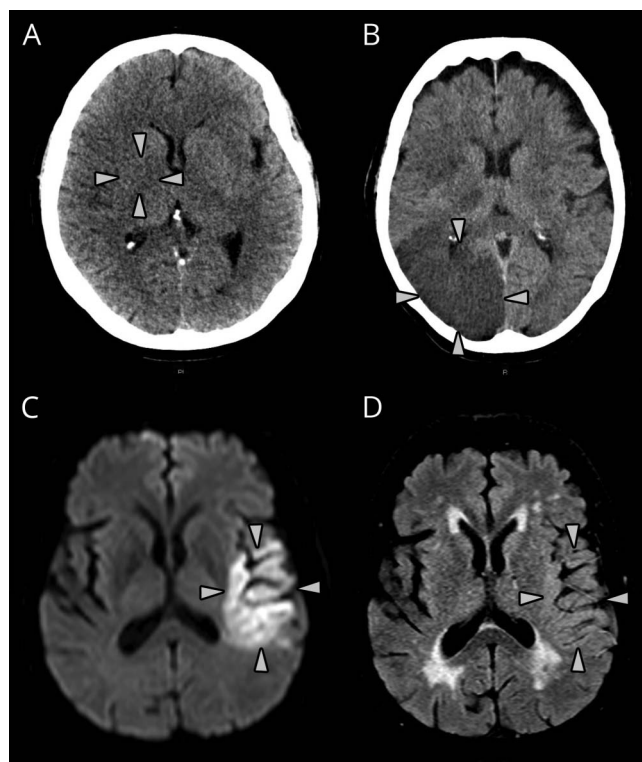
We also assessed baseline scans for leukoaraiosis, atrophy, and old stroke lesions (i.e., prestroke signs) using validated scores.^{4,20–22} We noted the presence of any hemorrhage at follow-up.

Data analysis

We compared baseline and follow-up imaging to detect change in any of the acute ischemic lesion appearances. We subtracted the baseline imaging scores from the follow-up imaging scores. For the variables lesion visibility grade, IST-3 Ischemic Lesion Score, and swelling, a positive value represented imaging progression. For ASPECTS, a negative value represented imaging progression.

We used univariate tests to compare the alteplase and control groups and to assess for associations with imaging progression. We then used multivariable ordinal regression to identify predictors of imaging progression (in those with a significant univariate association, i.e., change in lesion visibility grade) and 6-month functional outcome. Finally, we tested for interactions with alteplase between subgroups of variables predictive of

Figure 1 CT and MRI examples of grading of acute ischemic lesion visibility



(A) CT lesion visibility grade 1; attenuation of affected gray matter (right lentiform nucleus, arrows) equivalent to normal surrounding white matter. (B) CT lesion visibility grade 2; attenuation of affected right occipital lobe (gray and white matter, arrows) less than normal white matter. (C) Diffusion-weighted and (D) fluid-attenuated inversion recovery (T2-based) imaging demonstrating MRI lesion visibility grade 1; acute lesion is clearly visible in panel C (arrows) but only faintly visible in panel D (arrows).

imaging progression ($p < 0.1$) on ordinal regression analysis. Because of the risk of confounding, we did not include ASPECTS and IST-3 Ischemic Lesion Score in the same multivariable models. We adjusted regression analyses for the key outcome predictors of age, NIHSS, time between baseline and follow-up scans, and presence of hemorrhage at follow-up, plus leukoaraiosis, atrophy, and old stroke lesions since we showed previously in IST-3 and other datasets that these pre-stroke signs affect lesion visibility^{16,17} and are adverse prognostic markers^{4,12} (therefore, we did not repeat these tests in the present analysis). To stabilize regression estimates, we grouped the variable *time between scans* into 6 time windows (0–11, 12–23, 24–35, 36–47, 48–59, 60+ hours) and we combined the 3 most severe grades of the Oxford Handicap Scale into a single category, resulting in 5 functional outcome grades (0, 1, 2, 3, 4–6).

We used IBM SPSS Statistics software, version 21.0 (IBM Corp., Armonk, NY) for all analyses unless otherwise stated, and considered $p < 0.05$ significant.

Meta-analysis

We used the 2014 Cochrane systematic review *Thrombolysis for Acute Ischemic Stroke*²³ to identify randomized controlled trials of IV alteplase that reported outcomes by imaging assessment of ischemic lesions at baseline and follow-up. Specifically, we sought comparable data for the 3 imaging features examined in IST-3: namely, acute lesion visibility; lesion extent (scored as *lesion volume* if assessed at only one time point, and *lesion growth* if assessed at more than one time point); and lesion swelling. In addition, for each relevant trial identified, we searched PubMed for any post hoc or subgroup analyses published up to the end of January 2018.

We used Comprehensive Meta-Analysis software, version 2 (Biostat, Englewood, NJ) to compute odds ratios (ORs) of the alteplase effect for each trial dataset and to calculate summary statistics using a random effects model. We used I^2 statistics to assess heterogeneity between studies.

Data availability

IST-3 data are available on request to bona fide researchers via Edinburgh DataShare (datashare.is.ed.ac.uk/handle/10283/1931).

Classification of evidence

Our primary objective was to determine whether alteplase alters the development of ischemic lesions on brain imaging after stroke. This study provides Class II evidence that IV alteplase (0.9 mg/kg) impedes the development of ischemic brain lesions according to 2 distinct imaging features. In IST-3, alteplase reduced short-term progression in lesion visibility (adjusted OR = 0.77, 95% confidence interval [CI] 0.67–0.89), and when combined in meta-analysis with all available randomized controlled trial data, alteplase reduced the extent of the ischemic brain lesion on follow-up imaging (adjusted OR = 0.85, 95% CI 0.76–0.95).

Results

IST-3 recruited 3,035 patients. Baseline or follow-up imaging was not available for central review in 18 (0.6%) and 105 patients (3.5%), respectively. Central imaging review did not occur if the patient had died or was too unwell at follow-up, or if completed scans were never received centrally or were corrupted. Thus, expert-reviewed baseline and follow-up imaging was available for 2,916 patients (96.1%) (data available from Edinburgh DataShare, figure e-3, dx.doi.org/10.7488/ds/2367). Most had noncontrast CT performed at baseline (2,861, 98.1%) and at follow-up (2,766, 94.9%). MRI was used in 55 and 150 patients, respectively.

For the 2,916 patients included in this analysis, 1,416 (48.6%) were male, median age was 81 years (interquartile range [IQR] 72–86 years), and the median baseline NIHSS score was 11 (IQR 6–17). Median time from stroke onset to baseline scan was 154 minutes (IQR 105–215 minutes) while the median time between baseline and follow-up scans was 26 hours (IQR 24–36 hours). Treatment allocation was 1,474 patients (50.5%) to alteplase and 1,442 (49.5%) to control. We found no differences in demographic or clinical characteristics between the 2,916 patients with complete imaging data in these analyses and the 3,035 patients in the whole IST-3 trial (data not shown).

Among the 2,916 patients with complete imaging data, baseline demographic, clinical, and imaging variables were not different between treatment groups (table 1), except that patients in the control group had a slightly longer time lapse between baseline and follow-up imaging (IQR 24–40 vs 23–30 hours in the group allocated to alteplase, $p < 0.001$).

Change in acute lesion between baseline and follow-up in IST-3

We identified an acute lesion (any of reduced tissue CT attenuation/increased T2-weighted hyperintensity, or swelling) in 1,183 patients at baseline and 2,124 patients at follow-up. Most acute lesions involved the MCA territory (baseline 1,088/1,178, 92.4%, follow-up 1,722/2,119, 81.3%). We identified any hemorrhage on 479/2,916 (16.4%) follow-up scans (table 2).

Lesion visibility grade changed between baseline and follow-up in 1,994/2,916 patients (68.4%). Most patients had no visible lesion at baseline (1,754/2,916, 60.2%); in contrast, 2,119/2,916 (72.7%) had a visible lesion at follow-up (table 2). The prevalence of visible ischemic lesions at baseline did not differ between patients who presented early (0–3 hours from symptom onset [40.4%]) vs later (4–6 hours [40.8%]) ($\chi^2 = 0.04$, $p = 0.834$). Some lesions completely disappeared (76/2,916, 2.6%) between baseline and follow-up, fewer became less visible but remained present (11/2,916, 0.4%). Overall, lesion visibility increased in fewer patients allocated to alteplase (936/1,474, 63.5%) than to control (971/1,442, 67.3%), and lesion visibility decreased in more patients allocated to alteplase (46/1,474, 3.1%) than to control (41/1,442, 2.8%) ($p = 0.007$) (table 3).

Table 1 Demographic, clinical, and baseline imaging characteristics of patients allocated to alteplase vs those allocated to control (n = 2,916)

Characteristic	Treatment allocation		p Value for difference
	Alteplase (n = 1,474)	Control (n = 1,442)	
Age, y	81 (72–86)	81 (71–86)	0.712
Sex, male	720 (48.8)	696 (48.3)	0.754
NIHSS score	11 (6–18)	11 (6–17)	0.953
Time from stroke onset to baseline scan, min	155 (106–214)	151 (105–216)	0.966
Time from baseline to follow-up scan, h	26 (23–30)	26 (24–40)	<0.001
OHS grade at 6 mo	3 (2–6)	4 (2–6)	0.152
Baseline imaging appearances			
Visible CT hypodensity or T2-weighted MRI hyperintensity of brain	603 (40.9)	580 (40.2)	0.706
Brain swelling	348 (23.6)	327 (22.7)	0.551
ASPECTS	10 (8–10)	10 (8–10)	0.388
IST-3 ischemic lesion score	0 (0–2)	0 (0–2)	0.542
Leukoaraiosis	744 (50.5)	745 (51.7)	0.737
Atrophy	1,131 (76.7)	1,114 (77.3)	0.521
Old stroke lesion	676 (45.9)	628 (43.6)	0.210

Abbreviations: ASPECTS = Alberta Stroke Program Early CT Score; IST-3 = Third International Stroke Trial; NIHSS = NIH Stroke Scale; OHS = Oxford Handicap Scale. Results are median (interquartile range) or n (%) as appropriate.

Acute lesion extent increased in 1,344/2,916 (46.1%) on the IST-3 Ischemic Lesion Score and 1,241/2,916 (42.6%) on ASPECTS among all patients. Although there were slightly fewer patients with lesion growth and more with a reduction in acute lesion extent between baseline and follow-up (on either IST-3 Ischemic Lesion Score or ASPECTS) among those allocated to alteplase vs those allocated to control, these changes were not significant in IST-3 (tables 2 and 3).

Swelling changed (mostly increased) between baseline and follow-up in 1,494/2,914 patients (51.3%) overall (table 2). However, there was no difference in the change in swelling from baseline to follow-up scanning between treatment groups (table 3).

On ordinal regression analysis, compared with control, patients allocated to alteplase were less likely to show an increase in acute lesion visibility grade between baseline and follow-up scans (OR = 0.77, 95% CI 0.67–0.89, $p < 0.001$) (table 4). Leukoaraiosis on baseline imaging independently predicted a less visible lesion on follow-up imaging (OR = 0.78, 95% CI 0.67–0.91, $p = 0.002$), but patients with leukoaraiosis were less likely to have a visible lesion both at baseline (562/1,489, 37.7% with leukoaraiosis vs 621/1,427, 43.5% without leukoaraiosis, $\chi^2 = 10.1$, $p = 0.002$) and follow-up (1,034/1,489, 69.4% with leukoaraiosis vs 1,090/1,427,

76.4% without, $\chi^2 = 17.7$, $p < 0.001$). The following independently predicted development of a more visible lesion at follow-up: higher NIHSS score at randomization (OR = 1.06, 95% CI 1.05–1.07, $p < 0.001$); the presence of an old stroke lesion at baseline (OR = 1.19, 95% CI 1.03–1.37, $p = 0.017$); or hemorrhage on follow-up imaging (OR = 1.62, 95% CI 1.34–1.96, $p < 0.001$). Our results did not change if patients with MRI (at either baseline or follow-up) were excluded: in those with CT at both time points, OR for the effect of treatment on change in lesion visibility grade = 0.76 (95% CI 0.66–0.88, $p < 0.001$, n = 2,731; full data not shown).

We found no evidence of an interaction between alteplase and prespecified subgroups on change in acute lesion visibility grade between baseline and follow-up (ordinal regression analysis): baseline stroke severity mild (NIHSS score <8) vs moderate-severe (NIHSS score ≥ 8) ($p = 0.842$); presence vs absence of leukoaraiosis, atrophy, or old stroke lesions ($p = 0.871$, $p = 0.358$, $p = 0.239$, respectively) (data available from Edinburgh DataShare, figure e-4, dx.doi.org/10.7488/ds/2367).

Effect of imaging appearances and clinical features on 6-month outcome in IST-3

On univariate analysis, the change in IST-3 Ischemic Lesion Score ($r = 0.21$, $p < 0.001$), ASPECTS ($r = -0.35$, $p < 0.001$), acute lesion visibility grade ($r = 0.22$, $p < 0.001$), and swelling

Table 2 Results of central expert panel assessment for the imaging variables assessed at baseline and follow-up (n = 2,916)

Imaging variable	Options	Baseline scan (2,861 CT, 55 MRI)	Follow-up scan (2,766 CT, 150 MRI)
Presence of an acute lesion (either change in tissue CT attenuation/T2-weighted intensity or swelling)		1,183 (40.6)	2,124 (72.8)
Visibility grade	0 = No attenuation/intensity change	1,754 (60.2)	797 (27.3)
	1 = Early tissue changes	974 (33.4)	204 (7.0)
	2 = Late tissue changes	188 (6.4)	1,915 (65.7)
Location of acute lesion	ACA territory	4/1,178 (0.3)	37/2,119 (1.7)
	MCA territory	1,088 (92.4)	1,722 (81.3)
	PCA territory	39 (3.3)	108 (5.1)
	Vertebrobasilar territory	18 (1.5)	59 (2.8)
	Borderzone	7 (0.6)	14 (0.7)
	Multiple arterial territories	22 (1.9)	179 (8.4)
ASPECTS	10	1,825 (62.6)	1,118 (38.3)
	9	174 (6.0)	232 (8.0)
	8	205 (7.0)	230 (7.9)
	7	180 (6.2)	265 (9.1)
	6	142 (4.9)	198 (6.8)
	5	98 (3.4)	176 (6.0)
	4	77 (2.6)	116 (4.0)
	3	78 (2.7)	132 (4.5)
	2	70 (2.4)	112 (3.8)
	1	32 (1.1)	134 (4.6)
	0	35 (1.2)	203 (7.0)
IST-3 ischemic lesion score	0 = No acute lesion	1,738 (59.6)	797 (27.3)
	1 = Small	194 (6.7)	432 (14.8)
	2 = Medium	485 (16.6)	723 (24.8)
	3 = Large	254 (8.7)	414 (14.2)
	4 = Very large	245 (8.4)	550 (18.9)
Degree of tissue swelling	None	2,241 (76.9)	1,244/2,914 (42.7)
	Effacement of sulci only	534 (18.3)	735 (25.2)
	Effacement of sulci and lateral ventricle (minor)	140 (4.8)	658 (22.6)
	Effacement of sulci and lateral ventricle (complete)	0	55 (1.9)
	Effacement of sulci, lateral and third ventricles	0	15 (0.5)
	Effacement of sulci, lateral and third ventricles plus midline shift	1 (0.03)	124 (4.3)
	Effacement sulci, lateral and third ventricles, midline shift plus effacement of basal cisterns	0	83 (2.8)
Any hemorrhage on follow-up imaging		—	479 (16.4)

Abbreviations: ACA = anterior cerebral artery; ASPECTS = Alberta Stroke Program Early CT Score; IST-3 = Third International Stroke Trial; MCA = middle cerebral artery; PCA = posterior cerebral artery. Results are n (%). Data for location of acute lesion and degree of tissue swelling were not available for all patients at both time points. Presence of hemorrhage was assessed only at follow-up.

Table 3 Univariate analyses comparing baseline to follow-up imaging progression between the alteplase vs control groups

Imaging variable	Imaging change between scans ^a	Alteplase group	Control group	<i>p</i> Value for difference between alteplase and control groups ^b
Lesion visibility grade (n = 2,916)	Less visible	46 (3.1)	41 (2.8)	0.007
	No change	492 (33.4)	430 (29.8)	
	More visible	936 (63.5)	971 (67.3)	
IST-3 ischemic lesion score (n = 2,916)	Smaller lesion	112 (7.6)	101 (7.0)	0.149
	No change	695 (47.2)	649 (45.0)	
	Larger lesion	667 (45.3)	692 (48.0)	
ASPECTS (n = 2,916)	Smaller lesion	141 (9.6)	134 (9.3)	0.768
	No change	639 (43.4)	602 (41.7)	
	Larger lesion	694 (47.1)	706 (49.0)	
Swelling (n = 2,914)	Less swelling	35 (2.4)	45 (3.1)	0.402
	No change	727 (49.3)	693 (48.1)	
	More swelling	712 (48.3)	702 (48.8)	

Abbreviations: ASPECTS = Alberta Stroke Program Early CT Score; IST-3 = Third International Stroke Trial.

Results represent n (%) within the alteplase and control groups.

^a Scalar data have been condensed for simplification in this table.

^b The *p* values are derived from noncondensed data.

($r = 0.40$, $p < 0.001$) between baseline and follow-up imaging were all associated with 6-month functional outcome such that a worsening of imaging appearances between baseline and 24–48 hours was associated with worse 6-month functional outcome.

On ordinal regression analysis, the following were independent predictors of poor outcome: greater age (OR = 0.97, $p < 0.001$); higher baseline NIHSS score (OR = 0.86, $p < 0.001$); leukoaraiosis (OR = 0.72, $p < 0.001$) or atrophy (OR = 0.77, $p = 0.013$) on baseline imaging; increasing acute

lesion extent (OR = 0.92, $p < 0.001$) or swelling (OR = 0.73, $p < 0.001$) between baseline and follow-up imaging; and hemorrhage on follow-up imaging (OR = 0.74, $p = 0.017$). Treatment with alteplase (OR = 1.36, $p < 0.001$) and increased time between baseline and follow-up imaging (OR = 1.10, $p = 0.009$) independently predicted better outcome at 6 months. Old stroke lesions and increasing visibility grade of the acute lesion between baseline and follow-up did not independently predict outcome (table 5). Results were similar if IST-3 Ischemic Lesion Score was used instead of ASPECTS to assess change in lesion extent (data not shown).

Table 4 Ordinal regression analysis of associations between change in lesion visibility grade between baseline and 24- to 48-hour follow-up (dependent variable) and potential clinical and imaging predictors

Change in lesion visibility grade (n = 2,916)	Source data	Odds ratio	95% CI	<i>p</i> Value
Increasing age, y	81 (72–86)	1.01	1.00–1.01	0.100
Increasing baseline NIHSS score	11 (6–17)	1.06	1.05–1.07	<0.001
Leukoaraiosis on baseline imaging	1,489 (51.1)	0.78	0.67–0.91	0.002
Atrophy on baseline imaging	2,245 (77.0)	0.84	0.69–1.02	0.073
Old stroke lesion(s) on baseline imaging	1,304 (44.7)	1.19	1.03–1.37	0.017
Increasing time from baseline to follow-up imaging (12-h groups)	26 (24–36)	1.05	0.99–1.12	0.111
Treatment with alteplase	1,474 (50.5)	0.77	0.67–0.89	<0.001
Any hemorrhage on follow-up imaging	479 (16.4)	1.62	1.34–1.96	<0.001

Abbreviations: CI = confidence interval; NIHSS = NIH Stroke Scale.

Source data summary provided as median (interquartile range) or n (%). Odds ratio >1 indicates a more visible lesion.

Meta-analysis

There have been no new randomized controlled trials of IV alteplase vs control since publication of the Cochrane review in 2014. The Cochrane review already contained a meta-analysis assessing the alteplase effect on symptomatic edema in 6 trials (including IST-3), which we did not repeat. Two of the trial datasets identified using Cochrane (ECASS [European Cooperative Acute Stroke Study], EPITHET [Echoplanar Imaging Thrombolytic Evaluation Trial])^{24,25} had examined lesion growth between baseline and follow-up similar to IST-3, while 3 of the trials (NINDS [National Institute of Neurological Disorders and Stroke], ATLANTIS [Alteplase Thrombolysis for Acute Noninterventive Therapy in Ischemic Stroke] A & B)^{26–28} had measured lesion volume on follow-up imaging alone (total n = 1,841).

On meta-analysis, we found that alteplase impeded lesion growth (OR = 0.87, 95% CI 0.76–0.99) and was associated with smaller lesion volumes on follow-up imaging (OR = 0.82, 95% CI 0.67–1.00). When combined in a single meta-analysis including nearly 5,000 patients from 6 trials (including IST-3), alteplase reduced progression in the extent of the ischemic lesion (increased lesion growth or greater lesion volume on follow-up imaging) (OR = 0.85, 95% CI 0.76–0.95, $p = 0.004$) (figure 2).

Discussion

In this large randomized trial with baseline and follow-up CT or MRI available for blinded central review in more than 97% of patients, we found that during the first 24 to 48 hours after the onset of ischemic stroke, patients allocated to alteplase

were less likely to show progression in the visibility of the acute lesion compared with controls. Remarkably, less than 50% of patients in both treatment arms showed any lesion growth. IV alteplase did not reduce significantly the extent of the acute lesion or alter the degree of lesion swelling in IST-3, although there were fewer patients with larger lesions and more patients with smaller or stable lesions at 24 to 48 hours who received alteplase than control. It seems likely that IST-3 was underpowered to detect this subtle change in lesion extent, but when IST-3 data were combined in a meta-analysis of 6 randomized controlled trials of alteplase including nearly 5,000 patients, we found that alteplase was associated with a significant reduction in progression of the ischemic lesion extent. This alteplase effect includes a reduction in lesion growth between baseline and follow-up and a smaller lesion volume at follow-up. We postulate that IV alteplase resulted in fewer patients either converting an area of reversible ischemia to infarction, or expanding their ischemic lesion into tissue that was unaffected at baseline—both effects result in less injured brain tissue and may explain the better functional outcome seen following treatment with alteplase.

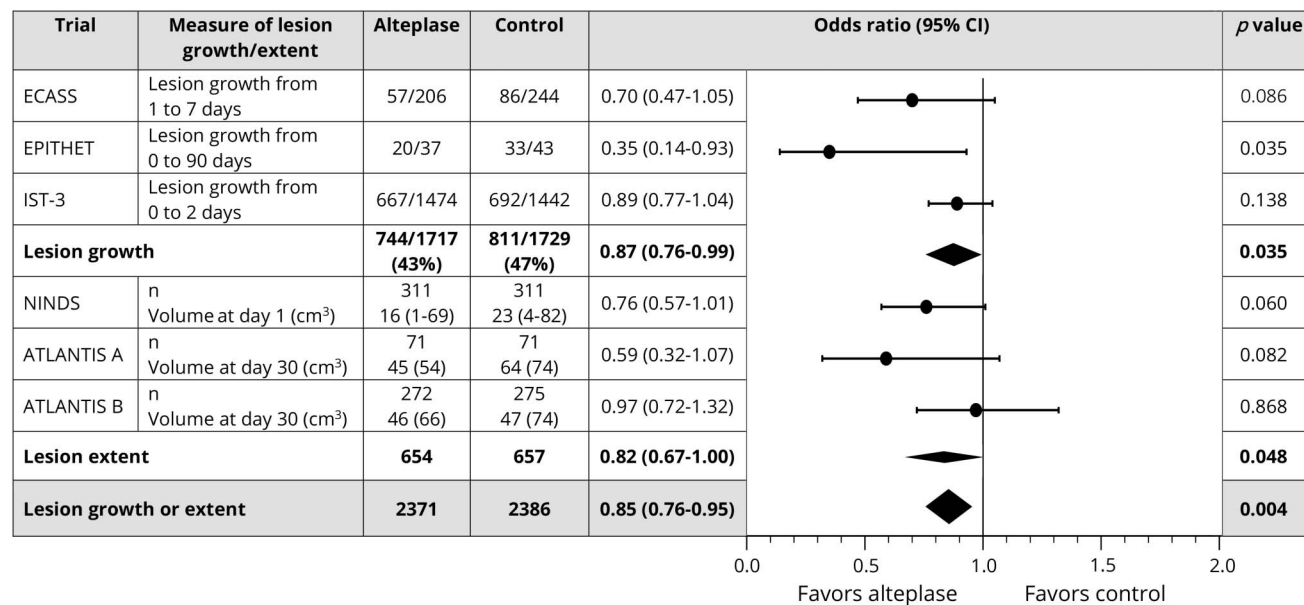
Background prestroke brain imaging features and baseline stroke severity were also independent predictors of change in acute lesion visibility from baseline to follow-up in IST-3. Patients with old infarcts were more likely to have increased acute lesion visibility at 24 to 48 hours. Perhaps individuals with prior infarcts are more likely to develop tissue injury if they experience another stroke than are patients without old infarcts on imaging, as suggested for lesion visibility on MRI in patients with minor stroke.²⁹ Harder to explain is the finding that prestroke leukoaraiosis appeared to reduce progression of

Table 5 Ordinal regression analysis of 6-month functional outcome (dependent variable) and potential predictors: Clinical and imaging characteristics (change in the acute lesion from baseline to 24- to 48-hour follow-up; prestroke features)

OHS grade at 6 mo (n = 2,916)	Source data	Odds ratio	95% CI	p Value
Increasing age, y	81 (72–86)	0.97	0.96–0.98	<0.001
Increasing baseline NIHSS score	11 (6–17)	0.86	0.85–0.87	<0.001
Leukoaraiosis on baseline imaging	1,488 (51.1)	0.72	0.60–0.85	<0.001
Atrophy on baseline imaging	2,243 (77.0)	0.77	0.62–0.95	0.013
Old stroke lesion(s) on baseline imaging	1,304 (44.7)	0.92	0.78–1.07	0.277
Increased lesion visibility grade from baseline to follow-up imaging	1,906 (65.4)	0.97	0.88–1.07	0.525
Worsening ASPECTS (more extensive lesion) from baseline to follow-up imaging	1,399 (48.0)	0.92	0.88–0.96	<0.001
Increased extent of tissue swelling from baseline to follow-up imaging	1,414 (48.5)	0.73	0.66–0.79	<0.001
Increasing time from baseline to follow-up imaging (12-h groups)	26 (24–36)	1.10	1.02–1.18	0.009
Treatment with alteplase	1,474 (50.6)	1.36	1.17–1.58	<0.001
Any hemorrhage on follow-up imaging	479 (16.4)	0.74	0.57–0.95	0.017

Abbreviations: ASPECTS = Alberta Stroke Program Early CT Score; CI = confidence interval; NIHSS = NIH Stroke Scale; OHS = Oxford Handicap Scale. Source data provided as median (interquartile range) or n (%). Odds ratio >1 indicates an increased likelihood of a better outcome.

Figure 2 Meta-analysis of data from randomized controlled trials of alteplase that assessed short-term lesion growth or lesion extent on follow-up imaging



For all studies in the combined analysis, $I^2 = 31.5\%$. ATLANTIS = Alteplase Thrombolysis for Acute Noninterventional Therapy in Ischemic Stroke; CI = confidence interval; ECASS = European Cooperative Acute Stroke Study; EPITHET = Echoplanar Imaging Thrombolytic Evaluation Trial; IST-3 = Third International Stroke Trial; NINDS = National Institute of Neurological Disorders and Stroke.

acute lesion visibility at follow-up. This may be because acute lesions were less often seen in patients with chronically abnormal white matter at baseline, a discrepancy that increased on follow-up imaging, but the reason for this is unclear.

Increased stroke severity (NIHSS) at baseline was a powerful independent predictor for increased lesion visibility on follow-up imaging in IST-3 in keeping with current and previously demonstrated associations between NIHSS, other imaging measures of severity (hyperattenuated arteries, arterial occlusion on angiography, acute lesion extent), and outcome after ischemic stroke.^{10,11,30} However, we found no evidence of an interaction between alteplase and severe vs mild stroke or presence/absence of prestroke features on change in acute lesion visibility; i.e., alteplase worked equally well across all of these subgroups.

Worsening of imaging appearances from baseline to 24–48 hours independently predicted poor outcome at 6 months in IST-3. Specifically, greater change in acute lesion extent on ASPECTS and increased tissue swelling were both associated with poor outcome. In addition, increased time from baseline to follow-up imaging was associated with better functional outcome, perhaps because of residual confounding with milder strokes being reimaged later. However, despite a significant univariate correlation between greater lesion visibility from baseline to 24- to 48-hour follow-up imaging and functional outcome, changes in lesion visibility did not independently predict outcome. This may reflect that increased lesion visibility in patients at follow-up in our analysis may

include new infarcts appearing since baseline imaging (likely to affect functional outcome) and early infarcts at baseline becoming more visible secondary to the expected short-term tissue changes of infarct (less likely to affect functional outcome). Whether the transition from ischemic to infarcted brain can be reliably differentiated using unenhanced CT or basic MRI sequences remains unproven.

Lack of an association between alteplase and change in the degree of swelling at 24- to 48-hour follow-up appears to contrast with the significant excess of symptomatic brain swelling (that is, severe swelling on follow-up imaging plus neurologic deterioration within 7 days) among alteplase-treated patients in the primary IST-3 report.¹² However, the current analysis examined all grades of swelling rather than only symptomatic swelling, and as noted above, progressive swelling was associated with worse functional outcome at 6 months.

The limitations of IST-3 have been discussed previously,¹² chiefly the potential for bias because of the open trial design; however, for the present analyses, all readers were masked to clinical data and treatment allocation. In IST-3, investigators were required to perform follow-up imaging between 24 and 48 hours unless the patient deteriorated clinically, in which case immediate rescanning was required; patients who deteriorated and hence were scanned sooner were more likely to have poor 6-month outcomes. Patients treated with alteplase underwent follow-up imaging marginally sooner than controls but had better outcomes overall. It is likely that this marginal difference in scan interval may reflect the open design and the

less-pressing need to reimage patients known to have been allocated to the control group. Although almost all patients had CT imaging at baseline and follow-up, a few patients were scanned with different modalities at the 2 time points. It may not be appropriate to compare acute lesion extent and visibility between CT and MRI, though it is perhaps reasonable to assume that classification of swelling would not differ between modalities. However, the results remained the same when those with MRI were excluded from the analysis assessing change in lesion visibility; we have therefore left all patients in for completeness. Validated quantitative computational methods for the assessment of brain imaging are not yet available for all of the characteristics we assessed in IST-3. Most important, computational lesion volume measurement does not distinguish between an increase in volume due to a true change in lesion extent and an increase in volume due to more swelling in a lesion of the same extent. We and others are developing computational lesion assessment methods,³¹ but their superiority over human visual rating remains unproven. Finally, angiographic imaging at baseline and follow-up was not available. We are aware that we do not know whether and to what extent treatment with alteplase was associated with arterial recanalization, and tissue reperfusion. The strengths of IST-3 include its large sample size, the inclusion of patients with a wide range of clinical characteristics and baseline imaging appearances, and central masked review of all imaging and visual scoring methods that had undergone extensive independent validation.^{16,17}

We provide robust evidence that in ischemic stroke, allocation to alteplase was associated with less progression in the extent (based on the totality of the randomized evidence from the meta-analysis) and visibility (in IST-3 alone) of the acute lesion on short-term imaging follow-up. These findings may reflect less tissue damage among patients treated with alteplase and help explain how alteplase improves functional outcome after ischemic stroke. Alteplase did not alter the development of lesion swelling, but progression of lesion extent and swelling were both associated with poorer clinical outcome at 6 months. Imaging biomarkers of the effect of alteplase on ischemic brain will be valuable for clinical practice and research. Our findings indicate that early changes in the ischemic brain lesion are measurable on imaging, that these imaging appearances can predict outcome, and that treatment with alteplase limits progression of the ischemic lesion, which may in turn act as a surrogate for an improved functional outcome.

Author contributions

Dr. Mair contributed to the design of this work, analyzed and interpreted the data, and drafted the manuscript. Prof. von Kummer contributed to the design of this work, to data collection and interpretation, and critically revised the manuscript. Dr. Morris contributed to data collection and critically revised the manuscript. Dr. von Heijne contributed to data collection and critically revised the manuscript. Dr. Bradey contributed to data collection and critically revised the manuscript. Prof. Cala contributed to data collection and critically revised the

manuscript. Dr. Peeters contributed to data collection and critically revised the manuscript. Prof. Farrall contributed to data collection and critically revised the manuscript. Dr. Adami contributed to data collection and critically revised the manuscript. Dr. Potter contributed to data collection and critically revised the manuscript. Prof. Sandercock contributed to the design of this work, to data collection and interpretation, and critically revised the manuscript. Prof. Lindley contributed to the design of this work, to data interpretation, and critically revised the manuscript. Prof. Wardlaw helped design IST-3, designed and supervised the IST-3 imaging data collection, coordinated the image reading panel, managed all IST-3 imaging analysis, data processing and supervised the statistical analysis, and drafted and critically revised the manuscript.

Study funding

IST-3 was funded from a large number of sources (data available from Edinburgh DataShare, eAppendix, dx.doi.org/10.7488/ds/2367) but chiefly the UK Medical Research Council (MRC G0400069 and EME 09-800-15) and the UK Stroke Association.

Disclosure

G. Mair reports no disclosures relevant to the manuscript. R. von Kummer is editor-in-chief of *Neuroradiology*, served on the data monitoring and safety committees for Impact-24, ReSPECT ESUS, ReSPECT CVT, ECASS 4, SWIFT DIRECT and bills BrainsGate, Applied Clinical Intelligence, LLC, and Parexel for his time spent on these studies. He is adjudicating the images of SITS Open and bills Karolinska Institutet per case. Z. Morris, A. von Heijne, N. Bradey, and L. Cala report no disclosures relevant to the manuscript. A. Peeters: Boehringer Ingelheim. A. Farrall, A. Adami, and G. Potter report no disclosures relevant to the manuscript. P. Sandercock was the chief investigator of the IST-3 trial, which received a donation of drug and placebo for 300 patients in the IST-3 pilot study. Prof. Sandercock has received lecture fees (paid to his department) from Boehringer Ingelheim. R. Lindley: Boehringer Ingelheim, Covidien. J. Wardlaw received research funding from the Medical Research Council, Efficacy and Mechanisms Evaluation, Stroke Association, Health Foundation, and Chest Heart & Stroke Scotland for this work. Prof. Wardlaw was imaging chief investigator for IST-3, which received a donation of drug and placebo for the first 300 patients in IST-3 from Boehringer Ingelheim and initial setup of the image management system from DesAcc. Prof. Wardlaw also receives funding from the EU H2020 SVDs@Target and Fondation Leducq. Go to Neurology.org/N for full disclosures.

Publication history

Received by *Neurology* March 12, 2018. Accepted in final form August 14, 2018.

References

1. Simard JM, Kent TA, Chen M, Tarasov KV, Gerzanich V. Brain oedema in focal ischaemia: molecular pathophysiology and theoretical implications. *Lancet Neurol* 2007;6:258–268.

2. Dzialowski I, Weber J, Doerfler A, Forsting M, von Kummer R. Brain tissue water uptake after middle cerebral artery occlusion assessed with CT. *J Neuroimaging* 2004;14:42–48.
3. Wardlaw JM, Mielke O. Early signs of brain infarction at CT: observer reliability and outcome after thrombolytic treatment—systematic review. *Radiology* 2005;235:444–453.
4. Wardlaw JM, Sandercock PAG, Lindley RI, et al. Association between brain imaging signs, early and late outcomes, and response to intravenous alteplase after acute ischaemic stroke in the Third International Stroke Trial (IST-3): secondary analysis of a randomised controlled trial. *Lancet Neurol* 2015;14:485–496.
5. Dzialowski I, Klotz E, Goericke S, Doerfler A, Forsting M, von Kummer R. Ischemic brain tissue water content: CT monitoring during middle cerebral artery occlusion and reperfusion in rats. *Radiology* 2007;243:720–726.
6. von Kummer R, Dzialowski I. Imaging of cerebral ischemic edema and neuronal death. *Neuroradiology* 2017;59:545–553.
7. Moseley ME, Kucharczyk J, Mintorovitch J, Cohen Y, Kurhanewicz J, Derugin N. Diffusion-weighted MR imaging of acute stroke: correlation with T2-weighted and magnetic susceptibility-enhanced MR imaging in cats. *AJNR Am J Neuroradiol* 1990;11:423–429.
8. Thomalla G, Cheng B, Ebinger M, et al. DWI-FLAIR mismatch for the identification of patients with acute ischaemic stroke within 4.5 h of symptom onset (PRE-FLAIR): a multicentre observational study. *Lancet Neurol* 2011;10:978–986.
9. Emberson J, Lees KR, Lyden P, et al. Effect of treatment delay, age, and stroke severity on the effects of intravenous thrombolysis with alteplase for acute ischaemic stroke: a meta-analysis of individual patient data from randomised trials. *Lancet* 2014;384:1929–1935.
10. Mair G, von Kummer R, Morris Z, et al. Effect of alteplase on the CT hyperdense artery sign and outcome after ischemic stroke. *Neurology* 2016;86:118–125.
11. Mair G, von Kummer R, Adami A, et al. Arterial obstruction on computed tomographic or magnetic resonance angiography and response to intravenous thrombolitics in ischemic stroke. *Stroke* 2017;48:353–360.
12. IST-3 Collaborative Group. The benefits and harms of intravenous thrombolysis with recombinant tissue plasminogen activator within 6 h of acute ischaemic stroke (the Third International Stroke Trial [IST-3]): a randomised controlled trial. *Lancet* 2012;379:2352–2363.
13. Sandercock P, Lindley R, Wardlaw J, et al. Third International Stroke Trial (IST-3) of thrombolysis for acute ischaemic stroke. *Trials* 2008;9:37.
14. Bamford J, Sandercock P, Dennis M, Burn J, Warlow C. A prospective study of acute cerebrovascular disease in the community: the Oxfordshire Community Stroke Project—1981–86. 2. Incidence, case fatality rates and overall outcome at one year of cerebral infarction, primary intracerebral and subarachnoid haemorrhage. *J Neurol Neurosurg Psychiatry* 1990;53:16–22.
15. Whiteley W, Lindley R, Wardlaw J, Sandercock P. Third International Stroke Trial. *Int J Stroke* 2006;1:172–176.
16. Wardlaw JM, Farrall AJ, Perry D, et al. Factors influencing the detection of early computed tomography signs of cerebral ischemia: an internet-based, international multiobserver study. *Stroke* 2007;38:1250–1256.
17. Wardlaw JM, von Kummer R, Farrall AJ, Chappell FM, Hill M, Perry D. A large web-based observer reliability study of early ischaemic signs on computed tomography. The Acute Cerebral CT Evaluation of Stroke Study (ACCESS). *PLoS One* 2010;5:e15757.
18. Wardlaw JM, Sellar RJ. A simple practical classification of cerebral infarcts on CT and its interobserver reliability. *AJNR Am J Neuroradiol* 1994;15:1933–1939.
19. Barber PA, Demchuk AM, Zhang J, Buchan AM. Validity and reliability of a quantitative computed tomography score in predicting outcome of hyperacute stroke before thrombolytic therapy. ASPECTS Study Group. Alberta Stroke Programme Early CT Score. *Lancet* 2000;355:1670–1674.
20. Fazekas F, Chawluk JB, Alavi A, Hurtig HI, Zimmerman RA. MR signal abnormalities at 1.5T in Alzheimer's dementia and normal aging. *AJR Am J Roentgenol* 1987;149:351–356.
21. van Swieten JC, Hijdra A, Koudstaal PJ, van Gijn J. Grading white matter lesions on CT and MRI: a simple scale. *J Neurol Neurosurg Psychiatry* 1990;53:1080–1083.
22. Farrell C, Chappell F, Armitage PA, et al. Development and initial testing of normal reference MR images for the brain at ages 65–70 and 75–80 years. *Eur Radiol* 2008;19:177–183.
23. Wardlaw JM, Murray V, Berge E, del Zoppo GJ. Thrombolysis for acute ischaemic stroke. *Cochrane Database Syst Rev* 2014;7:CD000213.
24. Pantano P, Caramia F, Bozzao L, Dieler C, von Kummer R. Delayed increase in infarct volume after cerebral ischemia: correlations with thrombolytic treatment and clinical outcome. *Stroke* 1999;30:502–507.
25. Davis SM, Donnan G, Parsons MW, et al. Effects of alteplase beyond 3 h after stroke in the Echoplanar Imaging Thrombolytic Evaluation Trial (EPITHET): a placebo-controlled randomised trial. *Lancet Neurol* 2008;7:299–309.
26. Clark WM, Albers GW, Madden KP, Hamilton S. The rtPA (alteplase) 0- to 6-hour acute stroke trial, part A (A0276g): results of a double-blind, placebo-controlled, multicenter study. Thrombolytic Therapy in Acute Ischemic Stroke Study investigators. *Stroke* 2000;31:811–816.
27. Clark WM, Wissman S, Albers GW, Jhamandas JH, Madden KP, Hamilton S. Recombinant tissue-type plasminogen activator (alteplase) for ischemic stroke 3 to 5 hours after symptom onset. The ATLANTIS Study: a randomized controlled trial. Alteplase Thrombolysis for Acute Noninterventional Therapy in Ischemic Stroke. *JAMA* 1999;282:2019–2026.
28. The National Institute of Neurological Disorders and Stroke (NINDS) rt-PA Stroke Study Group. Effect of intravenous recombinant tissue plasminogen activator on ischemic stroke lesion size measured by computed tomography. *Stroke* 2000;31:2912–2919.
29. Makin SD, Doubal FN, Dennis MS, Wardlaw JM. Clinically confirmed stroke with negative diffusion-weighted imaging magnetic resonance imaging: longitudinal study of clinical outcomes, stroke recurrence, and systematic review. *Stroke* 2015;46:3142–3148.
30. Schaefer PW, Pulli B, Copen WA, et al. Combining MRI with NIHSS thresholds to predict outcome in acute ischemic stroke: value for patient selection. *AJNR Am J Neuroradiol* 2015;36:259–264.
31. Chen L, Carlton Jones AL, Mair G, et al. Rapid automated quantification of cerebral leukoaraiosis on CT images: a multicenter validation study. *Radiology* 2018;288:573–581.

Neurology®

Effect of IV alteplase on the ischemic brain lesion at 24–48 hours after ischemic stroke

Grant Mair, Rüdiger von Kummer, Zoe Morris, et al.

Neurology published online October 26, 2018

DOI 10.1212/WNL.0000000000006575

This information is current as of October 26, 2018

Updated Information & Services	including high resolution figures, can be found at: http://n.neurology.org/content/early/2018/10/26/WNL.0000000000006575.full
Subspecialty Collections	This article, along with others on similar topics, appears in the following collection(s): Clinical trials Randomized controlled (CONSORT agreement) http://n.neurology.org/cgi/collection/clinical_trials_randomized_controlled_consort_agreement CT http://n.neurology.org/cgi/collection/ct Infarction http://n.neurology.org/cgi/collection/infarction MRI http://n.neurology.org/cgi/collection/mri
Permissions & Licensing	Information about reproducing this article in parts (figures, tables) or in its entirety can be found online at: http://www.neurology.org/about/about_the_journal#permissions
Reprints	Information about ordering reprints can be found online: http://n.neurology.org/subscribers/advertise

Neurology® is the official journal of the American Academy of Neurology. Published continuously since 1951, it is now a weekly with 48 issues per year. Copyright © 2018 The Author(s). Published by Wolters Kluwer Health, Inc. on behalf of the American Academy of Neurology. All rights reserved. Print ISSN: 0028-3878. Online ISSN: 1526-632X.

