



THE UNIVERSITY *of* EDINBURGH

Edinburgh Research Explorer

## Thrombotic microangiopathy associated with interferon beta

**Citation for published version:**

Hunt, D, Kavanagh, D, Drummond, I, Weller, B, Overell, J, Bellamy, C, Evans, S, Jackson, A & Chandran, S 2014, 'Thrombotic microangiopathy associated with interferon beta', *New England Journal of Medicine*, vol. 370, no. 13, pp. 1270-1. <https://doi.org/10.1056/NEJMc1316118>

**Digital Object Identifier (DOI):**

[10.1056/NEJMc1316118](https://doi.org/10.1056/NEJMc1316118)

**Link:**

[Link to publication record in Edinburgh Research Explorer](#)

**Document Version:**

Peer reviewed version

**Published In:**

New England Journal of Medicine

**General rights**

Copyright for the publications made accessible via the Edinburgh Research Explorer is retained by the author(s) and / or other copyright owners and it is a condition of accessing these publications that users recognise and abide by the legal requirements associated with these rights.

**Take down policy**

The University of Edinburgh has made every reasonable effort to ensure that Edinburgh Research Explorer content complies with UK legislation. If you believe that the public display of this file breaches copyright please contact [openaccess@ed.ac.uk](mailto:openaccess@ed.ac.uk) providing details, and we will remove access to the work immediately and investigate your claim.



Published in final edited form as:

*N Engl J Med.* 2014 March 27; 370(13): 1270–1271. doi:10.1056/NEJMc1316118.

## Thrombotic Microangiopathy Associated with Interferon Beta

**David Hunt, Ph.D.** and

Edinburgh University Edinburgh, United Kingdom

**David Kavanagh, M.D., Ph.D.**

Newcastle University Newcastle upon Tyne, United Kingdom

**Iain Drummond, M.B., Ch.B., Belinda Weller, M.B., B.S., and Chris Bellamy, Ph.D.**

Edinburgh University Edinburgh, United Kingdom

**James Overell, M.D.** and

Glasgow University Glasgow, United Kingdom

**Stephen Evans, M.Sc.**

London School of Hygiene and Tropical Medicine London, United Kingdom

**Andrew Jackson, Ph.D.** and **Siddharthan Chandran, Ph.D.**

University of Edinburgh Edinburgh, United Kingdom

---

**To the Editor:** Interferon beta is a widely prescribed recombinant-protein therapy with a well-established favorable safety profile.<sup>1</sup> Here, we describe an unexpectedly high number of cases of thrombotic microangiopathy associated with severe or malignant hypertension in four patients with multiple sclerosis who were receiving therapy with recombinant interferon beta in South Scotland. A detailed review of the case histories of these patients, including a genetic analysis, did not identify any other causal factor for this condition, and an analysis of pharmacy records revealed a significant association with a common manufacturing source of interferon beta (Rebif, Merck) (Fig. 1, and the Supplementary Appendix, available with the full text of this letter at [NEJM.org](http://NEJM.org)).

The regulatory authorities in the United Kingdom received six additional spontaneous reports of disorders related to thrombotic microangiopathy and interferon beta, all associated with the same manufacturer (for details, see the Supplementary Appendix). In December 2013, the Medicines and Healthcare Products Regulatory Agency (MHRA) issued a drug-safety update regarding a possible link between interferon beta and thrombotic microangiopathy.<sup>2</sup> In April 2009, the manufacturer of Rebif added a warning to the package insert about a possible association with thrombotic microangiopathy, which was specifically defined as the hemolytic–uremic syndrome and thrombotic thrombocytopenic purpura (HUS/TTP).

---

Correspondence Copyright © 2014 Massachusetts Medical Society.

siddharthan.chandran@ed.ac.uk.

Disclosure forms provided by the authors are available with the full text of this letter at [NEJM.org](http://NEJM.org).

We requested details regarding the geographical and temporal distribution of the HUS/TTP reports. Consistent with our observations in the United Kingdom, very few cases were reported globally in the first 9 years of safety monitoring. However, there has been a recent increase in reports from countries that share the same formulation as that used in the United Kingdom.<sup>3</sup> Substantial caution is required in the interpretation of spontaneous reports of adverse drug reactions, since such reports are voluntary, are potentially subject to underreporting, and may be influenced by many factors, including the severity of the drug reaction, the diagnostic classification, and the degree of publicity. However, we did not detect such patterns or trends in the safety data from a similar recombinant interferon beta product, suggesting that further investigation of the association with changes in manufacturing may be worthwhile. We have raised these concerns with the manufacturer and regulatory authorities.

The patients in our analysis share important clinical features (for details, see the Supplementary Appendix). First, all the patients presented after years of well-tolerated treatment with inter-feron beta, making an association difficult to recognize. Second, fulminant presentation was associated with severe hypertension. Third, despite the emergency presentation, retrospective review identified chronic changes in all renal-biopsy specimens and a prodrome in three of the four patients with features that included newly diagnosed hypertension, hematologic abnormalities, and renal impairment in the months before diagnosis. We subsequently identified a similar prodrome in a recent fatal case in the United Kingdom. Thrombotic microangiopathy is therefore a serious and potentially fatal complication that has emerged late in the lifetime of recombinant inter-feron beta therapy. Early manifestations of this complication may be recognizable with increased vigilance, with the potential to mitigate severity.

## Supplementary Material

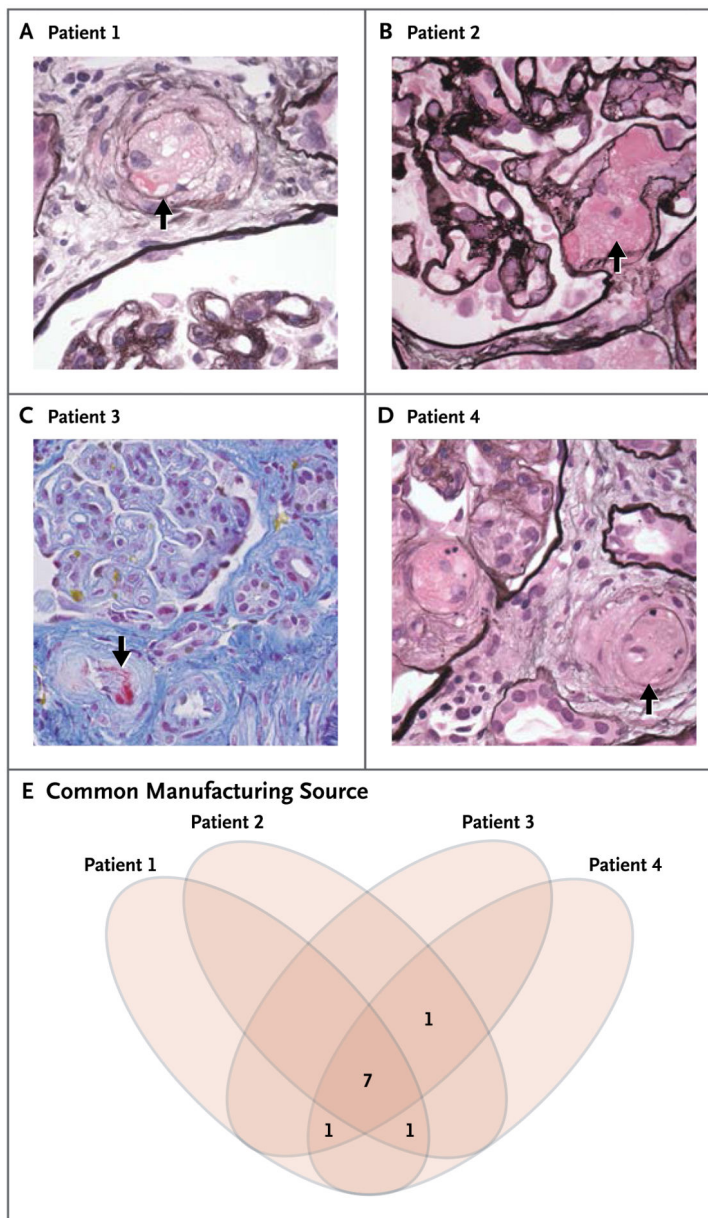
Refer to Web version on PubMed Central for supplementary material.

## Acknowledgments

Supported by the Scottish Higher Education Funding Council and by grants from the Wellcome Trust and the Academy of Medical Sciences (to Drs. Hunt and Kavanagh) and from the Medical Research Council (to Dr. Jackson).

## References

1. PRISMS (Prevention of Relapses and Disability by Interferon beta-1a Subcutaneously in Multiple Sclerosis) Study Group. Randomised double-blind placebo-controlled study of interferon beta-1a in relapsing/remitting multiple sclerosis. *Lancet*. 1998; 352:1498–504. [PubMed: 9820297] *Lancet*. 1999; 353:678. Erratum.
2. Recombinant interferon-beta: thrombotic microangiopathy. [December 2013] Drug Safety Update. p. S3 <http://www.mhra.gov.uk/Safetyinformation/DrugSafetyUpdate/CON355481>
3. Giovannoni G, Barbarash O, Casset-Semanaz F, et al. Safety and immunogenicity of a new formulation of interferon beta-1a (Rebif New Formulation) in a Phase IIIb study in patients with relapsing multiple sclerosis: 96-week results. *Mult Scler*. 2009; 15:219–28. [PubMed: 18755819]



**Figure 1. Cases of Thrombotic Microangiopathy Associated with a Common Manufacturing Source of Interferon Beta**

Shown are renal-biopsy specimens obtained from four patients receiving recombinant interferon beta therapy in South Scotland in whom thrombotic micro-angiopathy was diagnosed during an 18-month period (Panels A through D). All four specimens show arteriolar luminal obliteration with swollen endothelium and fibrin (arrows; hematoxylin and eosin and silver staining [Panels A, B, and D] and Martius scarlet blue [MSB] staining [Panel C]). All four patients were treated with recombinant interferon beta from the same manufacturer, as confirmed by tracing of drug batches. The Venn diagram shows the overlap of 10 batches prescribed to patients in the year before the presentation of the index case (Panel E).