



THE UNIVERSITY *of* EDINBURGH

## Edinburgh Research Explorer

# TG18 management strategies for gallbladder drainage in patients with acute cholecystitis: Updated Tokyo Guidelines 2018 (with videos)

### Citation for published version:

Mori, Y, Itoi, T, Baron, TH, Takada, T, Strasberg, SM, Pitt, HA, Ukai, T, Shikata, S, Noguchi, Y, Teoh, AYB, Kim, M, Asbun, HJ, Endo, I, Yokoe, M, Miura, F, Okamoto, K, Suzuki, K, Umezawa, A, Iwashita, Y, Hibi, T, Wakabayashi, G, Han, H, Yoon, Y, Choi, I, Hwang, T, Chen, M, Garden, OJ, Singh, H, Liau, K, Huang, WS, Gouma, DJ, Belli, G, Dervenis, C, De Santibañes, E, Giménez, ME, Windsor, JA, Lau, WY, Cherqui, D, Jagannath, P, Supe, AN, Liu, K, Su, C, Deziel, DJ, Chen, X, Fan, ST, Ker, C, Jonas, EC, Padbury, R, Mukai, S, Honda, G, Sugioka, A, Asai, K, Higuchi, R, Wada, K, Yoshida, M, Mayumi, T, Hirata, K, Sumiyama, Y, Inui, K & Yamamoto, M 2018, 'TG18 management strategies for gallbladder drainage in patients with acute cholecystitis: Updated Tokyo Guidelines 2018 (with videos)', *Journal of Hepato-Biliary-Pancreatic Sciences*, vol. 25, no. 1. <https://doi.org/10.1002/jhbp.504>

### Digital Object Identifier (DOI):

[10.1002/jhbp.504](https://doi.org/10.1002/jhbp.504)

### Link:

[Link to publication record in Edinburgh Research Explorer](#)

### Document Version:

Peer reviewed version

### Published In:

Journal of Hepato-Biliary-Pancreatic Sciences

### General rights

Copyright for the publications made accessible via the Edinburgh Research Explorer is retained by the author(s) and / or other copyright owners and it is a condition of accessing these publications that users recognise and abide by the legal requirements associated with these rights.

### Take down policy

The University of Edinburgh has made every reasonable effort to ensure that Edinburgh Research Explorer content complies with UK legislation. If you believe that the public display of this file breaches copyright please contact [openaccess@ed.ac.uk](mailto:openaccess@ed.ac.uk) providing details, and we will remove access to the work immediately and investigate your claim.



Guideline

**TG18 management strategies for gallbladder drainage in patients with acute  
cholecystitis: Updated Tokyo Guidelines 2018 (with videos)**

Yasuhisa Mori, Takao Itoi, Todd H. Baron, Tadahiro Takada, Steven M. Strasberg,  
Henry A. Pitt, Tomohiko Ukai, Satoru Shikata, Yoshinori Noguchi, Anthony Yuen  
Bun Teoh, Myung-Hwan Kim, Horacio J. Asbun, Itaru Endo, Masamichi Yokoe,  
Fumihiko Miura, Kohji Okamoto, Kenji Suzuki, Akiko Umezawa, Yukio Iwashita,  
Taizo Hibi, Go Wakabayashi, Ho-Seong Han, Yoo-Seok Yoon, In-Seok Choi,  
Tsann-Long Hwang, Miin-Fu Chen, O James Garden, Harjit Singh, Kui-Hin Liau,  
Wayne Shih-Wei Huang, Dirk Joan Gouma, Giulio Belli, Christos Dervenis, Eduardo  
de Santibañes, Mariano Eduardo Giménez, John Albert Windsor, Wan Yee Lau, Daniel  
Cherqui, Palepu Jagannath, Avinash Nivritti Supe, Keng-Hao Liu, Cheng-Hsi Su,  
Daniel J. Deziel, Xiao-Ping Chen, Sheung Tat Fan, Chen-Guo Ker, Eduard C. Jonas,  
Robert Padbury, Shuntaro Mukai, Goro Honda, Atsushi Sugioka, Koji Asai, Ryota  
Higuchi, Keita Wada, Masahiro Yoshida, Toshihiko Mayumi, Koichi Hirata,  
Yoshinobu Sumiyama, Kazuo Inui, Masakazu Yamamoto

The author's affiliations are listed in the Appendix.

This article has been accepted for publication and undergone full peer review but has not  
been through the copyediting, typesetting, pagination and proofreading process, which may  
lead to differences between this version and the Version of Record. Please cite this article as  
doi: 10.1002/jhbp.504

This article is protected by copyright. All rights reserved.

**Correspondence to:**

Tadahiro Takada, MD, PhD, Department of Surgery, Teikyo University School of Medicine, 2-11-1 Kaga, Itabashi-ku, Tokyo 173-8605, Japan. E-mail:

t-takada@jshbps.jp

**Keywords:** Acute cholecystitis, Gallbladder drainage, Percutaneous transhepatic gallbladder drainage (PTGBD), Endoscopic transpapillary gallbladder drainage (ETGBD), endoscopic ultrasound-guided gallbladder drainage (EUS-GBD)

**ABSTRACT**

Since the publication of the Tokyo Guidelines in 2007 and their revision in 2013, appropriate management for acute cholecystitis has been more clearly established. Since the last revision, several manuscripts, especially for alternative endoscopic techniques, have been reported; therefore, additional evaluation and refinement of the 2013 Guidelines is required. We describe a standard drainage method for surgically high-risk patients with acute cholecystitis and the latest developed endoscopic gallbladder drainage techniques described in the updated Tokyo Guidelines 2018 (TG18). Our study confirmed that percutaneous transhepatic gallbladder drainage should be considered the first alternative to surgical intervention in surgically high-risk patients with acute cholecystitis. Also, endoscopic transpapillary gallbladder drainage

This article is protected by copyright. All rights reserved.

or endoscopic ultrasound-guided gallbladder drainage can be considered in high-volume institutes by skilled endoscopists. In the endoscopic transpapillary approach, either endoscopic naso-gallbladder drainage or gallbladder stenting can be considered for gallbladder drainage. We also introduce special techniques and the latest outcomes of endoscopic ultrasound-guided gallbladder drainage studies.

## INTRODUCTION

Although standard treatment for patients with acute cholecystitis (AC) is well established based on the 2007 Tokyo Guidelines (TG07)(1), revised in Tokyo Guidelines 2013 (TG13)(2), morbidity and mortality rates in patients at high risk for surgery with comorbid medical conditions remain high (3-9). In TG07, the detailed procedure of percutaneous transhepatic gallbladder drainage (PTGBD) was introduced, while the recommendation of PTGBD for AC was not established. Since then, TG13 stated that PTGBD should be recommended as the first alternative to cholecystectomy in such patients (2). However, some studies have evaluated the usefulness of percutaneous transhepatic gallbladder aspiration (PTGBA) without catheter placement as a simple decompression method (10, 11). Another alternative procedure is endoscopic gallbladder drainage, which can be performed using either a transpapillary or transmural approach. The former method is endoscopic transpapillary gallbladder drainage (ETGBD) including endoscopic naso-gallbladder drainage (ENGBD) and gallbladder stenting (EGBS) under endoscopic retrograde cholangiopancreatography

(ERCP), through which the gallbladder is drained via the cystic duct with a nasobiliary tube or stent across the papilla. This procedure appears to be especially suitable for patients with severe coagulopathy, thrombocytopenia, or an anatomically inaccessible location. More recently, endoscopic ultrasound-guided gallbladder drainage (EUS-GBD) has been reported to be useful as an alternative gallbladder drainage procedure in patients with AC. TG13 proposed that these endoscopic approaches provide suboptimal drainage because they have not been fully evaluated. Since the introduction of TG13, several studies describing alternative endoscopic techniques have been published; therefore, additional evaluation and refinement of TG13 is required. We describe a standard drainage method for surgically high-risk patients with AC, and the latest developed endoscopic gallbladder drainage techniques. We also discuss the recommendation grades for the procedures, (12, 13) established by the updated 2018 Tokyo Guidelines (TG18).

### **Methods of systematic review and meta-analysis**

In the updated TG, we performed systematic reviews and meta-analyses related to each discussion point for gallbladder drainage, where possible, and described the results based on the PRISMA statement. We systematically searched MEDLINE (PubMed), the Cochrane Library, and Japan Medical Abstracts (the largest database of Japanese articles) for studies describing each discussion point for gallbladder drainage. In MEDLINE, we combined the Centre for Reviews and Dissemination/Cochrane

Highly Sensitive Search Strategy with the Medical Subject Heading (MeSH) terms.

Similar search strategies were adopted in other databases. References from previous review articles and meta-analyses were also hand-searched. Two investigators (YM and TI) thoroughly assessed the quality of each article and selected the final included articles. Disagreement between investigators was discussed and resolved by consensus.

Meta-analysis was conducted using Cochrane Collaboration Review Manager 5.3 software (Cochrane, London, United Kingdom). Statistical analysis was performed using the Mantel-Haenszel method, and summary statistics were described as odds ratio (OR). We used a random-effects model with  $OR < 1$  favoring the investigation group and the OR point estimate was considered statistically significant at  $P < 0.05$  if the 95% confidence interval (CI) did not include the value 1. We also calculated  $I^2$  to assess homogeneity.

**Q1. What are the standard gallbladder drainage methods for AC in surgically high-risk patients?**

We recommend PTGBD as a standard drainage method for surgically high-risk patients with AC (Recommendation 1, level B). However, ETGBD or EUS-GBD could be considered in high-volume institutes when performed by skilled endoscopists (levelB).

## PTGBD

PTGBD should be considered the first alternative to surgical intervention in surgically high-risk patients with AC because several studies have described PTGBD as less invasive and having a lower risk of adverse events compared with cholecystectomy (OS) (14-21) (EO)(22, 23). The PTGBD procedure is described in the previous guidelines (2), and the technique is relatively easy for general clinicians to perform. Briefly, after ultrasound-guided transhepatic gallbladder puncture has been performed with an 18-G needle, a 6- to 10-Fr catheter is placed in the gallbladder using a guidewire under fluoroscopy. Of note, PTGBD for Grade III (severe) cases based on the TG13 severity grading was reported to be associated with higher mortality and mortality, higher readmission rates, and prolonged hospital stay (OS)(24).

## Endoscopic drainage

Recently, ETGBD under ERCP including ENGBD and EGBS, and EUS-GBD have been reported as novel effective alternative gallbladder drainage procedures in patients with AC in (RCT)(25-27), (OS)(28-43), (SR)(29, 38, 44, 45), (EO)(30, 33, 46), and a case study (CS)(47). Although there are no published papers, to our knowledge, comparing PTGBD and ETGBD, SRs have shown no significant difference regarding the technical success rate, clinical success rate, and the frequency of adverse events between PTGBD and EUS-GBD (SR)(32, 38, 44). The internal drainage obtained with endoscopic gallbladder drainage (EGBS/EUS-GBD) results in

less post-procedure pain than with the external drainage of PTGBD. However, because these internal procedures require difficult endoscopic techniques, and almost all reports regarding endoscopic drainage have been by skilled pancreatobiliary endoscopists from high-volume centers, these endoscopic techniques have not yet been established as standard procedures. Therefore, ETGBD and EUS-GBD should be considered in high-volume institutes by skilled pancreatobiliary endoscopists; otherwise, PTGBD should be selected as the standard drainage procedure.

#### PTGBA

Although PTGBA without catheter placement appears to be a simple and easy decompression method, aspiration could be unsuccessful because of replacement of bile with dense biliary sludge or pus (RCT)(20), (OS)(11, 20, 21). Therefore, PTGBA should not be recommended as a standard procedure for all patients with AC.

However, the latest international multicenter study (OS)(48) showed that the clinical success rate within 3 days of PTGBA was significantly higher than that of PTGBD and EGBS, although there was no significant difference within 7 days. Also, the complication rate of PTGBA was lower than that of PTGBD and EGBS. Several possible reasons are suggested when comparing previous reports, including the possibility that the PTGBA groups included patients with mild or moderate grade cholecystitis, and gallbladder lavage using saline during PTGBA was more effective



than simple drainage. Prospective RCTs using standardized techniques and devices for PTGBD, PTGBA, and endoscopic gallbladder drainage are warranted.

Gallbladder drainage for patients with coagulopathy or who are receiving antithrombotic agents

There are few reports discussing PTGBD for patients with AC and coagulopathy or who are receiving antithrombotic agents (CPG)(49)(MA)(50)(CS)(51). The Society of Interventional Radiology guidelines suggest that PTGBD can be performed without discontinuing acetylsalicylic acid if patients have a high risk of thromboembolism; however, the guidelines also recommend discontinuing clopidogrel for 5 days before PTGBD (CPG)(49). The guidelines also recommend that PTGBD in patients who are receiving anticoagulants should be performed with PT-INR < 1.5 and heparin substitution (CPG)(49). PTGBD for patients receiving both antiplatelet and anticoagulant agents should be avoided because there is no reliable data in these patients. ETGBD should be considered in such conditions when skilled pancreaticobiliary endoscopists are available in the institution.

**Q2. What procedure for preoperative drainage should be used for endoscopic transpapillary gallbladder drainage? ENGBD or EGBS?**

We suggest that either ENGBD or EGBS may be considered for gallbladder drainage based on the patient's background and endoscopist's decision (Recommendation 1, level B).

Detailed procedures for ENGBD and EGBS

ETGBD could be considered in high-volume institutes by skilled endoscopists as described in Q1. ETGBD can be divided into two different methods: ENGBD and EGBS. ENGBD involves placing a naso-gallbladder drainage tube and generally does not require sphincterotomy. The detailed techniques for ENGBD are as follows: After successful bile duct cannulation, a 0.025 or 0.035-inch guidewire is advanced into the cystic duct (Fig. 1a) and subsequently into the gallbladder (Fig. 1b). Next, the catheter is withdrawn and the guidewire remains in the gallbladder, and a 5 Fr to 8.5 Fr pigtail naso-gallbladder drainage tube is inserted into the gallbladder (Fig. 1c, Video 1). In comparison, the EGBS procedure is the same as for ENGBD, but a 6-Fr to 10-Fr internal stent is placed in the gallbladder, instead. Stent placement is not always successful because the cystic duct is frequently not visible on cholangiography, severe cystic duct stenosis and/or impacted stones in the neck of the gallbladder can block advancement of the guidewire and stent, and the tortuous valves of Heister can be difficult to traverse with standard guidewires (27). These procedures require skillful

techniques because prolonged or unsuccessful procedures may lead to serious complications such as post-ERCP pancreatitis and perforation of a cystic duct or gallbladder. Therefore, endoscopists should acquire accurate knowledge and technical skills including selective biliary cannulation and appropriate guidewire technique.

### ENGBD vs. EGBS

Recently, several reports evaluating the feasibility, safety, and efficacy of ETGBD have been published (SR)(31, 44), (OS)(25, 26, 28, 30, 33, 34, 38, 52), (EO)(32). This procedure appears to be especially suitable for patients with severe coagulopathy, thrombocytopenia, or an anatomically inaccessible location. To date, two RCTs (35, 53) and an SR(28) comparing ENGBD and EGBS have been published. A meta-analysis including these two RCTs was conducted in TG18 and found no statistically significant difference in technical success [odds ratio (OR): 1.18 (95% confidence interval (CI): 0.36–3.89)], clinical success [OR: 1.82 (95% CI: 0.40–8.26)], or adverse events rate [OR: 1.04 (95% CI: 0.29–3.81)] between ENGBD and EGBS (Fig. 2, 3 and 4, respectively). Note, however, that ENGBD involves cases in which the tube is removed by patients themselves because of discomfort. While EGBS carries a risk of stent obstruction, ENGBD has the advantage of flushing the bile via the transnasal tube (27). Consequently, the advantages and disadvantages of each drainage method are considered approximately equal, and TG18 suggests that either ENGBD or

EGBS may be considered for gallbladder drainage based on the patient's background and endoscopist's decision.

### **Special technique: EUS-GBD**

#### Technique

The gallbladder is punctured from the body or antrum of the stomach or duodenal bulb under direct EUS visualization. A 0.035-inch guidewire is inserted through the outer sheath, and dilation of the tract using a mechanical dilator, electrocautery dilator, or balloon dilator is then performed. Finally, a naso-gallbladder drainage tube (NGBT), double pigtail plastic stent (PS), or self-expandable metal stent (SEMS) is inserted into the gallbladder (Fig. 5, Video 2). More recently, lumen-apposing metal stents (LAMS) (Fig. 6a and b) (54, 55), the flared end of a covered SEMS (Fig. 6c) (56), and biflanged metal stents (Fig. 6d) (57) provide effective and safe drainage of gallbladder contents.

#### Outcomes

The latest outcomes regarding overall technical success rate, clinical success rate, and frequency of adverse events were 98.0% (194/198), 94.4% (187/198), and 12.1% (24/198), respectively (Table 1) (45). The technical success rate was 100% using NGBT, 100% using PS, 98.6% using SEMS, and 95.8% using LAMS, and the

clinical success rate was 100%, 100%, 94.5%, and 90.1 % using NGBT, PS, SEMS, and LAMS, respectively. There were no significant differences among these stents; however, LAMS may be ideal for EUS-GBD because it was associated with the lowest adverse events rate among the stents (40).

### **Acknowledgments**

We express our deep gratitude to the Japanese Society of Hepato-Biliary-Pancreatic Surgery, the Japanese Society of Abdominal Emergency Medicine, the Japanese Society of Surgical Infection, and the Japan Biliary Association, for their substantial support and guidance in the preparation of this article. We also would like to express our deep gratitude to the Japanese Society of Hepato-Biliary-Pancreatic Surgery for the Article Processing Managing Office of the Tokyo Guidelines 18 for preparing this publication. We appreciate all secretariats of the Japanese Society of Hepato-Biliary-Pancreatic Surgery for their technical support.

### **Conflicts of interest**

Anthony Yuen Bun Teoh, has received consultant fees from Boston Scientific Corporation, USA, Cook Medical, USA, and Taewoong Medical, Korea. Goro Honda has received honoraria from Johnson and Johnson and Medtronic.

## Appendix: Authors' Affiliations

Yasuhisa Mori, Department of Surgery and Oncology, Graduate School of Medical Sciences, Kyushu University, Fukuoka, Japan; Takao Itoi and Shuntaro Mukai, Department of Gastroenterology and Hepatology, Tokyo Medical University Hospital, Tokyo, Japan; Todd H. Baron, Division of Gastroenterology and Hepatology, University of North Carolina at Chapel Hill, NC, USA; Tadahiro Takada, Fumihiko Mira, and Keita Wada, Department of Surgery, Teikyo University School of Medicine, Tokyo, Japan; Steven M. Strasberg, Section of Hepato-Pancreato-Biliary Surgery, Washington University School of Medicine, St. Louis, MO, USA; Henry A. Pitt, Lewis Katz School of Medicine at Temple University, Philadelphia, PA, USA; Tomohiko Ukai, Department of Family Medicine, Mie Prefectural Ichishi Hospital, Mie, Japan; Satoru Shikata, Director, Mie Prefectural Ichishi Hospital, Mie, Japan; Yoshinori Noguchi and Masamichi Yokoe, Department of General Internal Medicine, Japanese Red Cross Nagoya Daini Hospital, Aichi, Japan; Anthony Yuen Bun Teoh, Department of Surgery, The Chinese University of Hong Kong, Shatin, Hong Kong; Myung-Hwan Kim, Department of Gastroenterology, University of Ulsan College of Medicine, Seoul, Korea; Horacio J. Asbun, Department of Surgery, Mayo Clinic College of Medicine, FL, USA; Itaru Endo, Department of Gastroenterological Surgery, Yokohama City University Graduate School of Medicine, Kanagawa, Japan; Kohji Okamoto, Department of Surgery, Center for Gastroenterology and Liver Disease, Kitakyushu City Yahata Hospital, Fukuoka, Japan; Kenji Suzuki, Department of Surgery, Fujinomiya City General Hospital, Shizuoka, Japan; Akiko Umezawa,

Minimally Invasive Surgery Center, Yotsuya Medical Cube, Tokyo, Japan; Yukio Iwashita, Department of Gastroenterological and Pediatric Surgery, Oita University Faculty of Medicine, Oita, Japan; Taizo Hibi, Department of Surgery, Keio University School of Medicine, Tokyo, Japan; Go Wakabayashi, Department of Surgery, Ageo Central General Hospital, Saitama, Japan; Ho-Seong Han and Yoo-Seok Yoon, Department of Surgery, Seoul National University Bundang Hospital, Seoul National University College of Medicine, Seoul, Korea; In-Seok Choi, Department of Surgery, Konyang University Hospital, Daejeon, Korea; Tsann-Long Hwang, Miin-Fu Chen, and Keng-Hao Liu, Division of General Surgery, Linkou Chang Gung Memorial Hospital, Taoyuan, Taiwan; O. James Garden, Clinical Surgery, University of Edinburgh, Edinburgh, UK; Harjit Singh, Department of Hepato-Pancreato-Biliary Surgery, Hospital Selayang, Malaysia; Kui-Hin Liao, Liao KH Consulting PL, Mt Elizabeth Novena Hospital Singapore & Yong Loo Lin School of Medicine, National University of Singapore, Singapore; Wayne Shih-Wei Huang, Department of Surgery, Show Chwan Memorial Hospital, Changhua, Taiwan; Dirk Joan Gouma, Department of Surgery, Academic Medical Center, Amsterdam, The Netherlands; Giulio Belli, Department of General and HPB Surgery, Loreto Nuovo Hospital, Naples Italy; Christos Dervenis, First Department of Surgery, Agia Olga Hospital, Athens, Greece; Eduardo de Santibañes, Department of Surgery, Hospital Italiano, University of Buenos Aires, Buenos Aires, Argentina; Mariano Eduardo Giménez, Chair of General Surgery and Minimal Invasive Surgery “Taquini” University of Buenos Aires. Argentina, DAICIM Foundation, Argentina; John Albert Windsor, Department of

This article is protected by copyright. All rights reserved.

Surgery, The University of Auckland, Auckland, New Zealand; Wan Yee Lau, Faculty of Medicine, The Chinese University of Hong Kong, Shatin, Hong Kong; Daniel Cherqui, Hepatobiliary Center, Paul Brousse Hospital, Villejuif, France; Palepu Jagannath, Department of Surgical Oncology, Lilavati Hospital and Research Centre, Mumbai, India; Avinash Nivritti Supe, Department of Surgical gastroenterology, Seth G S Medical College and K E M Hospital, Mumbai, India; Cheng-Hsi Su, Department of Surgery, Cheng Hsin General Hospital, Taipei, Taiwan; Daniel J. Deziel, Department of Surgery, Rush University Medical Center, Chicago, USA; Xiao-Ping Chen, Hepatic Surgery Centre, Department of Surgery, Tongji Hospital, Tongji Medical College, Huazhong University of Science and Technology, Wuhan, China; Sheung Tat Fan, Department of Surgery, The University of Hong Kong, Queen Mary Hospital, Hong Kong, Hong Kong; Chen-Guo Ker, Department of Surgery, Yuan's General Hospital, Kaohsiung, Taiwan; Eduard C. Jonas, Surgical Gastroenterology/Hepatopancreatobiliary Unit, University of Cape Town and Groote Schuur Hospital, Cape Town, South Africa; Robert Padbury, Division of Surgical and Specialty Services, Flinders Medical Centre, Adelaide, Australia; Goro Honda, Department of Surgery, Tokyo Metropolitan Komagome Hospital, Tokyo, Japan; Atsushi Sugioka, Department of Surgery, Fujita Health University School of Medicine, Aichi, Japan; Koji Asai, Department of Surgery, Toho University Ohashi Medical Center, Tokyo, Japan; Ryota Higuchi and Masakazu Yamamoto, Department of Surgery, Institute of Gastroenterology, Tokyo Women's Medical University, Tokyo, Japan; Masahiro Yoshida, Department of Hemodialysis and Surgery, chemotherapy



research institute Kaken hospital, International University of Health and Welfare, Chiba, Department of EBM and Guidelines, Japan council for Quality Health Care, Tokyo, Japan; Toshihiko Mayumi, Department of Emergency Medicine, School of Medicine University of Occupational and Environmental Health, Fukuoka, Japan; Koichi Hirata, Department of Surgery, JR Sapporo Hospital, Hokkaido, Japan; Yoshinobu Sumiyama, Director, Toho University, Tokyo, Japan; Kazuo Inui, Department of Gastroenterology, Second Teaching Hospital, Fujita Health University, Aichi, Japan

### References

1. Tsuyuguchi T, Takada T, Kawarada Y, Nimura Y, Wada K, Nagino M, et al. Techniques of biliary drainage for acute cholecystitis: Tokyo Guidelines. Journal of hepato-biliary-pancreatic surgery. 2007;14(1):46-51.
2. Tsuyuguchi T, Itoi T, Takada T, Strasberg SM, Pitt HA, Kim MH, et al. TG13 indications and techniques for gallbladder drainage in acute cholecystitis (with videos). Journal of hepato-biliary-pancreatic sciences. 2013;20(1):81-8.
3. Loozen CS, van Ramshorst B, van Santvoort HC, Boerma D. Early Cholecystectomy for Acute Cholecystitis in the Elderly Population: A Systematic Review and Meta-Analysis. Dig Surg. 2017.

4. Yokoe M, Takada T, Hwang TL, Endo I, Akazawa K, Miura F, et al.

Descriptive review of acute cholecystitis: Japan-Taiwan collaborative epidemiological study. *Journal of hepato-biliary-pancreatic sciences*. 2017;24(6):319-28.

5. Yokoe M, Takada T, Hwang TL, Endo I, Akazawa K, Miura F, et al.

Validation of TG13 severity grading in acute cholecystitis: Japan-Taiwan collaborative study for acute cholecystitis. *Journal of hepato-biliary-pancreatic sciences*. 2017;24(6):338-45.

6. Iwashita Y, Hibi T, Ohyama T, Honda G, Yoshida M, Miura F, et al. An

opportunity in difficulty: Japan-Korea-Taiwan expert Delphi consensus on surgical difficulty during laparoscopic cholecystectomy. *Journal of hepato-biliary-pancreatic sciences*. 2017;24(4):191-8.

7. Hibi T, Iwashita Y, Ohyama T, Honda G, Yoshida M, Takada T, et al. The

"right" way is not always popular: comparison of surgeons' perceptions during laparoscopic cholecystectomy for acute cholecystitis among experts from Japan, Korea and Taiwan. *Journal of hepato-biliary-pancreatic sciences*. 2017;24(1):24-32.

8. Asai K, Watanabe M, Kusachi S, Matsukiyo H, Saito T, Ishii T, et al.

Evaluating the timing of laparoscopic cholecystectomy for acute cholecystitis in an experienced center based on propensity score matching. *Asian journal of endoscopic surgery*. 2017;10(2):166-72.

9. Endo I, Takada T, Hwang TL, Akazawa K, Mori R, Miura F, et al. Optimal

treatment strategy for acute cholecystitis based on predictive factors: Japan-Taiwan

This article is protected by copyright. All rights reserved.

multicenter cohort study. Journal of hepato-biliary-pancreatic sciences.

2017;24(6):346-61.

10. Ito K, Fujita N, Noda Y, Kobayashi G, Kimura K, Sugawara T, et al.

Percutaneous cholecystostomy versus gallbladder aspiration for acute cholecystitis: a prospective randomized controlled trial. AJR Am J Roentgenol. 2004;183(1):193-6.

11. Komatsu S, Tsuchida S, Tsukamoto T, Wakahara T, Ashitani H, Ueno N, et al.

Current role of percutaneous transhepatic gallbladder aspiration: from palliative to curative management for acute cholecystitis. Journal of hepato-biliary-pancreatic sciences. 2016;23(11):708-14.

12. Takada T, Strasberg SM, Solomkin JS, Pitt HA, Gomi H, Yoshida M, et al.

TG13: Updated Tokyo Guidelines for the management of acute cholangitis and cholecystitis. Journal of hepato-biliary-pancreatic sciences. 2013;20(1):1-7.

13. Takada T, XXXX, YYYY, et al. ZZZZZZZZ. Journal of

hepato-biliary-pancreatic sciences. 2018.

14. Kiviniemi H, Makela JT, Autio R, Tikkakoski T, Leinonen S, Siniluoto T, et

al. Percutaneous cholecystostomy in acute cholecystitis in high-risk patients: an analysis of 69 patients. Int Surg. 1998;83(4):299-302.

15. Sugiyama M, Tokuhara M, Atomi Y. Is percutaneous cholecystostomy the

optimal treatment for acute cholecystitis in the very elderly? World J Surg.

1998;22(5):459-63.

16. Chopra S, Dodd GD, 3rd, Mumbower AL, Chintapalli KN, Schwesinger WH, Sirinek KR, et al. Treatment of acute cholecystitis in non-critically ill patients at high surgical risk: comparison of clinical outcomes after gallbladder aspiration and after percutaneous cholecystostomy. *AJR Am J Roentgenol.* 2001;176(4):1025-31.
17. Akhan O, Akinci D, Ozmen MN. Percutaneous cholecystostomy. *Eur J Radiol.* 2002;43(3):229-36.
18. Donald JJ, Cheslyn-Curtis S, Gillams AR, Russell RC, Lees WR. Percutaneous cholecystolithotomy: is gall stone recurrence inevitable? *Gut.* 1994;35(5):692-5.
19. Hultman CS, Herbst CA, McCall JM, Mauro MA. The efficacy of percutaneous cholecystostomy in critically ill patients. *Am Surg.* 1996;62(4):263-9.
20. Melin MM, Sarr MG, Bender CE, van Heerden JA. Percutaneous cholecystostomy: a valuable technique in high-risk patients with presumed acute cholecystitis. *Br J Surg.* 1995;82(9):1274-7.
21. Davis CA, Landercasper J, Gundersen LH, Lambert PJ. Effective use of percutaneous cholecystostomy in high-risk surgical patients: techniques, tube management, and results. *Arch Surg.* 1999;134(7):727-31; discussion 31-2.
22. Babb RR. Acute acalculous cholecystitis. A review. *J Clin Gastroenterol.* 1992;15(3):238-41.

23. Lillemoe KD. Surgical treatment of biliary tract infections. *Am Surg*. 2000;66(2):138-44.
24. Dimou FM, Adhikari D, Mehta HB, Riall TS. Outcomes in Older Patients with Grade III Cholecystitis and Cholecystostomy Tube Placement: A Propensity Score Analysis. *J Am Coll Surg*. 2017;224(4):502-11.e1.
25. Yang MJ, Yoo BM, Kim JH, Hwang JC, Baek NH, Kim SS, et al. Endoscopic naso-gallbladder drainage versus gallbladder stenting before cholecystectomy in patients with acute cholecystitis and a high suspicion of choledocholithiasis: a prospective randomised preliminary study. *Scand J Gastroenterol*. 2016;51(4):472-8.
26. Jang JW, Lee SS, Song TJ, Hyun YS, Park DY, Seo DW, et al. Endoscopic ultrasound-guided transmural and percutaneous transhepatic gallbladder drainage are comparable for acute cholecystitis. *Gastroenterology*. 2012;142(4):805-11.
27. Itoi T, Kawakami H, Katanuma A, Irisawa A, Sofuni A, Itokawa F, et al. Endoscopic nasogallbladder tube or stent placement in acute cholecystitis: a preliminary prospective randomized trial in Japan (with videos). *Gastrointest Endosc*. 2015;81(1):111-8.
28. Walter D, Teoh AY, Itoi T, Perez-Miranda M, Larghi A, Sanchez-Yague A, et al. EUS-guided gall bladder drainage with a lumen-apposing metal stent: a prospective long-term evaluation. *Gut*. 2016;65(1):6-8.

29. Choi JH, Lee SS, Choi JH, Park DH, Seo DW, Lee SK, et al. Long-term outcomes after endoscopic ultrasonography-guided gallbladder drainage for acute cholecystitis. *Endoscopy*. 2014;46(8):656-61.
30. Widmer J, Singhal S, Gaidhane M, Kahaleh M. Endoscopic ultrasound-guided endoluminal drainage of the gallbladder. *Dig Endosc*. 2014;26(4):525-31.
31. Kedia P, Sharaiha RZ, Kumta NA, Widmer J, Jamal-Kabani A, Weaver K, et al. Endoscopic gallbladder drainage compared with percutaneous drainage. *Gastrointest Endosc*. 2015;82(6):1031-6.
32. Khan MA, Atiq O, Kubiliun N, Ali B, Kamal F, Nollan R, et al. Efficacy and safety of endoscopic gallbladder drainage in acute cholecystitis: Is it better than percutaneous gallbladder drainage? *Gastrointest Endosc*. 2017;85(1):76-87.e3.
33. Itoi T. New era in acute cholecystitis treatment: encouraging results for interventional endoscopists. *Gastrointest Endosc*. 2017;85(1):88-9.
34. Tyberg A, Saumoy M, Sequeiros EV, Giovannini M, Artifon E, Teoh A, et al. EUS-guided Versus Percutaneous Gallbladder Drainage: Isn't It Time to Convert? *J Clin Gastroenterol*. 2016.
35. Teoh AYB, Serna C, Penas I, Chong CCN, Perez-Miranda M, Ng EKW, et al. Endoscopic ultrasound-guided gallbladder drainage reduces adverse events compared with percutaneous cholecystostomy in patients who are unfit for cholecystectomy. *Endoscopy*. 2017;49(2):130-8.

36. Mutignani M, Iacopini F, Perri V, Familiari P, Tringali A, Spada C, et al. Endoscopic gallbladder drainage for acute cholecystitis: technical and clinical results. *Endoscopy*. 2009;41(6):539-46.
37. Pannala R, Petersen BT, Gostout CJ, Topazian MD, Levy MJ, Baron TH. Endoscopic transpapillary gallbladder drainage: 10-year single center experience. *Minerva Gastroenterol Dietol*. 2008;54(2):107-13.
38. Penas-Herrero I, de la Serna-Higuera C, Perez-Miranda M. Endoscopic ultrasound-guided gallbladder drainage for the management of acute cholecystitis (with video). *Journal of hepato-biliary-pancreatic sciences*. 2015;22(1):35-43.
39. Maekawa S, Nomura R, Murase T, Ann Y, Oeholm M, Harada M. Endoscopic gallbladder stenting for acute cholecystitis: a retrospective study of 46 elderly patients aged 65 years or older. *BMC Gastroenterol*. 2013;13:65.
40. Song TJ, Park DH, Eum JB, Moon SH, Lee SS, Seo DW, et al. EUS-guided cholecystoenterostomy with single-step placement of a 7F double-pigtail plastic stent in patients who are unsuitable for cholecystectomy: a pilot study (with video). *Gastrointest Endosc*. 2010;71(3):634-40.
41. Kahaleh M, Perez-Miranda M, Artifon EL, Sharaiha RZ, Kedia P, Penas I, et al. International collaborative study on EUS-guided gallbladder drainage: Are we ready for prime time? *Dig Liver Dis*. 2016;48(9):1054-7.

42. Kwan V, Eisendrath P, Antaki F, Le Moine O, Deviere J. EUS-guided cholecystenterostomy: a new technique (with videos). *Gastrointest Endosc.* 2007;66(3):582-6.
43. Dollhopf M, Larghi A, Will U, Rimbas M, Anderloni A, Sanchez-Yague A, et al. EUS-guided gallbladder drainage in patients with acute cholecystitis and high surgical risk using an electrocautery-enhanced lumen-apposing metal stent device. *Gastrointest Endosc.* 2017.
44. Itoi T, Coelho-Prabhu N, Baron TH. Endoscopic gallbladder drainage for management of acute cholecystitis. *Gastrointest Endosc.* 2010;71(6):1038-45.
45. Anderloni A, Buda A, Vieceli F, Khashab MA, Hassan C, Repici A. Endoscopic ultrasound-guided transmural stenting for gallbladder drainage in high-risk patients with acute cholecystitis: a systematic review and pooled analysis. *Surg Endosc.* 2016;30(12):5200-8.
46. Choi JH, Lee SS. Endoscopic ultrasonography-guided gallbladder drainage for acute cholecystitis: from evidence to practice. *Dig Endosc.* 2015;27(1):1-7.
47. Itoi T, Itokawa F, Sofuni A, Kurihara T, Tsuchiya T, Ishii K, et al. Endoscopic ultrasound-guided choledochoduodenostomy in patients with failed endoscopic retrograde cholangiopancreatography. *World J Gastroenterol.* 2008;14(39):6078-82.
48. Itoi T, Takada T, Hwang TL, Endo I, Akazawa K, Miura F, et al. Percutaneous and endoscopic gallbladder drainage for acute cholecystitis: international multicenter



comparative study using propensity score-matched analysis. *Journal of hepato-biliary-pancreatic sciences*. 2017;24(6):362-8.

49. Patel IJ, Davidson JC, Nikolic B, Salazar GM, Schwartzberg MS, Walker TG, et al. Consensus guidelines for periprocedural management of coagulation status and hemostasis risk in percutaneous image-guided interventions. *J Vasc Interv Radiol*. 2012;23(6):727-36.

50. Hamada T, Yasunaga H, Nakai Y, Isayama H, Horiguchi H, Fushimi K, et al. Severe bleeding after percutaneous transhepatic drainage of the biliary system: effect of antithrombotic agents--analysis of 34 606 cases from a Japanese nationwide administrative database. *Radiology*. 2015;274(2):605-13.

51. Shibasaki S, Takahashi N, Toi H, Tsuda I, Nakamura T, Hase T, et al. Percutaneous transhepatic gallbladder drainage followed by elective laparoscopic cholecystectomy in patients with moderate acute cholecystitis under antithrombotic therapy. *Journal of hepato-biliary-pancreatic sciences*. 2014;21(5):335-42.

52. Irani S, Ngamruengphong S, Teoh A, Will U, Nieto J, Abu Dayyeh BK, et al. Similar Efficacies of Endoscopic Ultrasound Gallbladder Drainage With a Lumen-Apposing Metal Stent Versus Percutaneous Transhepatic Gallbladder Drainage for Acute Cholecystitis. *Clin Gastroenterol Hepatol*. 2017;15(5):738-45.

53. Tsutsui K, Uchida N, Hirabayashi S, Kamada H, Ono M, Ogawa M, et al. Usefulness of single and repetitive percutaneous transhepatic gallbladder aspiration for the treatment of acute cholecystitis. *J Gastroenterol*. 2007;42(7):583-8.

This article is protected by copyright. All rights reserved.

54. Itoi T, Binmoeller KF, Shah J, Sofuni A, Itokawa F, Kurihara T, et al. Clinical evaluation of a novel lumen-apposing metal stent for endosonography-guided pancreatic pseudocyst and gallbladder drainage (with videos). *Gastrointest Endosc.* 2012;75(4):870-6.
55. Moon JH, Choi HJ, Kim DC, Lee YN, Kim HK, Jeong SA, et al. A newly designed fully covered metal stent for lumen apposition in EUS-guided drainage and access: a feasibility study (with videos). *Gastrointest Endosc.* 2014;79(6):990-5.
56. Jang JW, Lee SS, Park DH, Seo DW, Lee SK, Kim MH. Feasibility and safety of EUS-guided transgastric/transduodenal gallbladder drainage with single-step placement of a modified covered self-expandable metal stent in patients unsuitable for cholecystectomy. *Gastrointest Endosc.* 2011;74(1):176-81.
57. Mukai S, Tsuchiya T, Itoi T, Tsuji S, Tanaka R, Tonozuka R, et al. Prospective evaluation of a new biflanged metal stent for the treatment of pancreatic fluid collections (with videos). *Gastrointest Endosc.* 2017;86(1):203-7.

## FIGURE LEGENDS

Figure 1. Detailed procedure for endoscopic naso-gallbladder drainage. After successful bile duct cannulation, a 0.025- or 0.035-inch guidewire is advanced into the cystic duct (a) and subsequently into the gallbladder (b). Next, the catheter is withdrawn, and the guidewire remains in the gallbladder, then a 5-Fr to 8.5-Fr pigtail naso-gallbladder drainage tube is inserted into the gallbladder (c).

Figure 2. Forest plot analysis of technical success rate of endoscopic naso-gallbladder drainage versus endoscopic gallbladder stenting.

Figure 3. Forest plot analysis of clinical success rate of endoscopic naso-gallbladder drainage versus endoscopic gallbladder stenting.

Figure 4. Forest plot analysis of adverse events of endoscopic naso-gallbladder drainage versus endoscopic gallbladder stenting.

Figure 5. Schema of endoscopic ultrasound-guided gallbladder drainage.

Figure 6. Metal stents for endoscopic ultrasound-guided gallbladder drainage. (a)

Fully-covered 10-mm-diameter lumen-apposing stent with dual anchor flanges. (b)

Fully-covered metal stent with folding-back wide anchoring flanges for lumen

apposition. (c) The flared end of a covered self-expandable metal stent. (d) Biflanged

metal stent.

Video 1. Detailed procedure for endoscopic naso-gallbladder drainage.

Video 2. Detailed procedure for endoscopic ultrasound-guided gallbladder drainage.

Table 1. Comparison of different gallbladder drainage techniques/materials for technical success, clinical success, and adverse events.

	Technical success	Clinical success	Adverse event
NGBT	100% (32/32)	100% (32/32)	12.5% (4/32)
PS	100% (22/22)	100% (22/22)	18.2% (4/22)
SEMS	98.6% (72/73)	94.5% (69/73)	12.3% (9/73)
LAMS	95.8% (68/71)	90.1% (64/71)	9.9% (7/71)
Total	98.0% (194/198)	94.4% (187/198)	12.1% (24/198)

NGBT: naso-gallbladder drainage tube

PS: plastic stent

SEMS: self-expandable metal stent

LAMS: lumen-apposing stent

Figure 1

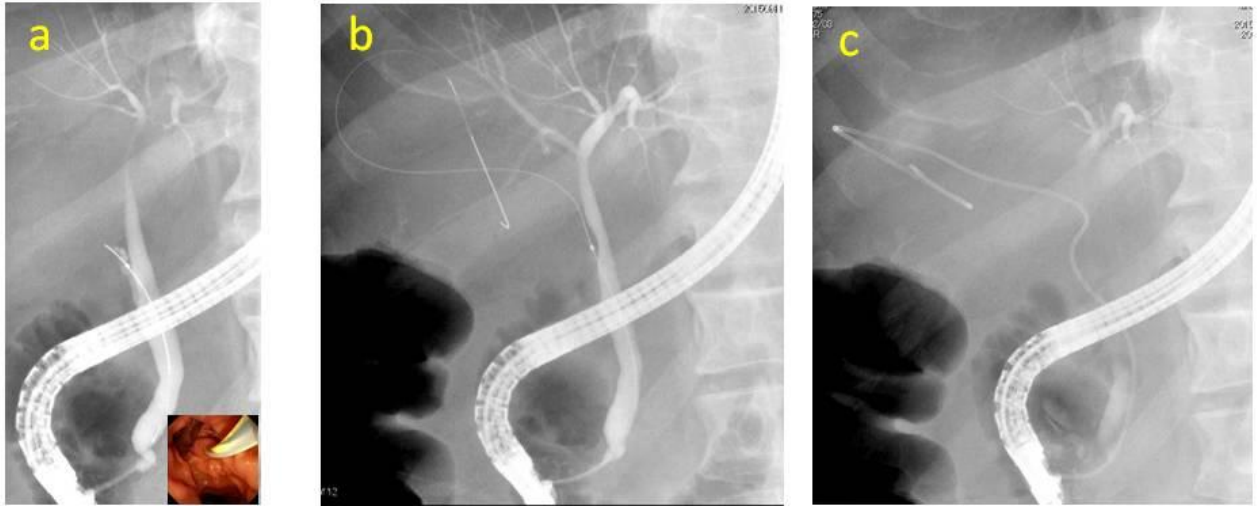
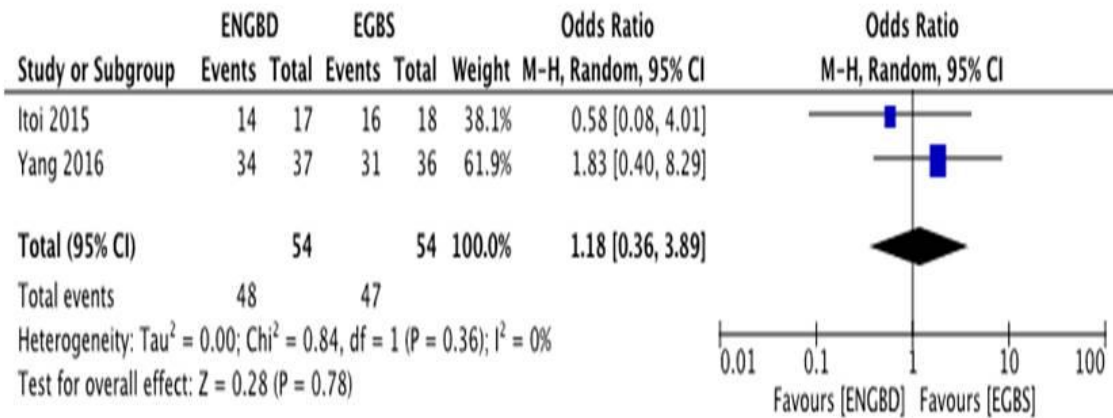


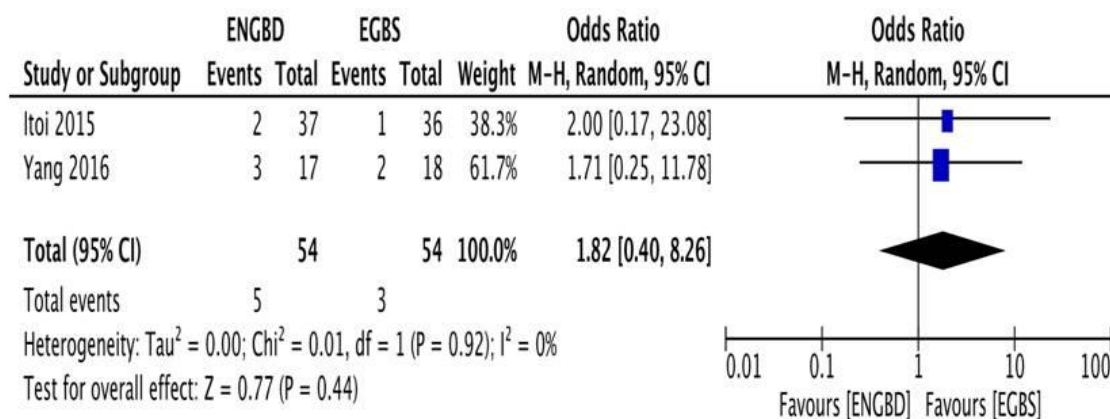
Figure 2

Technical success



**Figure 3**

Clinical success



**Figure 4**

Adverse event

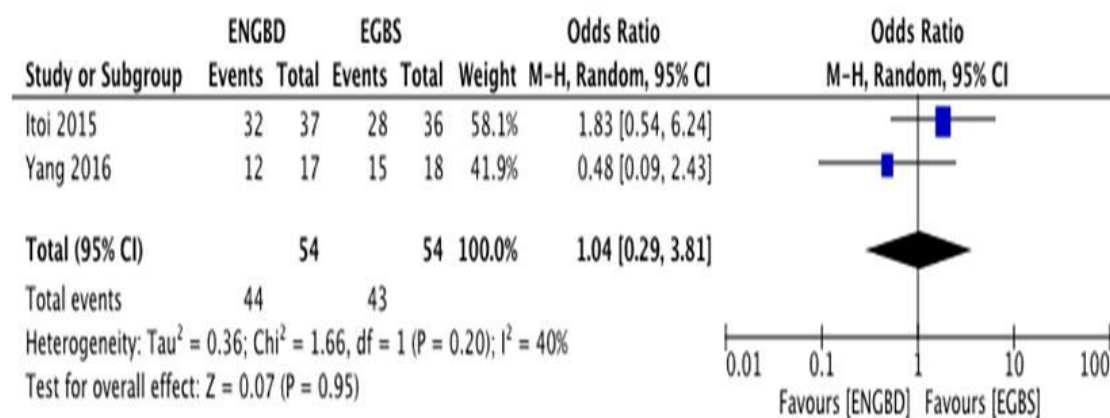


Figure 5

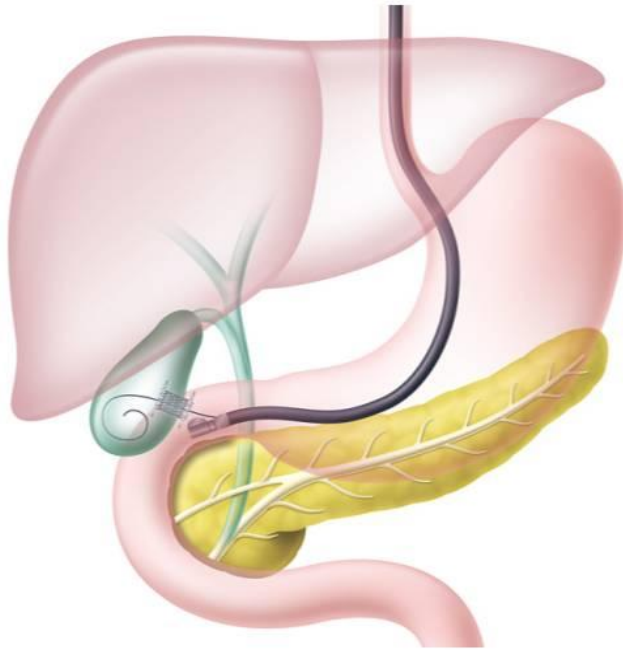


Figure 6

