



THE UNIVERSITY *of* EDINBURGH

Edinburgh Research Explorer

Hepatoprotective effects of Biochanin A on thioacetamide-induced liver cirrhosis in experimental rats.

Citation for published version:

Ibrahim, MY, Alamri, ZZ, Juma, ASM, Hamood, SA, Shareef, SH, Abdulla, MA & Jayash, S 2023, 'Hepatoprotective effects of Biochanin A on thioacetamide-induced liver cirrhosis in experimental rats.', *Molecules*, vol. 22, no. 28, 7608, pp. 1-14. <https://doi.org/10.3390/molecules28227608>

Digital Object Identifier (DOI):

[10.3390/molecules28227608](https://doi.org/10.3390/molecules28227608)

Link:

[Link to publication record in Edinburgh Research Explorer](#)

Document Version:

Publisher's PDF, also known as Version of record

Published In:

Molecules

General rights

Copyright for the publications made accessible via the Edinburgh Research Explorer is retained by the author(s) and / or other copyright owners and it is a condition of accessing these publications that users recognise and abide by the legal requirements associated with these rights.



Take down policy

The University of Edinburgh has made every reasonable effort to ensure that Edinburgh Research Explorer content complies with UK legislation. If you believe that the public display of this file breaches copyright please contact openaccess@ed.ac.uk providing details, and we will remove access to the work immediately and investigate your claim.



Article

Hepatoprotective Effects of Biochanin A on Thioacetamide-Induced Liver Cirrhosis in Experimental Rats

Mohamed Yousif Ibrahim ^{1,*}, Zaenah Zuhair Alamri ², Ameena S. M. Juma ³, Sarah Ashour Hamood ⁴, Suhayla Hamad Shareef ⁵ , Mahmood Ameen Abdulla ³ and Soher Nagi Jayash ^{6,*} 

¹ Faculty of Pharmacy, Elrazi University, Khartoum 11115, Sudan

² Department of Biological Sciences, Faculty of Science, University of Jeddah, Jeddah 21589, Saudi Arabia; zzalamri@uj.edu.sa

³ Department of Medical Microbiology, College of Science, Cihan University-Erbil, Erbil 44001, Iraq; ameena.sabah@cihanuniversity.edu.iq (A.S.M.J.); mahmood.ameen@cihanuniversity.edu.iq (M.A.A.)

⁴ Biomedical Engineering Department, Al-Esraa University College, Baghdad 10011, Iraq; sara.ashour@esraa.edu.iq

⁵ Department of Biology, College of Education, Salahaddin University-Erbil, Erbil 44001, Iraq; suhayla.shareef@su.edu.krd

⁶ The Roslin Institute and Royal (Dick) School of Veterinary Studies, University of Edinburgh, Easter Bush Campus, Midlothian EH25 9RG, UK

* Correspondence: al_omdah2003@hotmail.com or dean.ph@elrazi.edu.sd (M.Y.I.); soheernaji20@yahoo.com or sjayash@ed.ac.uk (S.N.J.)

Abstract: The protective effect of biochanin A (BCA) on the histopathology, immunohistochemistry, and biochemistry of thioacetamide (TAA)-induced liver cirrhosis in vivo was investigated. There was a significant reduction in liver weight and hepatocyte propagation, with much lower cell injury in rat groups treated with BCA (25 mg/kg and 50 mg/kg) following a TAA induction. These groups had significantly lower levels of proliferating cell nuclear antigen (PCNA) and α -smooth muscle actin (α -SMA). The liver homogenates showed increased antioxidant enzyme activity of superoxide dismutase (SOD), catalase (CAT), and glutathione peroxidase (GPx), as well as decreased malondialdehyde (MDA) levels. The serum biomarkers associated with liver function, namely alkaline phosphatase (ALP), alanine aminotransferase (ALT), aspartate aminotransferase (AST), and gamma glutamyl transaminase (GGT), returned to normal levels, comparable to those observed in both the normal control group and the reference control group. Taken together, the normal microanatomy of hepatocytes, the inhibition of PCNA and α -SMA, improved antioxidant enzymes (SOD, CAT, and GPx), and condensed MDA with repairs of liver biomarkers validated BCA's hepatoprotective effect.

Keywords: liver cirrhosis; TAA; biochanin A; antioxidant enzymes; histopathology; immunohistochemistry



Citation: Ibrahim, M.Y.; Alamri, Z.Z.; Juma, A.S.M.; Hamood, S.A.; Shareef, S.H.; Abdulla, M.A.; Jayash, S.N. Hepatoprotective Effects of Biochanin A on Thioacetamide-Induced Liver Cirrhosis in Experimental Rats. *Molecules* **2023**, *28*, 7608. <https://doi.org/10.3390/molecules28227608>

Academic Editors: Chun Guang Li, Riccardo Petrelli, Alberto C. P. Dias and Saiwang Seto

Received: 5 September 2023

Revised: 7 November 2023

Accepted: 9 November 2023

Published: 15 November 2023



Copyright: © 2023 by the authors. Licensee MDPI, Basel, Switzerland. This article is an open access article distributed under the terms and conditions of the Creative Commons Attribution (CC BY) license (<https://creativecommons.org/licenses/by/4.0/>).

1. Introduction

Liver fibrosis is a significant health concern that arises from a range of persistent liver injuries such as chemical exposure, parasitic infections, alcohol consumption, viral hepatitis B and C, and autoimmune hepatitis [1,2]. Chronic liver diseases have a significant impact on a vast number of individuals worldwide, with approximately 30 percent of the patients being susceptible to the development of fibrosis and cirrhosis. Additionally, this ailment has the potential to result in hepatic carcinoma and escalation of fatality rates [3]. The aforementioned illness is distinguished by the buildup of collagen within the hepatic lobules, concomitant with the process of tissue repair [4,5]. In cases of acute or self-limiting injury, these alterations are temporary, and the hepatic architecture reverts to its baseline condition. However, in the event of damage, the inflammatory response may persist and lead to the accumulation of extracellular matrix (ECM), ultimately resulting in the replacement of liver parenchyma with scar tissue [6]. Hepatic stellate cells (HSCs)

are recognized as the principal producers of ECM. The activation and proliferation of HSCs and fibrotic tissues are regulated by reactive oxygen species (ROS) and inflammatory cytokines [7]. The activation of HSCs leads to increased expression of fibrotic biomarkers, such as alpha-smooth muscle actin (α -SMA) and autotaxin (ATX) [8].

Thioacetamide (TAA) is a fungicidal agent that is extensively employed in the textile sector [9]. At present, it is categorized as a substance capable of causing cancer. During the process of metabolism, the production of free radical derivatives, namely TAA-S-S-dioxide and TAA-S-S-sulfoxide, was observed. These derivatives have been found to be responsible for causing centrilobular necrosis and subsequent liver damage, as reported previously [10]. The hepatotoxic properties of TAA have been acknowledged, as it induces fibrosis in laboratory animals, which is comparable to human fibrosis and is almost irreversible. This renders TAA a suitable model for evaluating the efficacy of antifibrotic drugs [11].

The current pharmaceutical management of liver fibrosis is insufficient because no drug has shown complete efficacy in halting this disease. Despite the utilization of recently developed medications for the management of chronic liver illnesses, it is frequently observed that these drug interventions are accompanied by adverse effects. Therefore, alternative pharmaceutical options are required for the treatment of liver disorders. Moreover, there has been a growing interest in exploring alternative drugs for the treatment of liver illnesses and related metabolic disturbances, particularly natural product-based drugs [12,13].

Biochanin A (BCA) (Figure 1) is a prominent isoflavone that has been extracted from various plants such as red clover, soy, and chickpea [14]. BCA exhibits a diverse array of pharmacological and biological properties, including anticancer, anti-inflammatory, antioxidant, neuroprotective, antimicrobial, and hepatoprotective effects [15,16].

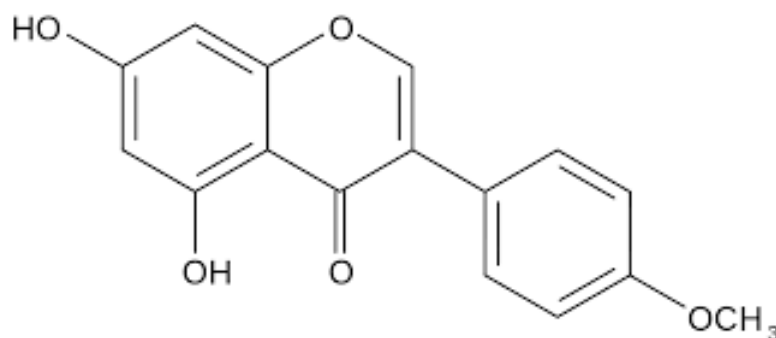


Figure 1. Chemical Structure of Biochanin A.

In view of that, the present study provides an update on the hepatoprotective and antifibrotic mechanisms of BCA in TAA-induced cirrhosis in rats.

2. Results

2.1. Acute Toxicity Study

14 days of observation were performed on experimental animals given BCA at doses of 20 mg/kg and 200 mg/kg [17,18]. Throughout the experiment, no signs of toxicity, changes in behavior, abnormalities in body weight, or major discoveries were observed in the experimental animals. At the end of the experiment, neither dose resulted in fatality. None of the groups displayed statistically significant differences in liver and kidney histopathology or biochemical markers in the blood compared with the control (Figure 2 and Table 1).

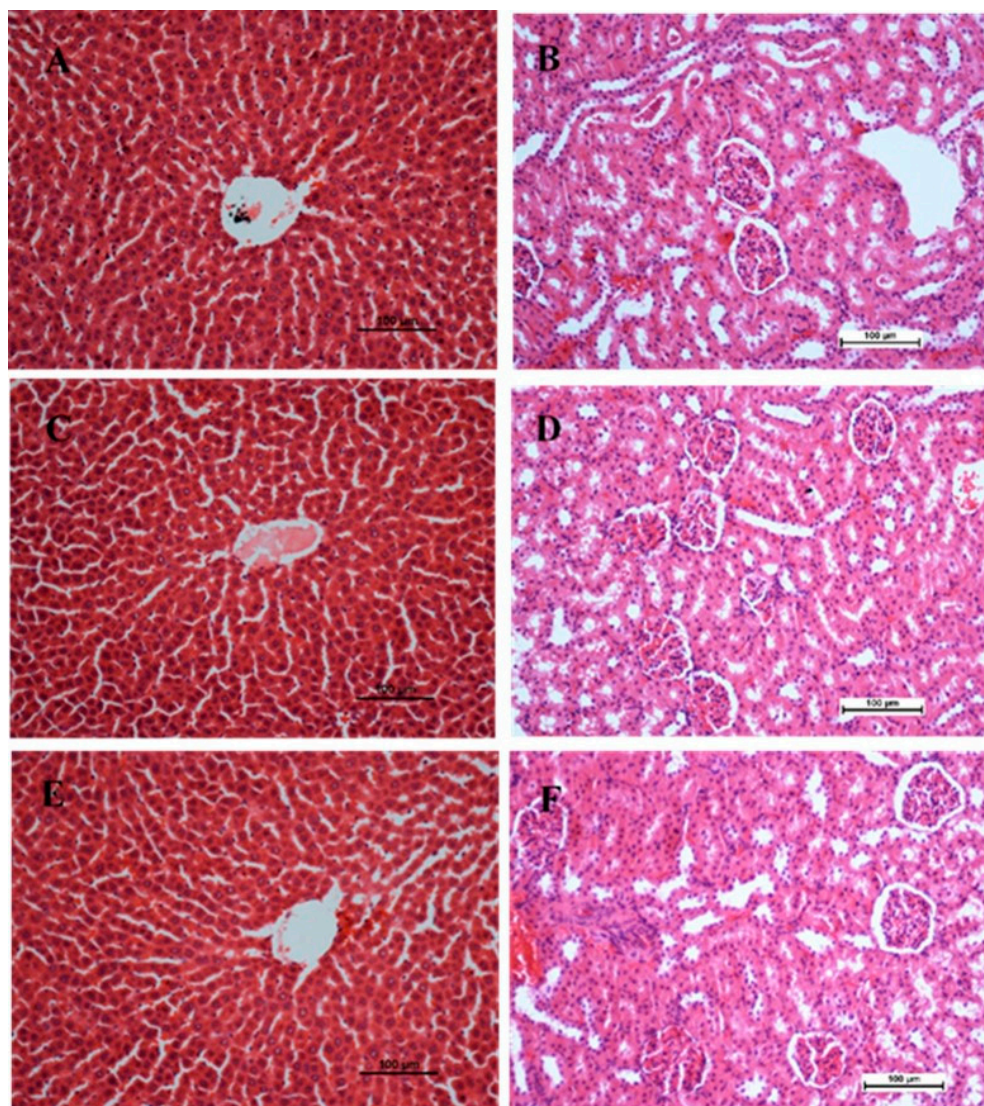


Figure 2. Effect of biochanin A (BCA) on histological sections of the liver (1st column) and kidney (2nd column) from acute toxicity test in rats. (A,B) Normal control group (C,D) rats fed with 20 mg g/kg of BCA (E,F) rats fed with 200 mg/kg of BCA. There is no significant change in the architecture of the livers and kidneys between the treated and control groups (Hematoxylin and Eosin stain, 20 \times). Scale bar 100 μ m.

2.2. Body Weight, Liver Weight, and Liver Index

The body weights of all animals were measured weekly before sacrifice. Table 2 shows the body and liver weights of the rats in the different groups after two months. Normal control rats exhibited weight gain ranging from 255 to 473 grams over the course of two months. The TAA group weighed significantly less than the other groups ($p < 0.05$). The liver index in the TAA group was the highest (liver/body weight ratio). In contrast, the liver index was significantly lowered by 25 or 50 mg/kg BCA ($p < 0.05$), similar to 50 mg/kg silymarin administration.

Table 1. Effects of BCA (20 mg/kg and 200 mg/kg) on liver and kidney biomarkers in rats.

Biochemical Parameters	Gender	Control	BCA 20 mg/kg	BCA 200 mg/kg
LFT				
ALP (IU/L)	Male	79 ± 1.72	80.15 ± 1.64	81 ± 1.30
	Female	62 ± 1.43	61 ± 2.00	63 ± 1.44
ALT (IU/L)	Male	40 ± 1.14	42.29 ± 1.72	41 ± 1.57
	Female	54 ± 3.26	55 ± 1.25	56 ± 1.43
AST (IU/L)	Male	60 ± 2.36	62.16 ± 2.31	59 ± 1.44
	Female	57 ± 0.21	58 ± 2.67	59 ± 0.00
T. Bilirubin (µmol/L)	Male	3.32 ± 1.10	3.41 ± 1.25	3.53 ± 1.37
	Female	5 ± 2.71	5 ± 1.90	5 ± 2.11
T. Protein (g/L)	Male	52 ± 1.64	49.32 ± 1.52	51.84 ± 2.31
	Female	33 ± 1.64	30 ± 0.63	31 ± 2.08
Albumin (g/L)	Male	34 ± 2.32	33.34 ± 1.47	35.29 ± 1.36
	Female	22 ± 4.22	23 ± 0.18	25 ± 0.79
RFT				
Sodium mmol/L	Male	122 ± 1.23	123.25 ± 1.42	123.12 ± 1.17
	Female	84 ± 1.30	85 ± 1.56	85 ± 1.10
Potassium mmol/L	Male	7 ± 2.39	7.42 ± 1.23	7.89 ± 2.47
	Female	5 ± 0.22	5 ± 1.19	5 ± 1.38
Chloride mmol/L	Male	88 ± 1.13	87.3 ± 1.02	87.22 ± 1.43
	Female	61 ± 2.26	62 ± 0.15	61 ± 2.63
Urea mmol/L	Male	6.21 ± 1.20	6.37 ± 1.54	5.99 ± 1.23
	Female	4 ± 0.02	3 ± 0.92	3 ± 1.29
Creatinine µmol/L	Male	62.27 ± 1.44	61.12 ± 1.33	61.52 ± 1.57
	Female	44 ± 2.27	42 ± 3.30	43 ± 2.14

Data were presented as mean ± S.E.M ($n = 6$). There is no significant difference between different groups ($p < 0.05$).

Table 2. Effect of BCA on body weight, liver weight, and liver index of the rats with TAA-induced liver injury.

Treatment	Initial Body Weight (g)	Final Body Weight (g)	Liver Weight (g)	Liver Index (LW/BW %)
Normal control	255 ± 31.22	473 ± 4.85	13 ± 3.14	3 ± 0.25
TAA control	260 ± 26.61	313 ± 36.12 *	16 ± 2.23 *	5 ± 0.12 *
Silymarin (50 mg/kg) + TAA	257 ± 24.38	485 ± 19.87 **	14 ± 1.48 **	3 ± 0.14 **
BCA 25 mg/kg + TAA	250 ± 4.25	430 ± 13.63 **	15 ± 1.23 **	4 ± 0.52 **
BCA 50 mg/kg + TAA	256 ± 6.72	467 ± 8.74 **	15 ± 1.72 **	4 ± 0.8 **

Data expressed as mean ± SEM ($n = 6$ rats/group). ** $p < 0.05$ compared with TAA control, * $p < 0.05$ compared with normal control.

2.3. Gross and Histopathological Examinations of the Liver

Figure 3 shows the gross and H&E histology of the hepatic sections from all groups. The liver tissues of rats in the normal group (Figure 3A) showed smooth surfaces with no nodules. There was a gross appearance of multiple micronodules in the liver of the TAA control rats, while histopathology revealed fibrous septae, proliferated bile ducts, and inflammatory cells (Figure 3B). In contrast, both silymarin-treated rats and BCA 50 mg/kg-treated rats (Figure 3C,E) had fewer micronodules with fewer septae and more normal hepatocytes. However, BCA 25 mg/kg displayed a lesser improvement in micronodules (Figure 3D) than that of BCA 50 mg/kg or silymarin 50 mg/kg.

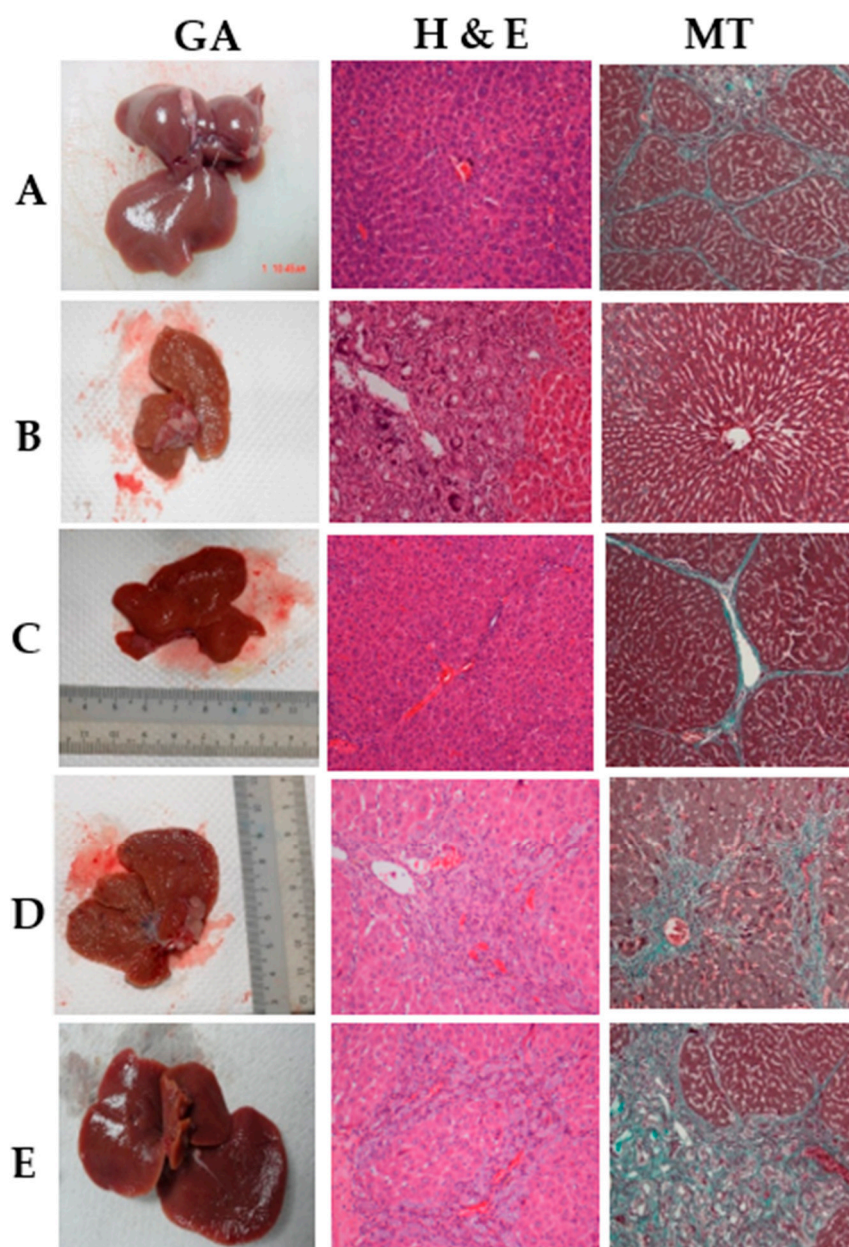


Figure 3. Effects of BCA on thioacetamide-induced liver injury in experimental rats. (A) Normal control group, (B) rats treated with thioacetamide (TTA group), (C) rats treated with thioacetamide + 50 mg/kg silymarin (silymarin group), (D) rats treated with thioacetamide + 25 mg/kg BCA (BCA low dose group), and (E) Rats treated with thioacetamide + 50 mg/kg BCA (BCA high dose group). (GA) Gross morphology, Hematoxylin and Eosin (H&E) stain 20 \times , (MT) Masson trichrome stain 20 \times .

2.4. Masson's Trichrome Staining

The level of liver fibrosis in the normal control, TAA, silymarin, and BCA treatment groups was determined using Masson's trichrome staining. Liver specimens from normal group 1 did not demonstrate any signs of collagen (Figure 3A). Figure 3B illustrates the fibrotic liver of group 2 rats with highly deposited collagen fibers surrounding a congested central vein. No collagen deposits were observed in the livers of the mice in group 3 after silymarin treatment (Figure 3C). In liver sections obtained from rats treated with BCA, collagen fiber deposition gradually decreased at BCA 25 mg/kg. A significant reduction in collagen deposition around the central vein was found with BCA 50 mg/kg treatment of cirrhotic rats (Figure 3E), compared to the TAA control group (Figure 3B).

2.5. Immunohistochemical Stain of Liver Sections

The normal control group's liver cells showed no PCNA discoloration, indicating that there was no cell renewal (Figure 4A). In contrast, hepatic cells in the TAA group showed overexpression of PCNA and had a higher mitotic index, indicating dissemination to the restoration of extensive liver structure injuries (Figure 4B). Compared to the TAA group, the BCA and silymarin groups had lower hepatocyte cell renewal, as indicated by a decrease in PCNA staining appearance and a significant decrease in mitotic index, indicating a lower degree of necrotized hepatocyte propagation and apoptosis (Figure 4C–E, Table 3).

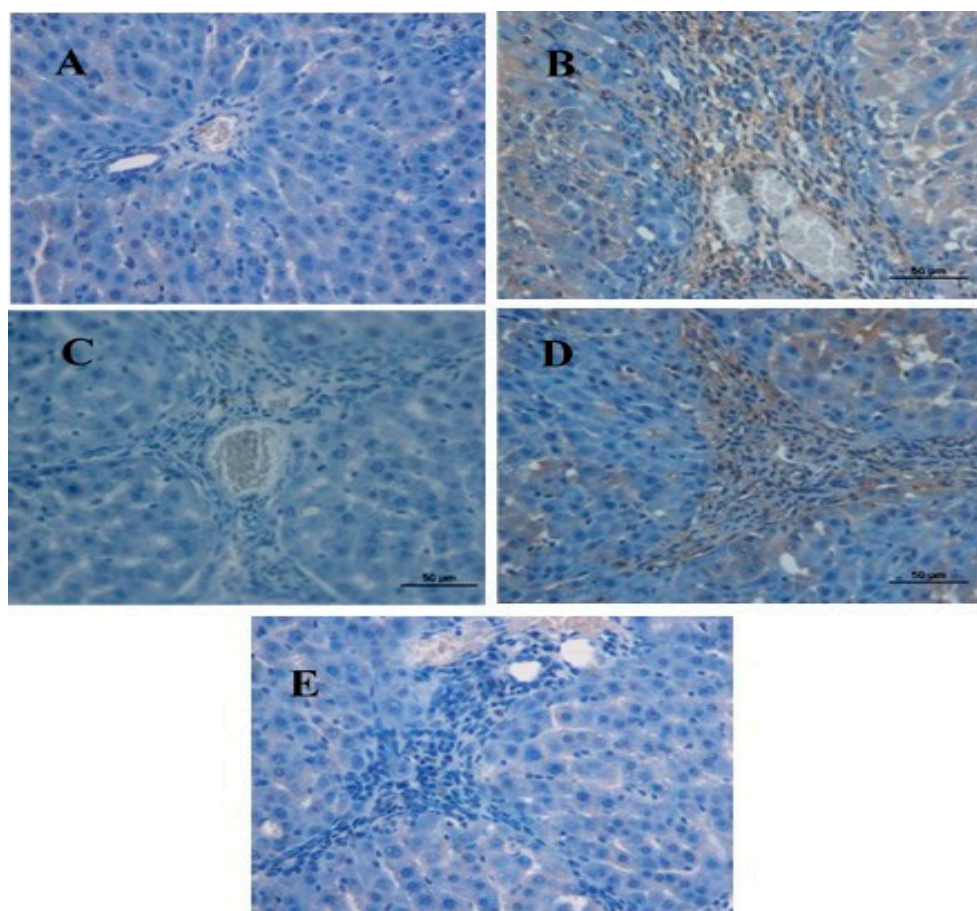


Figure 4. Immunohistochemistry staining for (PCNA) of liver sections sampled from different groups. (A) Normal control group, no PCNA staining (downregulation); (B) rats treated with thioacetamide (TAA group), PCNA expression in hepatocyte nuclei (upregulation); (C) rats treated with thioacetamide + 50 mg/kg silymarin (silymarin group), mild PCNA expression in hepatocytes nuclei (downregulation); (D) rats treated with thioacetamide + 25 mg/kg BCA (BCA low-dose group), mild to moderate expression in PCNA-positive hepatocyte nuclei (downregulation); and (E) rats treated with thioacetamide + 50 mg/kg BCA (BCA high-dose group), mild PCNA expression in hepatocyte nuclei (downregulation) (original magnification $\times 20$). Scale bar 50 μm .

We also studied the expression of alpha-smooth muscle actin (α -SMA) in the livers of the different groups using a specific antibody. The normal control group showed a decrease in α -SMA staining, indicating that no cell regeneration occurred (Figure 5A). The TAA group, on the other hand, had an outstanding α -SMA appearance, indicating up-regulation of this protein with increased hepatocyte fibrosis. The TAA group showed a significant increase in the mitotic figure index, indicating the proliferation of the regeneration of widespread hepatic damage caused by TAA (Figure 5B). Rats treated with 50 mg/kg BCA showed a lower hepatic cell revitalization than that of the TAA control group, as evidenced by α -SMA expression and the mitotic index (Figure 5E, Table 3). Similar results were

observed in the silymarin-treated group. (Figure 5C, Table 3). Rats treated with 25 mg/kg BCA exhibited moderate expression of α -SMA within hepatocytes, as well as a decrease in the mitotic figure index (Figure 5D, Table 3), but less than that of the silymarin-treated group (Figure 5C). These findings indicate that BCA exerts a significant hepatoprotective effect by inhibiting hepatocyte fibrosis and improving propagation.

Table 3. Effect of BCA on the PCNA staining of liver sections and the mitotic index of the liver.

Treatment	Liver PCNA Stain	Liver Mitotic Index
Normal control	0.00	0.00
TAA control	42 \pm 5.62 *	87.21 \pm 3.21 *
Silymarin (50 mg/kg) + TAA	2.15 \pm 0.36 **	33.11 \pm 2.51 **
BCA 25 mg/kg + TAA	3.27 \pm 0.89 **	47.19 \pm 3.43 **
BCA 50 mg/kg + TAA	4.19 \pm 8.74 **	34.13 \pm 2.37 **

Data expressed as mean \pm SEM ($n = 6$ rats/group). ** $p < 0.05$ compared with TAA control, * $p < 0.05$ compared with normal control.

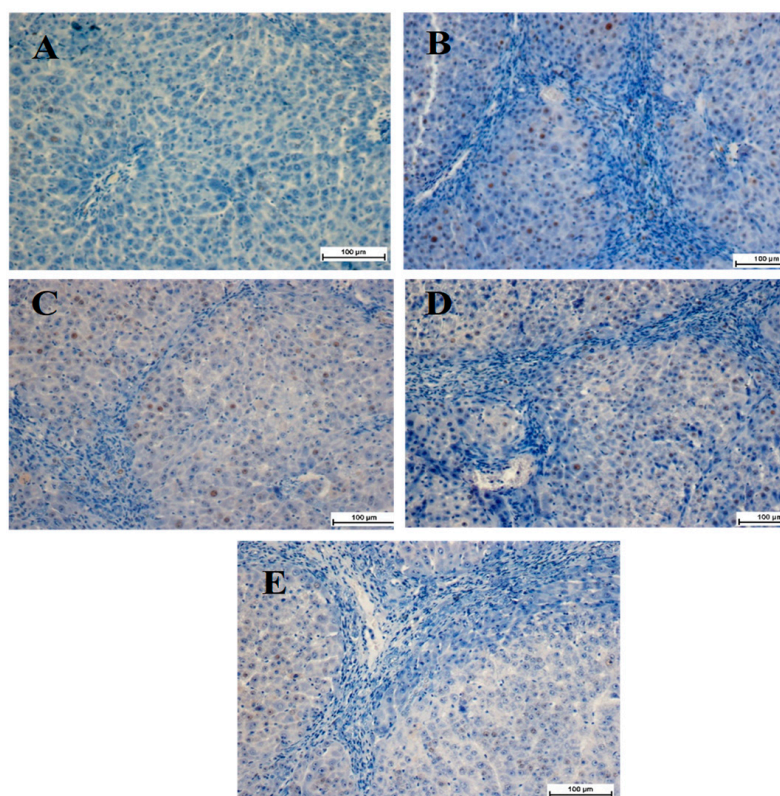


Figure 5. Immunohistochemistry staining of alpha smooth muscle actin (α -SMA) of liver sections samples from the different groups. (A) The livers from the normal control group showed no signs of positive α -SMA staining. (B) The liver from the TAA group showed dense brown staining with highly expressed α -SMA, demonstrating highly activated hepatic stellate cells. (C) Very little positive α -SMA staining in the silymarin-treated liver from the silymarin-treated group. (D) Moderate positive staining of α -SMA in the liver from BCA 25 mg/kg Group. (E) Very few positive α -SMA staining reflecting very few activated hepatic stellate cells in the liver from BCA 50 mg/kg of Group.

2.6. Hepatic Antioxidant Enzymes and Malondialdehyde

As shown in Table 4, TAA treatment significantly increased MDA levels in the liver homogenates of cirrhotic control rats. However, BCA treatment significantly altered TAA's damaging effects. In contrast, BCA treatment significantly elevated collapsed hepatic antioxidants enzyme activity (SOD, CAT, and GPx) induced by TAA.

Table 4. Impact of BCA on the liver MDA level and antioxidant enzymatic activity of the rats with TAA-induced liver injury.

Treatment	MDA nmol/min/mg Protein	SOD U/mg Protein	CAT nmol/min/mg Protein	GPx nmol/min/mg Protein
Normal control	2.13 ± 0.05	26.13 ± 0.61	81.52 ± 2.84	371.42 ± 14.62
TAA control	10.24 ± 0.14 *	15.31 ± 1.82 *	34.71 ± 1.13 *	278.54 ± 7.51 *
Silymarin (50 mg/kg) + TAA	3.01 ± 0.20 **	24.45 ± 1.03 **	84.65 ± 0.24 **	353.77 ± 3.87 **
BCA 25 mg/kg + TAA	1.52 ± 0.12 **	19.25 ± 0.37 **	49.00 ± 4.51 **	310.59 ± 4.52 **
BCA 50 mg/kg + TAA	3.13 ± 1.46 **	24.70 ± 1.65 **	80.85 ± 5.14 **	349.30 ± 0.24 **

Data expressed as mean ± SEM ($n = 6$ rats/group). ** $p < 0.05$ compared with TAA control, * $p < 0.05$ compared with normal control.

2.7. Effect of BCA on Biochemical Markers

Table 5 shows the serum levels of specific liver enzymes that were measured to determine liver function. TAA-intoxicated rats showed significantly elevated levels of liver biomarkers ALP, ALT, AST, and GGT compared to the normal control group. On the other hand, liver function biomarkers were significantly decreased after treatment with both BCA doses and silymarin (50 mg/kg) compared with the TAA control group.

Table 5. Specific liver enzymes measured from the rats' serum at the end of two two-month study.

Treatment	ALP (IU/L)	ALT (IU/L)	AST (IU/L)	GGT (IU/L)
Normal control	55.12 ± 1.44	28.22 ± 1.51	53.32 ± 1.24	3.71 ± 0.23
TAA control	196.84 ± 5.62 *	126.64 ± 2.31 *	163.27 ± 8.91 *	14.64 ± 0.72 *
Silymarin (50 mg/kg) + TAA	57.85 ± 3.21 **	33.56 ± 1.48 **	59.76 ± 4.81 **	5.27 ± 0.28 **
BCA 25 mg/kg + TAA	75.42 ± 1.82 **	70.66 ± 4.23 **	78.83 ± 2.75 **	9.27 ± 1.62 ***
BCA50mg/kg + TAA	55.06 ± 1.52 **	32.43 ± 1.59 **	63.75 ± 3.15 **	3.42 ± 0.41 **

ALP, alkaline phosphatase; ALT, alanine transferase; AST, aspartate transferase; GGT, gamma-glutamyl transaminase. Values are expressed as Mean ± SEM ($n = 6$ rats/group), * $p < 0.05$ compared with Normal, ** $p < 0.05$ compared with TAA group, *** $p < 0.05$ compared to TAA group.

3. Discussion

Liver cirrhosis is the 14th leading cause of death globally, resulting in over a million deaths annually. Survival rates decline significantly when the disease advances to a decompensated stage [19]. This condition results from the liver's wound healing response to repeated insults, leading to resilient and fibrous scar tissue [20]. The development of damage to the parenchyma occurs in various spatial patterns, depending on the causal factor. The key events involve the spread of oxidative reactions, leading to the conversion of inactive HSCs into cells resembling myofibroblasts [21]. Regrettably, there is currently no definitive therapeutic approach available to halt or treat liver fibrosis or its consequences. Therefore, we examined BCA's protective effects on TAA-induced liver cirrhosis.

This study assessed the toxicity of BCA on experimental rats; no morbidity or mortality occurred during the experiment, even at higher concentrations of 200 mg/kg. Several studies involving natural compounds have demonstrated its safety, and no signs of toxicity have been observed [22–24].

In the hepatoprotection experiment, findings demonstrated that the normal control group showed the highest body weight increments. The substantial increase in body weight observed in the normal control group may be indicative of rodent growth trends. In contrast, the rats treated with TAA exhibited the smallest body weight increments, and a significant increase in the liver/body ratio. The aforementioned observations were also documented in numerous studies [25–27].

An elevation in body weight suggests that anabolic processes surpass catabolic processes [10]. A reduction in body weight indicates catabolism persistence. The reduction in body weight following the TAA injection was attributed to the direct toxic effects of

TAA. Furthermore, it is possible to attribute the observed decrease in mean body weight growth in rats treated with TAA to malnutrition caused by a reduction in food absorption. Moreover, the primary factor contributing to the decrease in body weight is likely to be a reduction in adipose tissue and proteins. The potential effect of TAA on protein catabolism and reduction in food consumption during the intoxication period may have resulted in a reduction in body weight. The observed decrease in body weight in rats treated with TAA may be attributed, at least partially, to gastrointestinal toxicity and the subsequent decrease in appetite. This may lead to a reduced food intake. Additionally, it could be attributed to renal injury causing excessive loss of water, salts, and proteins, which results in dehydration and weight loss.

The liver-to-body weight ratio can be used for a more precise assessment of alterations in liver size than relying solely on liver weight, as the latter is heavily influenced by the overall size of the rat [10]. The observed increase in liver size in rats treated with TAA indicates the presence of hepatic lesions and liver damage. The alteration in liver weight under different conditions can be affected by many factors [28], involving a complex interplay of various elements, including the regulation of food behavior and fat storage, control of energy intake and expenditure, and influences from hormones, genetics, and psychology. When the liver undergoes damage, it has the capacity to activate regenerative processes [29], resulting in an increase in liver weight. In the event of significant injury, the liver may undergo hepatic fibrosis and cirrhosis, leading to liver atrophy [30]. Hence, it is not adequate to infer the pathological progression of chronic liver injury solely based on alternations in liver weight [10]. Furthermore, numerous studies have demonstrated that many natural compounds can decrease liver weight or body weight ratios compared with disease model controls [31–33].

The histological assessment demonstrated that BCA protected rats from TAA-induced cirrhosis caused by TAA. A cirrhosis-affected liver shows micronodules and macronodules. The histopathological evaluation of the TAA group revealed significant structural damage, irregular pseudolobules with dense fibrotic septa, and an increase in bile duct growth along with centrilobular and inflammatory cells. The results of silymarin and BCA treatments were positive. BCA has the potential to improve liver regeneration after cirrhosis. The protective impact of BCA protection was dose-dependent, with 50 mg/kg demonstrating a stronger effect. In addition, BCA decreased liver fibrosis, especially at 50 mg/kg. Masson's trichrome staining revealed a slight decrease in collagen synthesis in BCA groups. No substantial collagen accumulation was detected in healthy livers. The cells' cytoplasm exhibited transparency, along the expanded central veins. TAA administration resulted in liver cirrhosis, which led to significant fibrosis. This fibrosis was particularly pronounced around the bile ducts, where there was a substantial presence of dense fibrous septa and a large accumulation of collagen fibers. These fibers exhibited deformed nuclei and extensively vacuolated cytoplasm. Silymarin, the conventional medication, decreased collagen accumulation while the cellular structure remained intact. BCA displayed a considerable level of collagen fiber deposition, particularly at 50 mg/kg. Numerous studies have shown a reduction in collagen fibers by using natural compounds against TAA-induced liver cirrhosis, which agrees with the current study results [34–36].

Proliferating cell nuclear antigen (PCNA) functions as an adjunct protein to DNA polymerase, and its expression is upregulated during the S phase of mitosis compared to DNA replication [26]. Studies have shown that TAA-induced liver injury stimulates hepatocyte proliferation as a compensatory strategy for repairing liver tissue [37–39]. Conversely, hepatocyte proliferation decreases upon treatment with hepatoprotective medications [27,28]. Our results corroborate those of previous studies that reported the downregulation of PCNA in the hepatocytes of rats injected with TAA after treatment with natural compounds [40,41].

In the cirrhosis control group, TAA caused the production of reactive oxygen species (ROS), leading to the stimulation of HSCs, a major factor for the ECM in chronic liver cirrhosis and the upregulation of transforming growth factor-beta 1 (TGF- β 1) and alpha-smooth

muscle actin (α -SMA). The initiation of HSC involves cell propagation, and upgradation of ECM production, and the occurrence of α -SMA in myofibroblasts. The results of the current study revealed that BCA treatment caused downregulation of α -SMA compared to the cirrhosis control group, which showed significant upregulation of α -SMA. BCA treatment significantly reduced HSC activation by decreasing ROS production. Similar findings have been reported regarding the efficacy of BCA in reducing α -SMA expression in carbon tetrachloride (CCl₄)-induced liver cirrhosis [42].

The primary step in TAA hepatotoxicity is oxidative stress caused by free radicals, which contributes to fibrosis [17]. This was confirmed by the increased MDA levels and suppressed levels of the endogenous antioxidant enzymes SOD, CAT, and GPx. Flavonoids are powerful molecules that donate hydrogen atoms from aromatic hydroxyl groups to free radicals. This resulted in the formation of a stable phenolic radical. Furthermore, their amphiphilicity improves their ability to trap chain-initiating radicals at the membrane interface, thereby preventing radical chain reactions [43]. Treatment with BCA remarkably elevated the concentrations of SOD, CAT, and GPx, defending the liver from free radical harm compared to the hepatotoxic group. Hence, the present findings strongly suggest that BCA's hepatoprotective action might be due to its antioxidant effects.

Alkaline phosphatase (ALP), alanine aminotransferase (ALT), aspartate aminotransferase (AST), and gamma-glutamyl transaminase (GGT) levels in the serum were significantly increased in the hepatotoxic group. An increase in serum liver biomarker levels is a sign of hepatocellular damage. In groups treated with BCA, these values markedly decreased, approaching the normal values. Previous reports have provided comparable explanations for serum liver indicators enhancement caused by various natural compounds [44,45]. This hepatoprotective effect may be due to its effects on cell leakage and hepatic cell sheath damage. TAA has been shown to prevent RNA moving from the nucleus to the cytoplasm, causing damage and elevating serum liver biomarkers [46].

4. Materials and Methods

4.1. Drugs and Chemicals

Biochanin A ($\geq 99\%$ purity) was supplied by Sigma-Aldrich (St. Louis, MO, USA). All other drugs were obtained from Merck (Darmstadt, Germany) and Sigma-Aldrich (St. Louis, MO, USA).

4.2. Thioacetamide Preparation

A dose of 200 mg/kg of TAA was given intraperitoneally to the animals three times per week for two months. TAA induces morphological and biological alterations equivalent to those of human liver fibrosis [27].

4.3. Silymarin Preparation

A reference medication, silymarin, was dissolved in 10% Tween 20 and administered by gavage to animals daily at 50 mg/kg for two months [27,38].

4.4. Acute Toxicity Study

It is strongly recommended that natural compounds' safety be evaluated before any biological activity experiments are carried out. Male and female Sprague Dawley rats were obtained from the Animal House Unit, Faculty of Medicine, University of Malaya, Malaysia, ranging in age from 7–8 weeks and weight between 170–190 g. The rats were allowed to freely consume rat pellets and water ad libitum. BCA safe dose was determined in a pilot acute toxicology trial. We divided 18 male rats into three groups: vehicle (10% Tween 20), 20 mg/kg, and 200 mg/kg of BCA. Before being treated, the rats were deprived of food and water for a day. Toxic signs, abnormal behaviors, and mortality were recorded after 30 min, 2, 5, 24, and 48 h. After an overnight fast on day 14, rats were put under general anesthesia with ketamine (30 mg/kg, 100 mg/mL) and xylazine (3 mg/kg, 100 mg/mL) and sacrificed the following day [17]. Standard procedures for measuring blood biochemical parameters

and assessing gross necropsies of the liver and kidneys were followed, as described in a previous study [38].

4.5. Experimental Animals for Cirrhosis

A total of thirty adult male Sprague Dawley rats (7–8 weeks, 250–300 g) were used in this study. All animals were acclimatized for 10 days before the beginning of the experiment. Rats were placed in polypropylene cages under standard conditions (temperature 19–21 °C, and light-controlled (12 h on/12 h off). Throughout the experiment, the rats were provided with pellets and drinking water ad libitum. The experimental protocol was approved by the Animal Ethics Committee of the University of Malaya, Malaysia (Ethics No. PM 27/07/2010/MAA (R)).

4.6. Hepatoprotective Activity

Animals were randomly separated into five groups of six male rats each. Group 1, as the normal control group, was given oral administration of 10% Tween 20 in addition to intraperitoneal injections of distilled water three times a week for 2 months. Groups 2–5 were intraperitoneally injected with 200 mg/kg TAA three times per week for 2 months to induce liver cirrhosis. However, Group 2 orally received 10% Tween 20 (5 mg/kg) for 2 months, and Group 3 was fed silymarin (50 mg/kg) as hepatoprotective medication for 2 months. Groups 4 and 5 were orally administered 25 mg/kg and 50 mg/kg of BCA for 2 months. It should be mentioned that the body weights of rats' in all groups were assessed weekly, and the method of chronic hepatotoxicity induction was consistent with previous publications [11]. At the end of 2 months, all the rats were anesthetized by intramuscular injections of 50 mg/kg ketamine mixed with 5 mg/kg xylazine. Blood was collected and used for antioxidant enzyme measurement. The livers were immediately dissected and homogenized. The homogenates were then centrifuged at $3200 \times g$ for 20 min at 4 °C, and the supernatant obtained was used for enzyme assays.

4.7. Body Weight Assessment and Liver Weight Index

The body weight of the animals was measured weekly. The liver weights of rats were measured after sacrifice. The liver index was determined using the following equation: (liver weight/body weight) \times 100.

4.8. Gross and Histopathology Studies

The livers were excised and promptly rinsed in cold phosphate buffer saline, blotted on filter paper, weighed using an electrical digital balance, and carefully inspected for any gross pathological changes. The livers were macroscopically inspected for the occurrence of macronodules in addition to micronodules, followed by fixing the liver specimens in 10% formalin solution mixed with phosphate-buffered saline (pH 7.2). One day post-fixation, the liver tissues cassettes were handled in a tissue processing machine and then embedded and sectioned at 5 μ m thickness. Sections were preserved in the incubator at 45 °C for 2 days and then divided into two groups. The first group was stained with H&E to study the abnormalities in the liver tissues [27], whereas the second group was stained with Masson's trichrome to investigate the rate of liver fibrosis through collagen fiber staining. The fibrotic areas were estimated using an image-processing program (Adobe Systems Inc., San Jose, CA, USA) and later by Jensen [27].

4.9. Immunohistochemistry

A monoclonal antibody against PCNA and α -SMA (Dako Corp, Carpinteria, CA, USA) and the necessary chemicals (Vectastain ABC peroxidase kit, Vector Laboratories, Newark, NJ, USA) were used to detect the antigen-antibody complex in different groups using the avidin-biotin-peroxidase technique. DAB was used to determine the expression of each marker [47,48].

4.10. Biochemical Parameters for Liver Function

Blood was collected from each rat, and serum was separated to measure liver function enzymes, including ALT, AST, ALP, bilirubin, albumin, and total protein [49–52].

4.11. Liver Tissue Homogenate for Endogenous Enzymes

Liver specimens were washed, soaked in an ice-cold phosphate buffer solution (PBS), pH 7.4, and then homogenized on ice using a Teflon homogenizer (Polytron, Heidolph RZR 1, Meinerzhagen, Germany). In order to remove cell debris, 4500 rpm centrifugation was conducted at 4 °C for 15 min [25]. Superoxide dismutase, catalase, and glutathione peroxidase kits (SOD, CAT, and GPx; Cayman Chemical Company, Ann Arbor, MI, USA) were used to measure the antioxidant activity. A thiobarbituric acid reactive substance (TBARS; Cayman Chemical Company, Ann Arbor, MI, USA) assay kit was used to measure the oxidative stress biomarkers.

4.12. Data Analysis

Statistical analysis was conducted using one-way analysis of variance (ANOVA), followed by Bonferroni's post hoc test (SPSS ver. 20; SPSS Inc., Chicago, IL, USA). The data are presented as mean \pm S.E.M. $p < 0.05$ was considered as statistically significant.

5. Conclusions

The findings from the present study suggest that BCA might be a potential agent protect against toxic liver damage in rats. This is evidenced by the macroscopic appearance, histopathology, immunohistochemistry, and serum biochemical markers. The BCA significantly increased serum CAT, SOD, and GPx activities and significantly diminished hepatic MDA. The BCA effectively prevented the TAA-induced liver cirrhosis by drastically lowering the hepatic PCNA and α -SMA expression. The BCA's ability to avoid hepatocyte propagation, reduce oxidative stress, and reduce lipid peroxidation, along with its antioxidant and free radical scavenging properties, may explain its protective effect against the TAA-induced hepatotoxicity.

Author Contributions: Conceptualization, M.A.A., M.Y.I. and Z.Z.A.; data curation, M.A.A.; formal analysis, M.A.A. and A.S.M.J.; investigation, M.A.A.; methodology, S.H.S., M.A.A. and S.N.J.; software, S.A.H. and Z.Z.A.; writing—original draft, M.A.A. and M.Y.I.; writing—review and editing, M.A.A., M.Y.I. and S.N.J. All authors have read and agreed to the published version of the manuscript.

Funding: This work was supported by a grant from the Biotechnology and Biological Sciences Research Council (BBSRC) for the Institute Strategic Programme Grant Funding BB/J004316/1 to (SNJ). For the purpose of open access, the author has applied a CC-BY public copyright license to any Author Accepted Manuscript version arising from this submission.

Institutional Review Board Statement: The experimental protocol was approved by the Animal Ethics Committee of the University of Malaya, Malaysia, (ethic no. PM 27/07/2010/MAA (R)).

Informed Consent Statement: Not applicable.

Data Availability Statement: Data is contained within the article.

Conflicts of Interest: The authors declare no conflict of interest.

References

1. Antar, S.A.; Ashour, N.A.; Marawan, M.E.; Al-Karmalawy, A.A. Fibrosis: Types, Effects, Markers, Mechanisms for Disease Progression, and Its Relation with Oxidative Stress, Immunity, and Inflammation. *Int. J. Mol. Sci.* **2023**, *24*, 4004.
2. Bachar, S.C.; Bachar, R.; Jannat, K.; Jahan, R.; Rahmatullah, M. Chapter Seven—Hepatoprotective natural products. In *Annual Reports in Medicinal Chemistry*; Sarker, S.D., Nahar, L., Eds.; Academic Press: Cambridge, MA, USA, 2020; pp. 207–249.
3. Aslam, A.; Kwo, P.Y. Epidemiology and Disease Burden of Alcohol Associated Liver Disease. *J. Clin. Exp. Hepatol.* **2023**, *13*, 88–102. [[CrossRef](#)]

4. El-Fadaly, A.A.; Afifi, N.A.; El-Eraky, W.; Salama, A.; Abdelhameed, M.F.; El-Rahman, S.S.A.; Ramadan, A. Fisetin alleviates thioacetamide-induced hepatic fibrosis in rats by inhibiting Wnt/ β -catenin signaling pathway. *Immunopharmacol. Immunotoxicol.* **2022**, *44*, 355–366. [[CrossRef](#)]
5. Alshawsh, M.A.; Abdulla, M.A.; Ismail, S.; Amin, Z.A. Hepatoprotective effects of *Orthosiphon stamineus* extract on thioacetamide-induced liver cirrhosis in rats. *Evid.-Based Complement. Altern. Med.* **2011**, *2011*, 103039. [[CrossRef](#)]
6. Roehlen, N.; Crouch, E.; Baumert, T.F. Liver Fibrosis: Mechanistic Concepts and Therapeutic Perspectives. *Cells* **2020**, *9*, 875.
7. Kisseleva, T.; Brenner, D. Molecular and cellular mechanisms of liver fibrosis and its regression. *Nat. Rev. Gastroenterol. Hepatol.* **2021**, *18*, 151–166. [[CrossRef](#)]
8. El-Gendy, Z.A.; El-Marasy, S.A.; Ahmed, R.F.; El-Batran, S.A.; Abd El-Rahman, S.S.; Ramadan, A.; Youssef, S.A.H. Hepatoprotective effect of *Saccharomyces Cervisiae* Cell Wall Extract against thioacetamide-induced liver fibrosis in rats. *Heliyon* **2021**, *7*, e07159. [[CrossRef](#)]
9. Mousa, A.A.; El-Gansh, H.A.I.; Eldaim, M.A.A.; Mohamed, M.A.E.-G.; Morsi, A.H.; El Sabagh, H.S. Protective effect of *Moringa oleifera* leaves ethanolic extract against thioacetamide-induced hepatotoxicity in rats via modulation of cellular antioxidant, apoptotic and inflammatory markers. *Environ. Sci. Pollut. Res.* **2019**, *26*, 32488–32504. [[CrossRef](#)]
10. Al-Attar, A.M.; Al-Rethea, H.A. Chemoprotective effect of omega-3 fatty acids on thioacetamide induced hepatic fibrosis in male rats. *Saudi J. Biol. Sci.* **2017**, *24*, 956–965.
11. Al-Medhtiy, M.H.; Jabbar, A.A.; Shareef, S.H.; Ibrahim, I.A.A.; Alzahrani, A.R.; Abdulla, M.A. Histopathological evaluation of *Annona muricata* in TAA-induced liver injury in rats. *Processes* **2022**, *10*, 1613. [[CrossRef](#)]
12. Yoshiji, H.; Nagoshi, S.; Akahane, T.; Asaoka, Y.; Ueno, Y.; Ogawa, K.; Kawaguchi, T.; Kurosaki, M.; Sakaida, I.; Shimizu, M. Evidence-based clinical practice guidelines for liver cirrhosis 2020. *J. Gastroenterol.* **2021**, *56*, 593–619. [[CrossRef](#)] [[PubMed](#)]
13. Li, H. Advances in anti hepatic fibrotic therapy with Traditional Chinese Medicine herbal formula. *J. Ethnopharmacol.* **2020**, *251*, 112442. [[CrossRef](#)] [[PubMed](#)]
14. Feng, Z.-J.; Lai, W.-F. Chemical and Biological Properties of Biochanin A and Its Pharmaceutical Applications. *Pharmaceutics* **2023**, *15*, 1105. [[CrossRef](#)]
15. Sundaresan, A.; Radhiga, T.; Deivasigamani, B. Biological activity of biochanin A: A review. *Asian J. Pharm. Pharmacol.* **2018**, *4*, 1–5. [[CrossRef](#)]
16. Yan, J.; Qiu, P.; Zhang, X.; Zhang, Y.; Mi, L.; Peng, C.; Pan, X.; Peng, F. Biochanin A from chinese medicine: An isoflavone with diverse pharmacological properties. *Am. J. Chin. Med.* **2021**, *49*, 1623–1643. [[CrossRef](#)]
17. Breikaa, R.M.; Algandaby, M.M.; El-Demerdash, E.; Abdel-Naim, A.B. Biochanin A protects against acute carbon tetra-chloride-induced hepatotoxicity in rats. *Biosci. Biotechnol. Biochem.* **2013**, *77*, 909–916. [[CrossRef](#)] [[PubMed](#)]
18. Li, P.; Li, M.; Lou, X.; Zhao, B.; Ma, Q.; Bian, Y.; Mi, X. Evaluation of Hypoglycemic Activity and Sub-Acute Toxicity of the Novel Biochanin A–Chromium (III) Complex. *Molecules* **2022**, *27*, 5786. [[CrossRef](#)]
19. Al-Attar, A.M. Hematological and biochemical investigations on the effect of curcumin and Thymoquinone in male mice exposed to Thioacetamide. *Saudi J. Biol. Sci.* **2022**, *29*, 660–665. [[CrossRef](#)]
20. Alkreaty, H.M.; Esmat, A. Lycorine Ameliorates Thioacetamide-Induced Hepatic Fibrosis in Rats: Emphasis on Antioxidant, Anti-Inflammatory, and STAT3 Inhibition Effects. *Pharmaceutics* **2022**, *15*, 369. [[CrossRef](#)]
21. Zargar, S.; Wani, T.A.; Alamro, A.A.; Ganaie, M.A. Amelioration of thioacetamide-induced liver toxicity in Wistar rats by rutin. *Int. J. Immunopathol. Pharmacol.* **2017**, *30*, 207–214. [[CrossRef](#)]
22. Rizzo, C.C.; de Castro, O.; Junior, S.; Sankarankutty, A.K.; Menegazzo, L.A.G.; Granato, R.G. Repercussões sistêmicas da icterícia obstrutiva. *Medicina* **1997**, *30*, 173–182. [[CrossRef](#)]
23. Fändriks, L. Roles of the gut in the metabolic syndrome: An overview. *J. Intern. Med.* **2017**, *281*, 319–336. [[CrossRef](#)] [[PubMed](#)]
24. Court, F.; Wemyss-Holden, S.; Dennison, A.; Maddern, G. The mystery of liver regeneration. *Br. J. Surg.* **2002**, *89*, 1089–1095. [[CrossRef](#)] [[PubMed](#)]
25. Liedtke, C.; Luedde, T.; Sauerbruch, T.; Scholten, D.; Streetz, K.; Tacke, F.; Tolba, R.; Trautwein, C.; Trebicka, J.; Weiskirchen, R. Experimental liver fibrosis research: Update on animal models, legal issues and translational aspects. *Fibrogenesis Tissue Repair* **2013**, *6*, 19. [[CrossRef](#)] [[PubMed](#)]
26. Tsai, M.-Y.; Yang, W.-C.; Lin, C.-F.; Wang, C.-M.; Liu, H.-Y.; Lin, C.-S.; Lin, J.-W.; Lin, W.-L.; Lin, T.-C.; Fan, P.-S.; et al. The Ameliorative Effects of Fucoïdan in Thioacetamide-Induced Liver Injury in Mice. *Molecules* **2021**, *26*, 1937. [[CrossRef](#)]
27. Hu, C.; Zhao, L.; Tao, J.; Li, L. Protective role of melatonin in early-stage and end-stage liver cirrhosis. *J. Cell. Mol. Med.* **2019**, *23*, 7151–7162. [[CrossRef](#)]
28. ElBaset, M.A.; Salem, R.S.; Ayman, F.; Ayman, N.; Shaban, N.; Afifi, S.M.; Esatbeyoglu, T.; Abdelaziz, M.; Elalfy, Z.S. Effect of Empagliflozin on Thioacetamide-Induced Liver Injury in Rats: Role of AMPK/SIRT-1/HIF-1 α Pathway in Halting Liver Fibrosis. *Antioxidants* **2022**, *11*, 2152. [[CrossRef](#)]
29. Aslam, A.; Sheikh, N.; Shahzad, M.; Saeed, G.; Fatima, N.; Akhtar, T. Quercetin ameliorates thioacetamide-induced hepatic fibrosis and oxidative stress by antagonizing the Hedgehog signaling pathway. *J. Cell. Biochem.* **2022**, *123*, 1356–1365. [[CrossRef](#)]
30. El-Marasy, S.A.; El Awdan, S.A.; Abd-Elsalam, R.M. Protective role of chrysin on thioacetamide-induced hepatic encephalopathy in rats. *Chem.-Biol. Interact.* **2019**, *299*, 111–119. [[CrossRef](#)]

31. Shaker, M.E.; Eisa, N.H.; Elgaml, A.; El-Mesery, A.; El-Shafey, M.; El-Dosoky, M.; El-Mowafy, M.; El-Mesery, M. Ingestion of mannose ameliorates thioacetamide-induced intrahepatic oxidative stress, inflammation and fibrosis in rats. *Life Sci.* **2021**, *286*, 120040. [[CrossRef](#)]
32. Hussein, R.M.; Anwar, M.M.; Farghaly, H.S.; Kandeil, M.A. Gallic acid and ferulic acid protect the liver from thioacetamide-induced fibrosis in rats via differential expression of miR-21, miR-30 and miR-200 and impact on TGF- β 1/Smad3 signaling. *Chem.-Biol. Interact.* **2020**, *324*, 109098. [[CrossRef](#)] [[PubMed](#)]
33. Zaghoul, R.A.; Zaghoul, A.M.; El-Kashef, D.H. Hepatoprotective effect of Baicalin against thioacetamide-induced cirrhosis in rats: Targeting NOX4/NF- κ B/NLRP3 inflammasome signaling pathways. *Life Sci.* **2022**, *295*, 120410. [[CrossRef](#)] [[PubMed](#)]
34. El-Maadawy, W.H.; Seif el-Din, S.H.; Ezzat, S.M.; Hammam, O.A.; Safar, M.M.; Saleh, S.; El-Lakkany, N.M. Rutin Ameliorates Hepatic Fibrosis via Targeting Hepatic Stellate Cells' Activation, Proliferation and Apoptosis. *J. Herbs Spices Med. Plants* **2021**, *27*, 322–341. [[CrossRef](#)]
35. El-Lakkany, N.M.; El-Maadawy, W.H.; El-Din, S.H.S.; Saleh, S.; Safar, M.M.; Ezzat, S.M.; Mohamed, S.H.; Botros, S.S.; Demerdash, Z.; Hammam, O.A. Antifibrotic effects of gallic acid on hepatic stellate cells: In vitro and in vivo mechanistic study. *J. Tradit. Complement. Med.* **2019**, *9*, 45–53. [[CrossRef](#)]
36. Elnarawy, A.A.; Nashy, A.E.; Abozaid, A.M.; Komber, I.F.; Elweshahy, R.H.; Abdelrahman, R.S. Vinpocetine attenuates thioacetamide-induced liver fibrosis in rats. *Hum. Exp. Toxicol.* **2021**, *40*, 355–368. [[CrossRef](#)]
37. Algandaby, M.M. Antifibrotic effects of crocin on thioacetamide-induced liver fibrosis in mice. *Saudi J. Biol. Sci.* **2018**, *25*, 747–754. [[CrossRef](#)]
38. Ezhilarasan, D. Molecular mechanisms in thioacetamide-induced acute and chronic liver injury models. *Environ. Toxicol. Pharmacol.* **2023**, *99*, 104093. [[CrossRef](#)]
39. Li, S.; Hong, M.; Tan, H.-Y.; Wang, N.; Feng, Y. Insights into the Role and Interdependence of Oxidative Stress and Inflammation in Liver Diseases. *Oxidative Med. Cell. Longev.* **2016**, *2016*, 4234061. [[CrossRef](#)]
40. Li, S.; Tan, H.Y.; Wang, N.; Cheung, F.; Hong, M.; Feng, Y. The potential and action mechanism of polyphenols in the treatment of liver diseases. *Oxidative Med. Cell. Longev.* **2018**, *2018*, 8394818. [[CrossRef](#)]
41. Radwan, A.M.; Fatoh, S.A.; Massoud, A.; Tousson, E. Effectiveness of curcumin nanoparticles in rat liver fibrosis caused by thioacetamide. *Environ. Toxicol.* **2023**, online ahead of print. [[CrossRef](#)]
42. Munteanu, I.G.; Apetrei, C. Analytical Methods Used in Determining Antioxidant Activity: A Review. *Int. J. Mol. Sci.* **2021**, *22*, 3380. [[CrossRef](#)]
43. Polimati, H.; Pragada, R.R.; Thuan, N.H.; Tatipamula, V.B. Chapter 8—Hepatoprotective potential of bioflavonoids. In *Studies in Natural Products Chemistry*; ur Atta, R., Ed.; Elsevier: Amsterdam, The Netherlands, 2022; pp. 259–285.
44. Yahya, S.; Shalaby, R.; Mannaa, F.A.; Abdel-Wahhab, K.G.; Mohamed, N.R.; Shabana, M.; Elwakeel, S.H. Hepatoprotective effects of chitosan on thioacetamide induced liver toxicity in male albino rats. *Biointerface Res. Appl. Chem* **2021**, *11*, 14490–14505.
45. Ibrahim, S.A.; Mohamed, M.Z.; El-Tahawy, N.F.; Abdelrahman, A.M. Antifibrotic effects of bezafibrate and pioglitazone against thioacetamide-induced liver fibrosis in albino rats. *Can. J. Physiol. Pharmacol.* **2021**, *99*, 313–320. [[CrossRef](#)]
46. Thilagavathi, R.; Begum, S.S.; Varatharaj, S.D.; Balasubramaniam, A.k.; George, J.S.; Selvam, C. Recent insights into the hepatoprotective potential of medicinal plants and plant-derived compounds. *Phytother. Res.* **2023**, *37*, 2102–2118. [[CrossRef](#)] [[PubMed](#)]
47. Salama, S.; Kue, C.S.; Mohamad, H.; Omer, F.; Ibrahim, M.Y.; Abdulla, M.; Ali, H.; Mariod, A.; Jayash, S.N. Hepatoprotective potential of a novel quinazoline derivative in thioacetamide-induced liver toxicity. *Front. Pharmacol.* **2022**, *13*, 943340. [[CrossRef](#)] [[PubMed](#)]
48. Abood, W.N.; Bradosty, S.W.; Shaikh, F.K.; Salehen, N.A.; Farghadani, R.; Agha, N.F.S.; Al-Medhtiy, M.H.; Kamil, T.D.A.; Agha, A.S.; Abdulla, M.A. Garcinia mangostana peel extracts exhibit hepatoprotective activity against thioacetamide-induced liver cirrhosis in rats. *J. Funct. Foods* **2020**, *74*, 104200. [[CrossRef](#)]
49. Ibrahim, M.Y.; Hashim, N.M.; Mohan, S.; Abdulla, M.A.; Abdelwahab, S.I.; Arbab, I.A.; Yahayu, M.; Ali, L.Z.; Ishag, O.E. α -Mangostin from *Cratoxylum arborescens*: An in vitro and in vivo toxicological evaluation. *Arab. J. Chem.* **2015**, *8*, 129–137. [[CrossRef](#)]
50. Ibrahim, M.Y.; Hashim, N.M.; Omer, F.A.A.; Abubakar, M.S.; Mohammed, H.A.; Salama, S.M.; Jayash, S.N. Potential Antitumor Effect of α -Mangostin against Rat Mammary Gland Tumors Induced by LA7 Cells. *Int. J. Mol. Sci.* **2023**, *24*, 10283. [[CrossRef](#)]
51. Jabbar, A.A.; Alamri, Z.Z.; Abdulla, M.A.; Salehen, N.A.; Al Sinawi, Z.S.A.; Alfaifi, S.M. Hepatoprotective effects of *Gynura procumbens* against thioacetamide-induced cirrhosis in rats: Targeting inflammatory and oxidative stress signalling pathways. *Heliyon* **2023**, *9*, e19418. [[CrossRef](#)]
52. Shareef, S.H.; Juma, A.S.; Agha, D.N.; Alzahrani, A.R.; Ibrahim, I.A.A.; Abdulla, M.A. Hepatoprotective Effect of Alpinetin on Thioacetamide-Induced Liver Fibrosis in Sprague Dawley Rat. *Appl. Sci.* **2023**, *13*, 5243. [[CrossRef](#)]

Disclaimer/Publisher's Note: The statements, opinions and data contained in all publications are solely those of the individual author(s) and contributor(s) and not of MDPI and/or the editor(s). MDPI and/or the editor(s) disclaim responsibility for any injury to people or property resulting from any ideas, methods, instructions or products referred to in the content.