



THE UNIVERSITY *of* EDINBURGH

Edinburgh Research Explorer

The Boston criteria version 2.0 for cerebral amyloid angiopathy

Citation for published version:

Charidimou, A, Boulouis, G, Frosch, MP, Baron, J, Pasi, M, Albuher, JF, Banerjee, G, Barbato, C, Bonneville, F, Brandner, S, Calviere, L, Caparros, F, Casolla, B, Cordonnier, C, Delisle, M, Deramecourt, V, Dichgans, M, Gokcal, E, Herms, J, Hernandez-guillamon, M, Jäger, HR, Jaunmuktane, Z, Linn, J, Martinez-ramirez, S, Martínez-sáez, E, Mawrin, C, Montaner, J, Moulin, S, Olivot, J, Piazza, F, Puy, L, Raposo, N, Rodrigues, MA, Roeber, S, Romero, JR, Samarasekera, N, Schneider, JA, Schreiber, S, Schreiber, F, Schwall, C, Smith, C, Szalardy, L, Varlet, P, Viguier, A, Wardlaw, JM, Warren, A, Wollenweber, FA, Zedde, M, Van Buchem, MA, Gurol, ME, Viswanathan, A, Al-shahi Salman, R, Smith, EE, Werring, DJ & Greenberg, SM 2022, 'The Boston criteria version 2.0 for cerebral amyloid angiopathy: a multicentre, retrospective, MRI–neuropathology diagnostic accuracy study', *The Lancet Neurology*, vol. 21, no. 8, pp. 714-725. [https://doi.org/10.1016/S1474-4422\(22\)00208-3](https://doi.org/10.1016/S1474-4422(22)00208-3)

Digital Object Identifier (DOI):

[10.1016/S1474-4422\(22\)00208-3](https://doi.org/10.1016/S1474-4422(22)00208-3)

Link:

[Link to publication record in Edinburgh Research Explorer](#)

Document Version:

Peer reviewed version

Published In:

The Lancet Neurology

General rights

Copyright for the publications made accessible via the Edinburgh Research Explorer is retained by the author(s) and / or other copyright owners and it is a condition of accessing these publications that users recognise and abide by the legal requirements associated with these rights.

Take down policy

The University of Edinburgh has made every reasonable effort to ensure that Edinburgh Research Explorer content complies with UK legislation. If you believe that the public display of this file breaches copyright please contact openaccess@ed.ac.uk providing details, and we will remove access to the work immediately and investigate your claim.



Supplementary material contents

Supplementary Table 1	Page 2
Supplementary Table 2	Page 4
Supplementary Table 3	Page 5
Supplementary Methods	Page 6-9
Supplementary Figure 1	Page 10
Supplementary Figure 2	Page 11-13
Supplementary References	Page 14-15

Supplementary material

Supplementary Table 1. Characteristics of patients in the geographical external validation constituent medical centers

Centres	Univ of Milano-Bicocca, IRCCS Reggio Emilia (n=15)	Univ of Edinburgh (n=17)	Sainte-Anne Hospital (n=8)	Univ Hospital Munich (n=11)	Vall d'Hebron (n=6)	Univ Lille (n=16)	German Center Magdeburg (n=3)	Univ College London (n=28)	Toulouse Hospital (n=19)
Age, years	68 (63-77)	81 (77-85)	62 (60-71)	70 (66-73)	75 (72-82)	69 (65-82)	75 (62-83)	68 (61-75)	65 (58-67)
Sex, men	7 (47%)	9 (53%)	5 (63%)	5 (46%)	3 (50%)	5 (31%)	1 (33%)	15 (54%)	11 (58%)
Race	15 White	17 White	8 White	11 White	6 White	16 unknown	3 White	12 White 3 "other ethnic background" (treat as unknown) Others unknown	19 White
Hypertension	5 (33%)	11 (65%)	3 (38%)	3 (28%)	6 (100%)	8 (50%)	2 (67%)	19 (68%)	3 (16%)
ICH presentation	12 (80%)	15 (88%)	7 (88%)	10 (91%)	2 (33%)	11 (69%)	3 (100%)	18 (64%)	16 (84%)
T2*GRE MRI	14 (93%)	17 (100%)	8 (100%)	10 (91%)	6 (100%)	16 (100%)	3 (100%)	10 (36%)	19 (100%)
SWI MRI	1 (7%)	0	0	1 (9%)	0	0	0	18 (64%)	0
Autopsy	1 (7%)	17 (100%)	1 (13%)	0	5 (83%)	16 (100%)	0	0	2 (11%)
Biopsy	14 (93%)	0	0	5 (46%)	0	0	0	19 (68%)	3 (16%)
Haematoma evacuation	0	0	7 (88%)	6 (55%)	1 (17%)	0	3 (100%)	9 (32%)	14 (74%)

Values are presented as median (interquartile range) for continuous variables and (% total) for categorical variables.
See authors affiliations for full hospital listings.
Abbreviations: ICH intracerebral hemorrhage, GRE gradient-recalled echo, SWI susceptibility-weighted imaging

Supplementary Table 2 Criteria performance for probable CAA diagnosis (vs possible + non-CAA) according to MRI diagnostic markers combination in the derivation cohort

A. ICH clinical presentations (n=77)

+number strictly lobar ICH	+number strictly lobar CMB	+number cSS foci	+ severe CSO-PVS (y/n)	+ WMH-MS (y/n)	Sum	Sensitivity	Specificity	AUC (95% CI)
X	X	X			2 or more	76.7%	76.5%	0.78 (0.65-0.88)
X	X	X	X			85%	70.6%	0.78 (0.66-0.90)
X	X	X		X		86.7%	76.5%	0.82 (0.70-0.93)
X	X	X	X	X		86.7%	70.6%	0.79 (0.67-0.88)

B. Non-ICH clinical presentation (n=82)

+number strictly lobar CMB	+ cSS foci y/n number	+ severe CSO-PVS (y/n)	+ WMH-MS (y/n)	Sum	Sensitivity	Specificity	AUC (95% CI)
X	X			2 or more	44.7%	91.4%	0.68 (0.60-0.77)
X	X				48.9%	94.3%	0.72 (0.63-0.80)
X	X	X			59.6%	91.4%	0.76 (0.67-0.84)
X	X		X		53.2%	91.4%	0.72 (0.64-0.81)
X	X	X	X		59.6%	91.4%	0.75 (0.67-0.84)

Abbreviations: ICH intracerebral hemorrhage, CMB cerebral microbleeds, cSS cortical superficial siderosis, CSO-PVS perivascular spaces in the centrum semiovale, WMH-MS white matter hyperintensities in a multisport pattern, y/n yes (lesion present)/no (lesion absent), AUC area under the receiver operating characteristics curve

Supplementary Table 3 Criteria performance for any CAA diagnosis (probable + possible vs non-CAA) according to MRI diagnostic markers combination in the derivation cohort

A. ICH clinical presentations (n=77)

+ strictly lobar ICH	+ strictly lobar CMB	+ cSS foci	+ severe CSO-PVS (y/n)	+ WMH-MS (y/n)	Sum	Sensitivity	Specificity	AUC (95% CI)
X	(X)	(X)	(X)	(X)	1 or more	96.7%	41.2%	0.69 (0.57-0.81)

B. Non-ICH clinical presentation (n=82)

+ strictly lobar CMB	+ cSS foci	+ severe CSO-PVS (y/n)	+ multispot WMH (y/n)	Sum	Sensitivity	Specificity	AUC (95% CI)
X	X						0.75 (0.67-0.84)
X	X	X		1 or more	58.7%	91.4%	0.80 (0.71-0.89)
X	X		X		69.6%	71.4%	0.71 (0.60-0.81)
X	X	X	X		84.8%	65.7%	0.75 (0.66-0.85)

Abbreviations: ICH intracerebral hemorrhage, CMB cerebral microbleeds, cSS cortical superficial siderosis, CSO-PVS perivascular spaces in the centrum semiovale, WMH-MS white matter hyperintensities in a multispot pattern, y/n yes (lesion present)/no (lesion absent), AUC area under the receiver operating characteristics curve

For Supplementary Table 3A, presence of one strictly lobar ICH is itself sufficient for a diagnosis of possible CAA.

Supplementary Methods:

Please access the published study protocol paper for further details:

https://discovery.ucl.ac.uk/id/eprint/10085528/3/Werring_Advancing%20diagnostic%20criteria%20for%20sporadic%20cerebral%20amyloid%20angiopathy_AAM.pdf

or

<https://journals.sagepub.com/doi/abs/10.1177/1747493019855888>

MRI assessment and analysis

Key MRI biomarkers of CAA and small vessel disease were derived from a systematic review of the relevant literature.¹ These included characteristic hemorrhagic MRI biomarkers of CAA² (cerebral microbleeds-CMBs, ICH, cortical superficial siderosis-cSS, as well as non-hemorrhagic (white matter) markers² (white matter hyperintensities-WMH, posterior predominant WMH, WMH spots and MRI-visible perivascular spaces in the centrum semiovale-CSO-EPVS³⁻⁵). All MRI markers will be rated by a trained observer blinded to clinical and pathological information, according to Standards for Reporting Vascular changes on neuroimaging (STRIVE)⁶ where applicable and validated scales and guidelines. Additional trained raters will assess a random sample of the MRI scans (n=100) to generate inter-rater agreement measures.

CMBs presence and number will be evaluated on axial T2*-weighted images using current consensus criteria⁷ and categorized according to a simplified version of the previously validated Microbleeds Anatomic Rating Scale (MARS).⁸ For purposes of statistical analyses, the number of lobar CMBs will be taken into account as a continuous variable as well as categories using cut-points (0, 1, 2-4, ≥ 5 or 5-10 and ≥ 10).⁹ Non-lobar (i.e. deep CMBs) will also be categorized accordingly. ICH will be defined and categorized as lobar or non-lobar according to the simplified The Cerebral Hemorrhage Anatomical Rating Instrument (CHARTS) definitions.¹⁰

cSS will be defined as per recent consensus recommendations¹¹ (curvilinear hypointensities following the cortical surface, distinct from the vessels), and assessed on axial blood-sensitive sequences according to a validated scale: absent, focal (restricted to ≤ 3 sulci) or disseminated (affecting 4 or more sulci).^{12,13} cSS will also be rated for multifocality (i.e. taking into account cSS presence at spatially separate foci in each hemisphere) using another developed and validated protocol as: (a) 0 – none; (b) 1 -1 sulcus or up to 3 immediately adjacent sulci with cSS; or (c) 2 - 2 or more non-adjacent sulci or more than 3 adjacent sulci with cSS. Based on the total score:

0—no cSS, 1—unifocal cSS, while ≥ 2 multifocal cSS.¹⁴ Acute convexity subarachnoid hemorrhage (cSAH) will also be defined and assessed in line with recent consensus recommendations,¹¹ as linear hypointensity in the subarachnoid space affecting one or more cortical sulci on T2*-GRE/SWI sequences with corresponding hyperintensity in the subarachnoid space on T1-weighted or FLAIR images.^{7,13} cSS and acute cSAH are rated as equivalent MRI marker of CAA. They are both superficial cortical hemorrhages that follow the curvilinear shape of the surrounding cerebral gyri—cSAH is the acute form, while cSS is the chronic form, of essentially the same underlying process.¹⁵ In cases where acute cSAH is potentially connected (or in close vicinity) to cSS, they are counted as evidence of two hemorrhagic markers of CAA (e.g. similar to having 2 independent sulci of cSS or 2 lobar CMBs), since the acuity of cSAH provides evidence of dissemination in time (it's a new CAA-related superficial cortical hemorrhage event) compared to the chronic nature of cSS. This is the same rationale for counting single vs. two cSS sulci within the focal cSS category and also using the cSS multifocality scale: to potentially distinguishing cSS related to individual bleeding events originating from one focus or multiple different bleeding foci.

Periventricular and deep WMH will be classified using the 0-3 Fazekas scale on axially oriented FLAIR images.¹⁶ In patients with ICH, the unaffected hemisphere will be scored. In patients with bilateral ICH or significant edema, an estimation will be made, using the non-involved white matter areas. The antero-posterior ratio of WMH lesions' distribution will be computed using a validated approach on FLAIR,¹⁷ using multiplanar reformatting as necessary to provide axial orientation. In this method, WMH in the frontal lobe are evaluated around the frontal horn of the lateral ventricle and WMH in the occipital lobe are evaluated around the occipital horn of the lateral ventricle. For the frontal and occipital lobes, visual scales are separately used to rate WMH surrounding the ventricles (≤ 5 mm from ventricle), within juxtacortical white matter (≤ 5 mm from the cortex) and within the deep white matter (defined as the region between juxtacortical and ventricular areas). Periventricular WMH are graded as 0 (absent), 1 (caps or pencil-thin periventricular lining), 2 (smooth halo or thick lining), and in deep or in juxtacortical white matter as 0 (absent), 1 (punctate or nodular foci), 2 (confluent areas). The overall severity is then calculated separately for the frontal and occipital lobes by adding the scores for these three areas (range 0–6), and then the frontal-occipital (FO) gradient calculated as the WMH score in the frontal lobe minus that in the occipital lobe, ranging –6 to 6 (>0 implies frontal dominance

and <0 implies occipital dominance). As previously shown, using this method, a lower score reflects more posteriorly distributed WMH lesions.¹⁷

Multiple subcortical spots WMH refers to a pattern which appears in the subcortical white matter and corresponds to more than 10 small spots (circular or ovoid) of WMH on FLAIR images.¹⁸ This pattern in the subcortical white matter refers to small circles or spots of WMH (the total number of spots must be higher than 10 to meet this pattern requirement; this cutoff, though arbitrary, was prespecified based on its possible clinical usefulness as an easily identified pattern, see Supplementary Figure 1 below).¹⁸ When evaluating MRI scans for the presence of multiple subcortical WMH spots pattern, the following aspects should be taken into account:

- Assessment should be made on FLAIR images, covering the whole brain. All the slices, and both hemispheres, should be evaluated.

- Foci should only be counted if restricted to subcortical areas and isolated, that is, not confluent or continuous to periventricular foci.

- WMH foci related to acute or chronic infarcts, lacunes, PVS, or ICH should not be counted.

- There are no established size limits for subcortical WMH foci, but they should be visible without requiring extensive windowing.

- More than 10 subcortical WMH foci are required to establish the pattern.

- Cases with large confluent periventricular WMH foci can be challenging. In this context, raters should carefully assess subcortical areas in the high convexity and temporal regions for small, isolated spots.

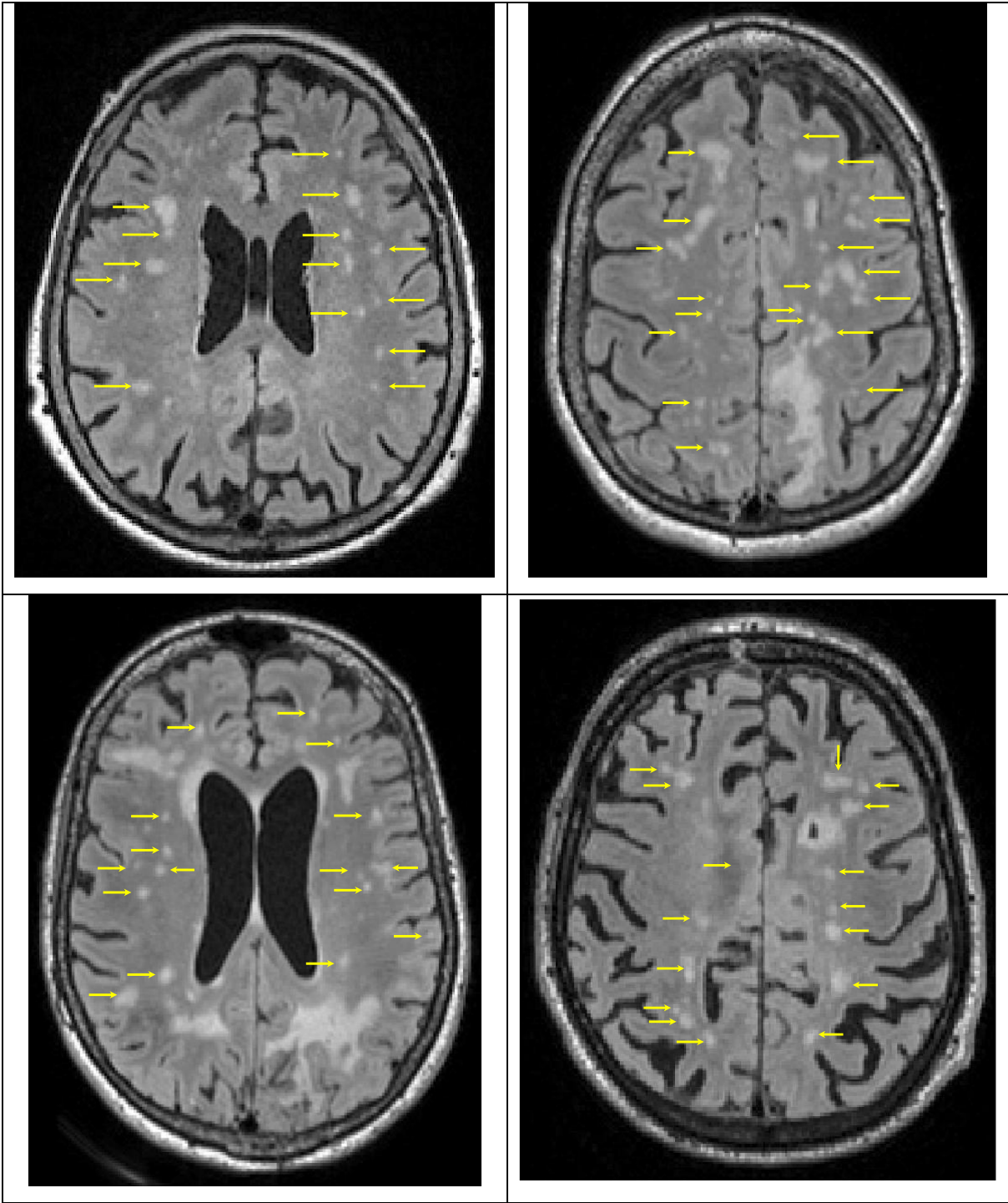
- Small round or ovoid spots in the subcortical areas in the high convexity and temporal regions should be counted if they appear isolated from each other, i.e. separated by normal parenchyma. For small, isolated spots that are often adjacent to each other giving the impression of confluence, they rater might try windowing the image/changing magnification to identify if spots in close proximity are in fact separate foci. When this is not possible or is still unclear that area of small confluent spots should be counted as a single lesion. When there is question re confluence of certain spots, the rater might first try to assess whether the pattern of 10 or more spots is fulfilled based on the presence of less ambiguous and isolated lesions as defined above. In this case, individual decisions regarding ambiguous confluence lesions will likely not influence the identification for the pattern since the number criterion is already fulfilled.

-When 10 or 11 foci are identified, that is, when the number of foci is within or extending slightly beyond the threshold, the overall pattern, rather than the raw number, should be considered.

MRI-visible PVS will be rated on axial T2-weighted MR images, in the basal ganglia (BG) and CSO, using a validated 4-point visual rating scale (0=no PVS, 1=<10 PVS, 2=11-20 PVS, 3=21-40 PVS and 4=>40 PVS).^{5,19-22} The numbers refer to PVS on one side of the brain: after reviewing all relevant slices for the anatomical area being assessed, the count for the slice and side with the highest number of PVS is recorded. The assessment of PVS may be influenced by the presence of confluent WMH; in such cases estimation is made for the PVS rating category, using the non-involved white matter region, and cortical gray matter according to the rating scale used. In cases of large lobar or deep ICH, PVS are assessed in the contralateral hemisphere, an estimation of the closest category ipsilateral to the lesion is made, and the highest severity is recorded. We pre-specified a dichotomised classification of PVS degree as high (score >2) or low (score ≤2). This definition is in line with the PVS burden used in previous studies and found to relate with different vascular risk factors and imaging markers of small vessel disease,^{21,22} in particular the association between CSO-EPVS and CAA.^{5,22,23} For a visual guide on PVS rating, please see:

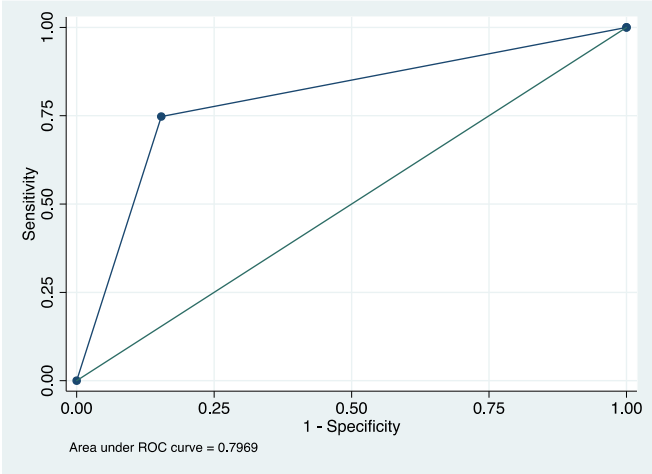
<https://www.ed.ac.uk/files/imports/fileManager/epvs-rating-scale-user-guide.pdf>

Supplementary Figure I. Boston Criteria v2.0 multispot white matter hyperintensity pattern examples, defined as greater than 10 T2/FLAIR small circular or ovoid hyperintense lesions in the subcortical white matter of both hemispheres. Yellow arrows points to WM spots that should fulfill the definitions and should be counted for the pattern. Each arrow represent a lesion that should be counted as one.

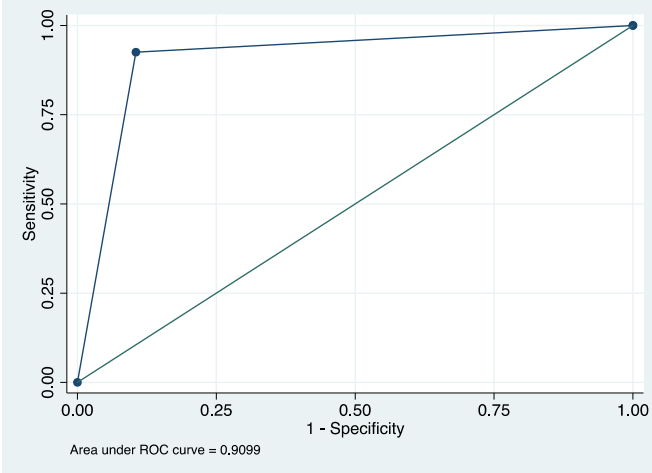


Supplementary Figure 2. ROC curves for diagnostic accuracy of Boston criteria v2.0 (probable vs. non probable CAA) across the derivation cohort, validation cohorts and the final whole sample analyses.

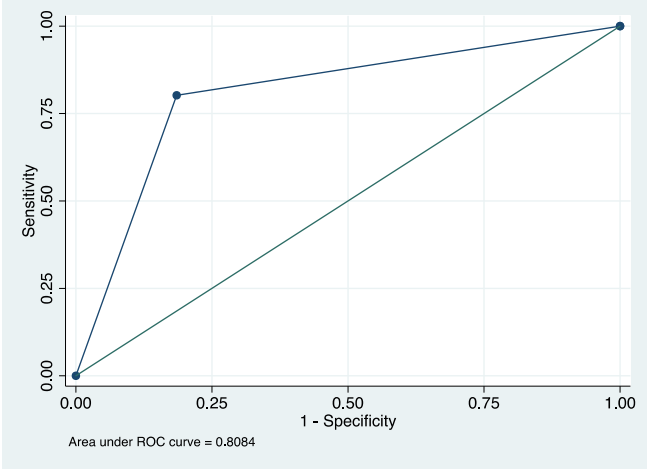
A. Derivation cohort



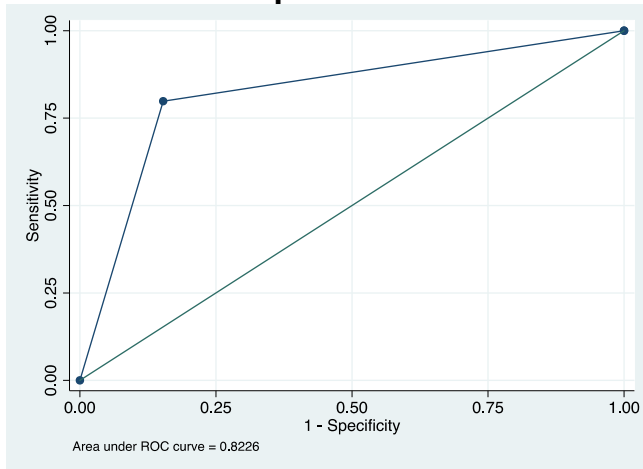
B. Temporal external validation



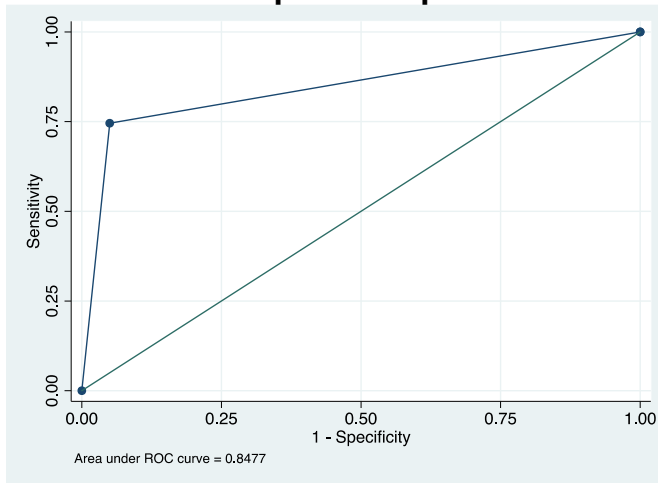
C. Geographical external validation



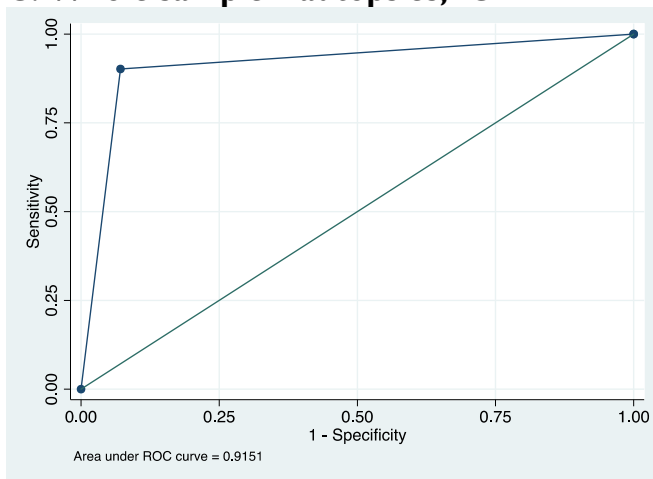
D. Whole sample



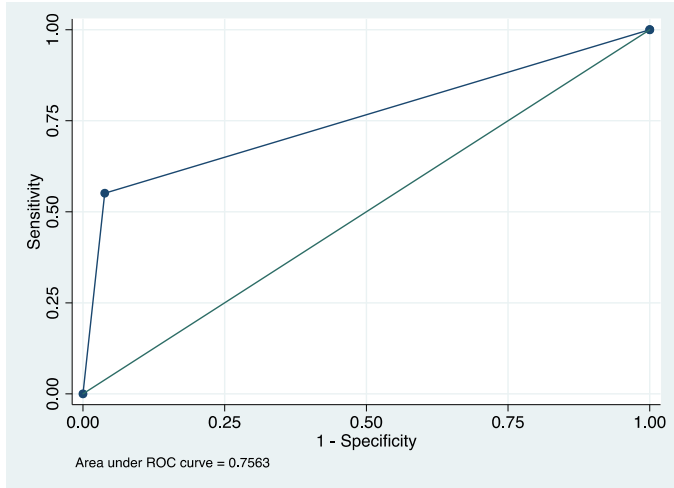
E. Whole sample – autopsies



C. Whole sample – autopsies, ICH



D. Whole sample – autopsies, non-ICH



Supplementary References:

1. Charidimou A, Boulouis G, Gurol ME, et al. Emerging concepts in sporadic cerebral amyloid angiopathy. *Brain* 2017; **140**(7): 1829-50.
2. Greenberg SM, Al-Shahi Salman R, Biessels GJ, et al. Outcome markers for clinical trials in cerebral amyloid angiopathy. *Lancet Neurol* 2014; **13**(4): 419-28.
3. Martinez-Ramirez S, Pontes-Neto OM, Dumas AP, et al. Topography of dilated perivascular spaces in subjects from a memory clinic cohort. *Neurology* 2013.
4. Charidimou A, Meegahage R, Fox Z, et al. Enlarged perivascular spaces as a marker of underlying arteriopathy in intracerebral haemorrhage: a multicentre MRI cohort study. *J Neurol Neurosurg Psychiatry* 2013.
5. Charidimou A, Jaunmuktane Z, Baron JC, et al. White matter perivascular spaces: An MRI marker in pathology-proven cerebral amyloid angiopathy? *Neurology* 2014; **82**(1): 57-62.
6. Wardlaw JM, Smith EE, Biessels GJ, et al. Neuroimaging standards for research into small vessel disease and its contribution to ageing and neurodegeneration. *Lancet Neurol* 2013; **12**(8): 822-38.
7. Greenberg SM, Vernooij MW, Cordonnier C, et al. Cerebral microbleeds: a guide to detection and interpretation. *Lancet Neurol* 2009; **8**(2): 165-74.
8. Gregoire SM, Chaudhary UJ, Brown MM, et al. The Microbleed Anatomical Rating Scale (MARS): reliability of a tool to map brain microbleeds. *Neurology* 2009; **73**(21): 1759-66.
9. Biffi A, Halpin A, Towfighi A, et al. Aspirin and recurrent intracerebral hemorrhage in cerebral amyloid angiopathy. *Neurology* 2010; **75**(8): 693-8.
10. Charidimou A, Schmitt A, Wilson D, et al. The Cerebral Haemorrhage Anatomical Rating in Instrument (CHARTS): Development and assessment of reliability. *J Neurol Sci* 2017; **372**: 178-83.
11. Charidimou A, Linn J, Vernooij MW, et al. Cortical superficial siderosis: detection and clinical significance in cerebral amyloid angiopathy and related conditions. *Brain* 2015; **138**(Pt 8): 2126-39.
12. Linn J, Halpin A, Demaerel P, et al. Prevalence of superficial siderosis in patients with cerebral amyloid angiopathy. *Neurology* 2010; **74**(17): 1346-50.
13. Charidimou A, Jager RH, Fox Z, et al. Prevalence and mechanisms of cortical superficial siderosis in cerebral amyloid angiopathy. *Neurology* 2013; **81**(7): 626-32.
14. Charidimou A, Boulouis G, Roongpiboonsopit D, et al. Cortical superficial siderosis multifocality in cerebral amyloid angiopathy: A prospective study. *Neurology* 2017; **89**(21): 2128-35.
15. Beitzke M, Enzinger C, Wunsch G, Asslaber M, Gattringer T, Fazekas F. Contribution of convexal subarachnoid hemorrhage to disease progression in cerebral amyloid angiopathy. *Stroke* 2015; **46**(6): 1533-40.
16. Fazekas F, Chawluk JB, Alavi A, Hurtig HI, Zimmerman RA. MR signal abnormalities at 1.5 T in Alzheimer's dementia and normal aging. *AJR American journal of roentgenology* 1987; **149**(2): 351-6.
17. Zhu YC, Chabriat H, Godin O, et al. Distribution of white matter hyperintensity in cerebral hemorrhage and healthy aging. *Journal of neurology* 2012; **259**(3): 530-6.
18. Charidimou A, Boulouis G, Haley K, et al. White matter hyperintensity patterns in cerebral amyloid angiopathy and hypertensive arteriopathy. *Neurology* 2016; **86**(6): 505-11.
19. Doubal FN, MacLulich AM, Ferguson KJ, Dennis MS, Wardlaw JM. Enlarged perivascular spaces on MRI are a feature of cerebral small vessel disease. *Stroke* 2010; **41**(3): 450-4.

20. Maclullich AM, Wardlaw JM, Ferguson KJ, Starr JM, Seckl JR, Deary IJ. Enlarged perivascular spaces are associated with cognitive function in healthy elderly men. *J Neurol Neurosurg Psychiatry* 2004; **75**(11): 1519-23.
21. Zhu YC, Tzourio C, Soumare A, Mazoyer B, Dufouil C, Chabriat H. Severity of dilated Virchow-Robin spaces is associated with age, blood pressure, and MRI markers of small vessel disease: a population-based study. *Stroke* 2010; **41**(11): 2483-90.
22. Martinez-Ramirez S, Pontes-Neto OM, Dumas AP, et al. Topography of dilated perivascular spaces in subjects from a memory clinic cohort. *Neurology* 2013; **80**(17): 1551-6.
23. Charidimou A, Meegahage R, Fox Z, et al. Enlarged perivascular spaces as a marker of underlying arteriopathy in intracerebral haemorrhage: a multicentre MRI cohort study. *Journal of neurology, neurosurgery, and psychiatry* 2013; **84**(6): 624-9.