



THE UNIVERSITY *of* EDINBURGH

Edinburgh Research Explorer

## Effects of Cilostazol and Isosorbide Mononitrate on Cerebral Hemodynamics in the LACI-1 Randomized Controlled Trial

### Citation for published version:

Blair, GW, Janssen, E, Stringer, MS, Thrippleton, MJ, Chappell, F, Shi, Y, Hamilton, I, Flaherty, K, Appleton, JP, Doubal, FN, Bath, PM & Wardlaw, JM 2021, 'Effects of Cilostazol and Isosorbide Mononitrate on Cerebral Hemodynamics in the LACI-1 Randomized Controlled Trial', *Stroke*.  
<https://doi.org/10.1161/STROKEAHA.121.034866>

### Digital Object Identifier (DOI):

[10.1161/STROKEAHA.121.034866](https://doi.org/10.1161/STROKEAHA.121.034866)

### Link:

[Link to publication record in Edinburgh Research Explorer](#)

### Document Version:

Publisher's PDF, also known as Version of record

### Published In:

Stroke

### General rights

Copyright for the publications made accessible via the Edinburgh Research Explorer is retained by the author(s) and / or other copyright owners and it is a condition of accessing these publications that users recognise and abide by the legal requirements associated with these rights.

### Take down policy

The University of Edinburgh has made every reasonable effort to ensure that Edinburgh Research Explorer content complies with UK legislation. If you believe that the public display of this file breaches copyright please contact [openaccess@ed.ac.uk](mailto:openaccess@ed.ac.uk) providing details, and we will remove access to the work immediately and investigate your claim.





# Effects of Cilostazol and Isosorbide Mononitrate on Cerebral Hemodynamics in the LACI-1 Randomized Controlled Trial

Gordon W. Blair<sup>1</sup>, MRCP; Esther Janssen, MSc; Michael S. Stringer, PhD; Michael J. Thrippleton<sup>1</sup>, PhD; Francesca Chappell<sup>1</sup>, PhD; Yulu Shi, PhD; Iona Hamilton, BSc; Katie Flaherty, MSc; Jason P. Appleton<sup>1</sup>, PhD; Fergus N. Doubal, PhD; Philip M. Bath<sup>1</sup>, DSc; Joanna M. Wardlaw<sup>1</sup>, MD

**BACKGROUND AND PURPOSE:** Cerebral small vessel disease—a major cause of stroke and dementia—is associated with cerebrovascular dysfunction. We investigated whether short-term isosorbide mononitrate (ISMN) and cilostazol, alone or in combination, improved magnetic resonance imaging–measured cerebrovascular function in patients with lacunar ischemic stroke.

**METHODS:** Participants were randomized to ISMN alone, cilostazol alone, both ISMN and cilostazol, or no medication. Participants underwent structural, cerebrovascular reactivity (to 6% carbon dioxide) and phase-contrast pulsatility magnetic resonance imaging at baseline and after 8 weeks of medication.

**RESULTS:** Of 27 participants (mean age, 68±7.7; 44% female), 22 completed cerebrovascular reactivity and pulsatility imaging with complete datasets. White matter cerebrovascular reactivity increased in the ISMN ( $\beta=0.021\%/mm\text{Hg}$  [95% CI, 0.003–0.040]) and cilostazol ( $\beta=0.035\%/mm\text{Hg}$  [95% CI, 0.014–0.056]) monotherapy groups and in those taking any versus no medication ( $\beta=0.021\%/mm\text{Hg}$  [95% CI, 0.005–0.037]).

**CONCLUSIONS:** While limited by small sample size, we demonstrate that measuring cerebrovascular function with magnetic resonance imaging is feasible in clinical trials and that ISMN and cilostazol may improve cerebrovascular function.

**REGISTRATION:** URL: <https://www.clinicaltrials.gov>; Unique identifier: NCT02481323. URL: [www.isrctn.com](http://www.isrctn.com); Unique identifier: ISRCTN12580546. URL: [www.clinicaltrialsregister.eu](http://www.clinicaltrialsregister.eu); Unique identifier: EudraCT 2015-001953-33.

**GRAPHIC ABSTRACT:** A [graphic abstract](#) is available for this article.

**Key Words:** cerebral small vessel diseases ■ cilostazol ■ cognitive dysfunction ■ ischemic stroke ■ magnetic resonance imaging

Cerebral small vessel disease (SVD) is a major cause of stroke and dementia. No specific treatment exists to stop disease progression.<sup>1</sup>

SVD is associated with reduced cerebrovascular reactivity (CVR<sup>2</sup>; the ability of blood vessels to increase blood flow), more pulsatile blood flow, and impaired cerebrospinal fluid (CSF) dynamics.<sup>2,3</sup>

Isosorbide mononitrate (ISMN) and cilostazol have pharmacological effects that could improve these cerebrovascular dysfunctions.<sup>1</sup> Cilostazol can reduce stroke recurrence<sup>4</sup> and may reduce cognitive impairment.<sup>5</sup> Glyceryl trinitrate—a shorter-acting nitrate than ISMN—improved cognitive scores in some patients treated early after ischemic stroke.<sup>6</sup>

Correspondence to: Joanna M. Wardlaw, MD, UK Dementia Institute Centre at the University of Edinburgh, Edinburgh EH16 4SB, United Kingdom. Email [joanna.wardlaw@ed.ac.uk](mailto:joanna.wardlaw@ed.ac.uk)

This manuscript was sent to Stephen M. Davis, Guest Editor, for review by expert referees, editorial decision, and final disposition.

Supplemental Material is available at <https://www.ahajournals.org/doi/suppl/10.1161/STROKEAHA.121.034866>.

For Sources of Funding and Disclosures, see page XXX.

© 2021 The Authors. *Stroke* is published on behalf of the American Heart Association, Inc., by Wolters Kluwer Health, Inc. This is an open access article under the terms of the [Creative Commons Attribution](#) License, which permits use, distribution, and reproduction in any medium, provided that the original work is properly cited.

*Stroke* is available at [www.ahajournals.org/journal/str](http://www.ahajournals.org/journal/str)

## Nonstandard Abbreviations and Acronyms

<b>BP</b>	blood pressure
<b>CSF</b>	cerebrospinal fluid
<b>CVR</b>	cerebrovascular reactivity
<b>ISMN</b>	isosorbide mononitrate
<b>LACI-1</b>	LACunar Intervention-1
<b>MRI</b>	magnetic resonance imaging
<b>PI</b>	pulsatility Index
<b>SVD</b>	small vessel disease
<b>WM</b>	white matter

We measured CVR, cerebral blood flow, and CSF dynamics in patients with lacunar stroke randomly assigned to receive ISMN or cilostazol monotherapy, combination therapy, or avoid these medications in the LACI-1 trial (LACunar Intervention-1).<sup>7</sup>

## METHODS

### Data Availability Statement

Access requests can be submitted to the corresponding author.

### Participants and Assessments

This study was a substudy of the main LACI-1 trial. LACI-1 was a phase IIa, partial factorial, prospective randomized open-label blinded end point trial. Our methods are published.<sup>7</sup> We recruited patients with nondisabling lacunar ischemic stroke.

All participants were scanned at randomization and at week 8 in the cilostazol monotherapy, ISMN monotherapy, and ISMN and cilostazol groups and week 3 in the no-medication group (after which this group commenced cilostazol and ISMN to test the alternative order of starting dual therapy). Medication compliance, side effects, and blood pressure (BP) were also assessed at each visit.

All participants provided written informed consent. Ethical approval was obtained from the Scotland-A Research Ethics Committee (Ref: 15/SS/0154).

### Intervention

Participants were randomized to ISMN monotherapy, cilostazol monotherapy, combination ISMN, and cilostazol or no medication.<sup>7</sup> Dose was titrated to ISMN 25 mg BID and cilostazol 100 mg BID.<sup>7</sup> Medication was taken for 8 weeks. Participants were masked to treatment allocation, and investigators assessing outcomes including all image analysis were blinded to treatment allocation.<sup>7</sup>

### Imaging

We performed brain scanning using a 1.5T GE MRI scanner (SignaHDxt; General Electric, Milwaukee, WI). Structural sequences included T1-weighted, T2-weighted, fluid attenuated inversion recovery, and gradient recalled echo.

### CVR Acquisition

During a 12-minute blood oxygen level–dependent magnetic resonance imaging (MRI) scan, participants alternated between breathing medical air and 6% carbon dioxide (CO<sub>2</sub>) in air, as is published previously.<sup>8</sup>

### Pulsatility Acquisition

Our pulsatility method is published previously.<sup>2,3</sup> We used a 2-dimensional cine phase-contrast sequence to measure flow in the internal carotid and vertebral arteries, superior sagittal, straight, and transverse venous sinuses, and foramen magnum and aqueduct CSF flow.

### Image Analysis

We performed CVR analysis by regressing blood oxygen level–dependent signal against end-tidal CO<sub>2</sub>, with CVR expressed as %blood oxygen level–dependent signal change/mmHg change in end-tidal CO<sub>2</sub> as published previously.<sup>7,8</sup> We extracted regional measurements of CVR in identical regions of the same anatomic structures at the two time points. Image analysis was performed by investigators blinded to treatment allocation.

Structural and pulsatility analysis methods are published.<sup>2,3</sup> Pulsatility index (PI) was calculated as  $(\text{Flow}_{\text{maximum}} - \text{Flow}_{\text{minimum}}) / \text{Flow}_{\text{mean}}$ .



### Statistical Analysis

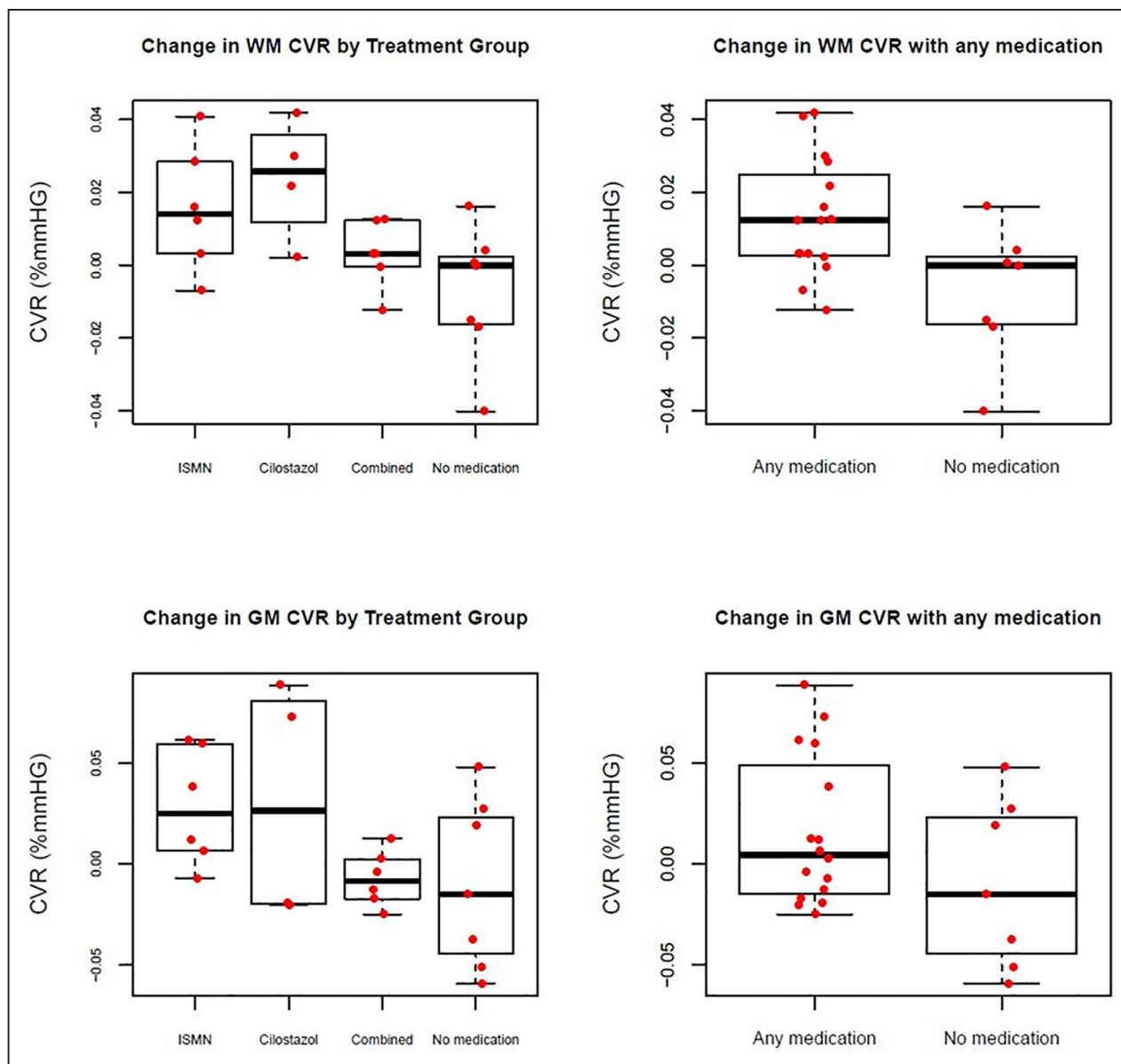
We used R, version 1.0.143, for statistical analyses. To examine the effect of treatment, 2 separate analyses were done. First, an intention-to-treat analysis (main article) and second, a per-protocol analysis (Supplemental Material) where participants who had stopped taking medication at the time of the follow-up scan were excluded from the treatment groups and analyzed as being in the no-medication group. We used multiple linear regression to assess the effect of treatment groups and being on any versus no medication on changes in white matter (WM) and gray matter CVR, PI, and CSF flow adjusting for age because this is suggested to affect CVR. This analysis was repeated and adjusted for systolic BP in place of age to examine the confounding effect of BP. To assure normality of the residuals and assess heteroscedasticity, we examined QQ plots, histograms of residuals, and plots of residual versus fitted values to examine.

This analysis was repeated and adjusted for systolic BP in place of age to examine the confounding effect of BP. Additional analyses were also performed controlling for systolic BP change in place of age between baseline and follow-up.

## RESULTS

Twenty-seven of the 28 participants recruited to LACI-1 consented to the MRI substudy. Full CVR data sets were obtained in 23 participants and full pulsatility data sets in 24 (Supplemental Material). The Figure shows the CONSORT flowchart.

The mean age of included participants was 68±7.7 years (range, 53–83 years), Table 1.



**Figure.** Change in cerebrovascular reactivity (CVR) by treatment group and any vs no medication.

GM indicates gray matter; ISMN, isosorbide mononitrate; and WM, white matter.

### CVR Change After Treatment

WM CVR increased with ISMN and cilostazol monotherapy (both  $P < 0.05$ ) and in participants taking any

versus no trial drug ( $P < 0.05$ ) but not combination therapy (Table 2).

There was no increase in gray matter CVR.

**Table 1.** Patient Characteristics

	All	ISMN	Cilostazol	Combined	No medication	P value
n	27	7	5	7	8	
Age, y	68±7.7	64.6±7.1	74.4±9.2	67.9±4.3	67.0±8.2	0.34
Sex, female	12 (44.4%)	2 (28.6%)	4 (80%)	3 (42.9%)	3 (37.5%)	0.33
Systolic BP, mm Hg	141.9±19.3	142.3±22.8	142.2±17.0	146.9±23.6	137.1±15.7	0.82
Treated hypertension	21 (77.8%)	6 (85.7%)	5 (100%)	4 (57.1%)	6 (75%)	0.52
WMH volume (percentage of intracranial volume), median (IQR)	1.1 (0.5–1.6)	0.5 (0.3–1.2)	1.2 (1.2–1.7)	0.8 (0.6–1.0)	1.3 (0.6–2.1)	0.35

BP indicates blood pressure; IQR, interquartile range; ISMN, isosorbide mononitrate; and WMH, white matter hyperintensity.

**Table 2. Associations Between Change in White Matter CVR, Intracranial Pulsatility, and Treatment**

	Treatment group		Any medication
White matter CVR	ISMN	$\beta=0.021$ (0.003 to 0.040), $P=0.027$	$\beta=0.021$ (0.005–0.037), $P=0.014$
	Cilostazol	$\beta=0.035$ (0.014 to 0.056), $P=0.003$	
	Combined	$\beta=0.011$ (–0.04 to 0.047), $P=0.222$	
Superior sagittal sinus PI	ISMN	$\beta=0.002$ (–0.097 to 0.102), $P=0.960$	$\beta=0.011$ (–0.085 to 0.107), $P=0.816$
	Cilostazol	$\beta=0.121$ (0.003 to 0.239), $P=0.045$	
	Combined	$\beta=-0.041$ (–0.140 to 0.058), $P=0.400$	
Vertebral artery PI	ISMN	$\beta=-0.409$ (–0.747 to –0.070), $P=0.021$	$\beta=-0.226$ (–0.525 to 0.073), $P=0.130$
	Cilostazol	$\beta=-0.107$ (–0.510 to 0.295), $P=0.583$	
	Combined	$\beta=-0.103$ (–0.439 to 0.234), $P=0.531$	

Multiple regression analysis adjusted for age. Standardized  $\beta$ -coefficient, 95% CI, and  $P$  value. The no-medication group is the reference group in all analyses. CVR indicates cerebrovascular reactivity; ISMN, isosorbide mononitrate; and PI, pulsatility index.

## Pulsatility Change After Treatment

Superior sagittal sinus PI increased with cilostazol alone. Vertebral artery PI decreased with ISMN alone (Table 2). CSF pulsatility did not change.

## DISCUSSION

Over an 8-week period, treatment with ISMN or cilostazol alone, or any drug versus no drug, increased WM but not gray matter CVR. Effects on pulsatility varied: ISMN decreased PI in the vertebral arteries; however, cilostazol increased superior sagittal sinus PI, which could be secondary to cilostazol increasing heart rate.<sup>7</sup> No changes in CSF flow dynamics were detected. Combination therapy did not have the effect of monotherapy although CVR in WM increased in participants taking any versus no medication, which includes those allocated dual therapy. Small numbers in each treatment group and participants finding it difficult to reach maximum dose of both drugs in combination means this is more likely sample size related and the true difference between effects of monotherapy versus combination remains undetermined.

Prior studies have measured medication effects on resting cerebral blood flow in similar patient populations. The DANTE study (Discontinuation of Antihypertensives in the Elderly) showed no change in MRI-measured cerebral blood flow after antihypertensive medication withdrawal, compared with continuing antihypertensives.<sup>9</sup> The PRESERVE trial (Prevention of Serious Adverse Events Following Angiography) showed no change in MRI-measured cerebral blood flow with more versus less intensive BP lowering in patients with stroke-related moderate-to-severe SVD.<sup>10</sup> Others have demonstrated pravastatin, atorvastatin, perindopril, and vinpocetine all increase transcranial Doppler-measured vasoreactivity.<sup>11–15</sup> The changes in CVR we demonstrated were independent of any change in systolic BP induced by medication, adding further evidence that changes in blood flow and vascular function in older individuals with SVD have a complex relationship with BP. We have previously demonstrated stronger associations of WM than gray matter CVR with SVD.<sup>2</sup> WM may be

differentially more impaired in SVD and thus more amenable to a detectable pharmacological improvement.

Lack of improvement in PI could reflect that modification of vascular stiffening requires longer treatment. Cilostazol has previously been shown to decrease PI after 90 days in patients with lacunar infarction.<sup>16</sup>

## Limitations

The sample is small. However, a primary aim of LACI-1 was to establish feasibility of the drug regimen to inform a larger trial (LACI-2; ISRCTN14911850) and secondarily to gather efficacy and safety data.<sup>7,17</sup>

The randomization was imperfect, as in the overall main trial,<sup>7</sup> with the cilostazol-only group being older.

## Conclusions

We demonstrated feasibility of cerebrovascular function MRI in a clinical trial of lacunar ischemic stroke and SVD and detected changes in CVR and pulsatility that support the positive modification of cerebrovascular function by existing medications. Larger studies over longer time periods will assess whether these improvements translate into clinical benefits.

## ARTICLE INFORMATION

Received March 23, 2021; final revision received July 6, 2021; accepted August 2, 2021.

### Affiliations

Brain Research Imaging Centre, Centre for Clinical Brain Sciences, UK Dementia Institute Centre at the University of Edinburgh, United Kingdom (G.W.B., M.S.S., M.J.T., F.C., Y.S., I.H., F.N.D., J.M.W.). Department of Neurology, Donders Institute for Brain, Cognition and Behaviour, Donders Centre for Medical Neuroscience, Radboud University Medical Center, Nijmegen, the Netherlands (E.J.). Stroke Trials Unit, Division of Clinical Neuroscience, University of Nottingham, United Kingdom (K.F., J.P.A., P.M.B.). Stroke, University Hospitals Birmingham NHS Foundation Trust, Queen Elizabeth Hospital, Mindelsohn Way, United Kingdom (J.P.A.). Stroke, Queen's Medical Centre Campus, Nottingham University Hospitals NHS Trust, United Kingdom (P.M.B.).

### Acknowledgments

We thank the participants and members of the trial committees.

## Sources of Funding

Alzheimer's Society Ref: 252 (AS-PG-14-033). European Union Horizon 2020 project No. 666881, SVDs@Target (G.W. Blair Dr Stringer); Stroke Association Princess Margaret Research Development Fellowship (G.W. Blair); Stroke Association Garfield Weston Foundation Senior Clinical Lectureship (FN. Doubal); National Health Service Research Scotland (FN. Doubal); China Scholarship Council/University of Edinburgh (Dr Shi); National Health Service Lothian Research & Development Office (Dr Thrippleton); Row Fogo Charitable Trust; Scottish Funding Council via Scottish Imaging Network, A Platform for Scientific Excellence Collaboration; Fondation Leducq (ref. 16CVD05); Edinburgh and Lothians Health Foundation; National Institute for Health Research (NIHR) Health Technology Assessment (HTA) TARDIS Trial (Dr Appleton and P.M. Bath); British Heart Foundation RIGHT-2 Trial (Dr Appleton and P.M. Bath); NIHR HTA TICH-2 trial (Tranexamic Acid for Hyperacute Primary Intracerebral Haemorrhage; K. Flaherty). P.M. Bath is Stroke Association Professor of Stroke Medicine and Emeritus NIHR Senior Investigator. UK Dementia Research Institute Centre at the University of Edinburgh (funded by the Medical Research Council, Alzheimer's Society and Alzheimer's Research UK; Dr Wardlaw).

## Disclosures

P.M. Bath is on the advisory boards of Sanofi, Nestle, DiaMedica, Moleac, Phagenesis, and ReNeuron. The other authors report no conflicts.

## Supplemental Material

LACI-1 Trial Inclusion and Exclusion Criteria  
 Supplemental Methods  
 CONSORT Flowcharts  
 Expanded Participant Characteristics Table  
 Expanded Intention-to-Treat Results Table  
 Per-Protocol Analyses  
 Summary Table  
 Expanded Acknowledgments  
 CONSORT Checklist

## REFERENCES

- Bath PM, Wardlaw JM. Pharmacological treatment and prevention of cerebral small vessel disease: a review of potential interventions. *Int J Stroke*. 2015;10:469–478. doi: 10.1111/ijis.12466
- Blair GW, Thrippleton MJ, Shi Y, Hamilton I, Stringer M, Chappell F, Dickie DA, Andrews P, Marshall I, Doubal FN, et al. Intracranial hemodynamic relationships in patients with cerebral small vessel disease. *Neurology*. 2020;94:e2258–e2269. doi: 10.1212/WNL.0000000000009483
- Shi Y, Thrippleton MJ, Blair GW, Dickie DA, Marshall I, Hamilton I, Doubal FN, Chappell F, Wardlaw JM. Small vessel disease is associated with altered cerebrovascular pulsatility but not resting cerebral blood flow. *J Cereb Blood Flow Metab*. 2020;40:85–99. doi: 10.1177/0271678X18803956
- McHutchison C, Blair GW, Appleton JP, Chappell FM, Doubal F, Bath PM, Wardlaw JM. Cilostazol for secondary prevention of stroke and cognitive decline: systematic review and meta-analysis. *Stroke*. 2020;51:2374–2385. doi: 10.1161/STROKEAHA.120.029454
- Tai SY, Chien CY, Chang YH, Yang YH. Cilostazol use is associated with reduced risk of dementia: a nationwide cohort study. *Neurotherapeutics*. 2017;14:784–791. doi: 10.1007/s13311-017-0512-4
- ENOS Trial Investigators. Efficacy of nitric oxide, with or without continuing antihypertensive treatment, for management of high blood pressure in acute stroke (ENOS): a partial-factorial randomised controlled trial. *Lancet*. 2015;385:617–628.
- Blair GW, Appleton JP, Flaherty K, Doubal F, Sprigg N, Dooley R, Richardson C, Hamilton I, Law ZK, Shi Y, et al. Tolerability, safety and intermediary pharmacological effects of cilostazol and isosorbide mononitrate, alone and combined, in patients with lacunar ischaemic stroke: the LACunar Intervention-1 (LACI-1) trial, a randomised clinical trial. *EClinicalMedicine*. 2019;11:34–43. doi: 10.1016/j.eclinm.2019.04.001
- Thrippleton MJ, Shi Y, Blair G, Hamilton I, Waiter G, Schwarzbauer C, Pernet C, Andrews PJ, Marshall I, Doubal F, et al. Cerebrovascular reactivity measurement in cerebral small vessel disease: rationale and reproducibility of a protocol for MRI acquisition and image processing. *Int J Stroke*. 2018;13:195–206. doi: 10.1177/1747493017730740
- Foster-Dingley JC, Moonen JE, de Craen AJ, de Ruijter W, van der Mast RC, van der Grond J. Blood pressure is not associated with cerebral blood flow in older persons. *Hypertension*. 2015;66:954–960. doi: 10.1161/HYPERTENSIONAHA.115.05799
- Croall ID, Tozer DJ, Moynihan B, Khan U, O'Brien JT, Morris RG, Cambridge VC, Barrick TR, Blamire AM, Ford GA, et al; PRESERVE Study Team. Effect of standard vs intensive blood pressure control on cerebral blood flow in small vessel disease: the PRESERVE randomized clinical trial. *JAMA Neurol*. 2018;75:720–727. doi: 10.1001/jamaneuro.2017.5153
- Walters M, Muir S, Shah I, Lees K. Effect of perindopril on cerebral vasomotor reactivity in patients with lacunar infarction. *Stroke*. 2004;35:1899–1902. doi: 10.1161/01.STR.0000131748.12553.ed
- Sterzer P, Meintzschel F, Rösler A, Lanfermann H, Steinmetz H, Sitzer M. Pravastatin improves cerebral vasomotor reactivity in patients with subcortical small-vessel disease. *Stroke*. 2001;32:2817–2820. doi: 10.1161/hs1201.099663
- Jovanović ZB, Pavlović AM, Pekmezović T, Mijajlović M, Covicković NS. Transcranial Doppler assessment of cerebral vasomotor reactivity in evaluating the effects of vinpocetine in cerebral small vessel disease: a pilot study. *Ideggyogy Sz*. 2013;66:263–268.
- Sander K, Hof U, Poppert H, Conrad B, Sander D. Improved cerebral vasoreactivity after statin administration in healthy adults. *J Neuroimaging*. 2005;15:266–270. doi: 10.1177/1051228405277403
- Pretnar-Oblak J, Sabovic M, Sebestjen M, Pogacnik T, Zaletel M. Influence of atorvastatin treatment on L-arginine cerebrovascular reactivity and flow-mediated dilatation in patients with lacunar infarctions. *Stroke*. 2006;37:2540–2545. doi: 10.1161/01.STR.0000239659.99112.fb
- Han SW, Song TJ, Bushnell CD, Lee S-S, Kim SH, Lee JH, Kim GS, Kim O-J, Koh I-S, Lee JY, et al. Cilostazol decreases cerebral arterial pulsatility in patients with mild white matter hyperintensities: subgroup analysis from the ECLIPSE study. *Cerebrovasc Dis*. 2014;38:197–203. doi: 10.1159/000365840
- Appleton JP, Blair GW, Flaherty K, Law ZK, May J, Woodhouse LJ, Doubal F, Sprigg N, Bath PM, Wardlaw JM. Effects of isosorbide mononitrate and/or cilostazol on hematological markers, platelet function, and hemodynamics in patients with Lacunar Ischaemic Stroke: safety data from the Lacunar Intervention-1 (LACI-1) trial. *Front Neurol*. 2019;10:723. doi: 10.3389/fneur.2019.00723