



THE UNIVERSITY *of* EDINBURGH

Edinburgh Research Explorer

A review on rabbit ocular *Encephalitozoon cuniculi* infection

Citation for published version:

Baney, V, Blacklock, B & Keeble, E 2021, 'A review on rabbit ocular *Encephalitozoon cuniculi* infection', *UK-VET Companion animal*. <https://doi.org/10.12968/coan.2021.0050>

Digital Object Identifier (DOI):

[10.12968/coan.2021.0050](https://doi.org/10.12968/coan.2021.0050)

Link:

[Link to publication record in Edinburgh Research Explorer](#)

Document Version:

Peer reviewed version

Published In:

UK-VET Companion animal

Publisher Rights Statement:

This document is the Accepted Manuscript version of a Published Work that appeared in final form in Companion Animal, copyright © MA Healthcare, after peer review and technical editing by the publisher. To access the final edited and published work see <https://www.magonlinelibrary.com/doi/full/10.12968/coan.2021.0050>

General rights

Copyright for the publications made accessible via the Edinburgh Research Explorer is retained by the author(s) and / or other copyright owners and it is a condition of accessing these publications that users recognise and abide by the legal requirements associated with these rights.

Take down policy

The University of Edinburgh has made every reasonable effort to ensure that Edinburgh Research Explorer content complies with UK legislation. If you believe that the public display of this file breaches copyright please contact openaccess@ed.ac.uk providing details, and we will remove access to the work immediately and investigate your claim.



A review on rabbit ocular *Encephalitozoon cuniculi* infection

Victoria Baney BVM&S MRCVS Anton Vets, Andover, Hampshire, SP10 2NJ, United Kingdom; Dr Ben Blacklock BVSc (Hons) DipECVO MRCVS RCVS & EBVS® European Specialist in Veterinary Ophthalmology, Senior Lecturer in Veterinary Ophthalmology; Dr Emma Keeble BVSc (Hons), Dip ZooMed (Mammalian), FHEA, MRCVS RCVS Recognised Specialist in Zoo and Wildlife Medicine (Small Mammal) Senior Lecturer in Rabbit, Exotic Animal and Wildlife Medicine and Surgery, Exotic Animal and Wildlife Clinician, The Royal (Dick) School of Veterinary Studies and The Roslin Institute, Easter Bush Campus, Midlothian, EH25 9RG. emma.keeble@ed.ac.uk


Abstract

Encephalitozoon cuniculi is a microsporidian parasite affecting rabbits and other mammals, including immunocompromised humans. One clinical manifestation of *E. cuniculi* is the ocular form, typically presenting with phacoclastic uveitis, a yellow-white granuloma and a cataract. This literature review will focus on the aetiopathogenesis, presentation, diagnosis, and treatment options for ocular *E. cuniculi* with emphasis on phacoemulsification, the gold standard treatment.

Introduction

As well as infecting rabbits, *Encephalitozoon cuniculi* may also colonise other mammals including mice, cats, dogs and sheep. It is important to recognise its zoonotic potential in immunocompromised humans. In rabbits, *E. cuniculi* most commonly presents as a neurological condition (*Figure 1*), but also affects the kidneys and eyes. Exposure to *E. cuniculi* is not uncommon in the UK, with one study finding that 52% of healthy rabbits were seropositive for *E. cuniculi* antibodies (Keeble and Shaw, 2006). Compared to the prevalence of *E. cuniculi* seropositivity, the prevalence of the ocular manifestation is fairly low (Williams, 2012).

Figure 1. Neurological presentation of *E. cuniculi* showing a left sided head tilt. This animal had a very high IgG titre on *E.cuniculi* serology.

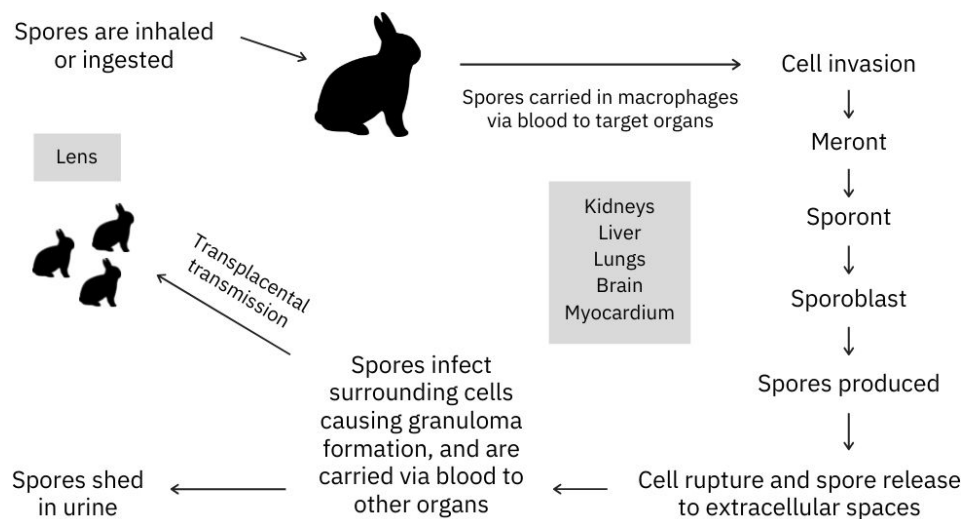


Aetiopathogenesis

The classification of *E. cuniculi* is controversial. Previously classed as a protozoal parasite, and often still referred to as this, the current categorisation of *E. cuniculi* microsporidia is an obligate intracellular atypical fungi without mitochondria (Vergneau-Grosset and Sylvain, 2016). Three strains of *E. cuniculi* have been identified, with strain I infecting rabbits and humans, strain II infecting rodents, and strain III infecting dogs and humans (Didier et al, 1995).

E. cuniculi and other microsporidia infect host cells using a polar tube that pushes a sporoplasm against the cell membrane, causing invagination and uptake into a parasitophorous vacuole protected from the cell defence mechanisms (Kunzel, 2018; Bohne et al, 2011). Alternatively, infection can occur if the spore is phagocytosed by the host cell (Kunzel, 2018). Within the parasitophorous vacuoles, *E. cuniculi* meronts replicate and differentiate, first into sporonts and then into mature spores. Eventually, the parasitophorous vacuole ruptures because of overcrowding, releasing the spores (Kunzel, 2018) and continuing the cycle (Figure 2).

Figure 2. *Encephalitozoon cuniculi* life cycle



E. cuniculi transmission can be vertical or horizontal. Horizontal transmission usually involves ingestion or inhalation of the microsporidian's environmentally resistant spores shed in infected urine (Künzel and Fisher, 2018). The parasite first affects the kidneys, liver and lungs, eventually targeting the brain (Künzel and Fisher, 2018). Vertical transmission, or transplacental from an infected mother, has been confirmed via polymer chain reaction (PCR) tests for *E. cuniculi* DNA in rabbit foetuses (Baneux and Pognan, 2003). It was originally unclear whether ocular infection occurred prenatally or postnatally, but further PCR testing on affected enucleated eyes confirmed that the parasite infects the ocular tissue while in utero (Özkan et al, 2019). While rabbit embryos are developing, the early lens forms a few days prior to the protective lens capsule (the lens capsule is the basement membrane of the lens epithelial cells), so it is likely the microsporidian infects the unprotected lens cells via its rich

tunica vasculosa lentis blood supply during this time window (Boillot et al, 2015; Özkan et al, 2019). After birth and as the rabbit ages, the spores cause the lens capsule to rupture, leading to lens protein escape and resulting in phacoclastic uveitis and a pyogranulomatous inflammation (Felchle and Sigler, 2002). One report found rabbits with ocular granulomas caused by *E. cuniculi* were, on average, 18 months of age, with an age range of 3–60 months (Wolfer et al, 1993). In utero infection appears to only affect the eye, and not the other organs (Künzel and Joachim, 2010). However, one study by Jeklová (2019) suggested that in utero infection may not be the only aetiology of ocular *E. cuniculi* infection. New Zealand White rabbits aged 4 months old were orally infected with *E. cuniculi* spores, then euthanised at 2, 4, 6 and 8 weeks post-infection, and their eyes collected for immunohistochemistry. While none of these rabbits developed any signs of uveitis, cataract, or ocular granuloma, spores were detected most frequently in the cornea and sclera, and also in the lens in 11 out of 25 infected rabbits (Jeklová, 2019). This demonstrates that the microsporidian can access the lens postnatally, but the mechanism of this is currently unknown. In the adult rabbit, the lens is enclosed in the lens capsule and is avascular, receiving its nutritional support from the aqueous humour as the blood supply from the tunica vasculosa lentis regresses postnatally by day six (Boillot et al, 2015). It is therefore unclear how *E. cuniculi* entered the lens in these 4-month-old rabbits. Another question arising from the Jeklová (2019) study is whether these postnatally infected rabbits would eventually go on to develop phacoclastic uveitis similar to rabbits infected in utero, but as the study rabbits were euthanised this remains unanswered.

Clinical presentation

Ophthalmic *E. cuniculi* presents in a variety of ways, and may be mistaken for pasteurellosis or uveal neoplasia. The ocular lesions are usually unilateral, but bilateral lesions can also be seen (Harcourt-Brown and Holloway, 2003). It often presents as a white-yellow mass (granuloma), seen in the anterior chamber of the eye with neovascularisation, and a cataract (Figure 3). This mass begins at the lens, as it originates from where there is a break in the lens capsule, with lens protein leakage and a subsequent development of phacoclastic uveitis (Donnelly, 2003), (Figure 4). Williams (2012) reported that, unlike uveitis in other species, ocular *E. cuniculi* often does not present with a miotic pupil. Aqueous flare will usually be seen with a slit lamp (Maini and Hartley, 2019). However, the eye's posterior segment does not have pathologic changes (Williams, 2012). On tonometry, the affected eyes will usually have a lowered intraocular pressure, but they may be normal (see later for normal reference

intervals in rabbits), (Williams, 2012). If the uveitis is chronic, the affected eye can develop secondary glaucoma, synechiae or phthisis bulbi (Sandmeyer et al, 2011). Secondary glaucoma in dogs with lens-induced uveitis may be caused by blockage of the iridocorneal drainage angle by macrophages full of phagocytosed lens (Wilcock, 1987). It is possible a similar process can be extrapolated to rabbits.

Figure 3. Cataracts are commonly seen on routine clinical examination of pet rabbits and determining the underlying cause is important. This is a late mature cataract. There is some pigment deposition on the anterior lens capsule (iris rests), indicating a degree of intraocular inflammation (uveitis) associated with the cataract.

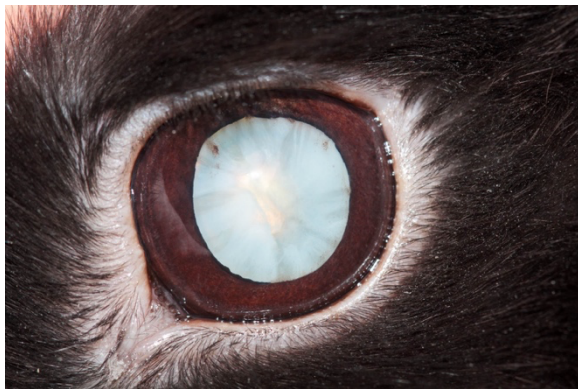
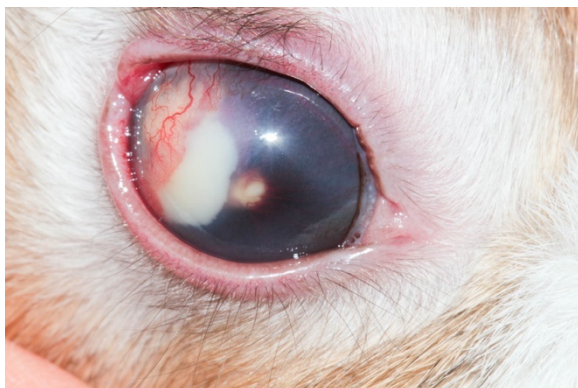
Figure 4. Lens capsule rupture in a rabbit. There is a miotic pupil (difficult to see because of diffuse corneal oedema), iris vascularisation and a large amount of lens material (white matter) in the anterior chamber. There is also corneal neovascularisation affecting mainly the lateral portion of the cornea.



Diagnosis

Diagnosing *E. cuniculi* can be challenging. Serology of IgG and IgM immunoglobulins is utilised in diagnosis, but may not always be straightforward. The severity of clinical signs does not correlate with serological titres because of the life cycle of the parasite (*Figure 2*), (Mancinelli, 2015). IgG immunoglobulin indicates exposure to *E. cuniculi*, but cannot be used alone to determine when infection occurred (Mancinelli, 2015). Following experimental infections of rabbits, there are three IgG responses that may occur: short, long, and episodic (Kunstýř et al, 1986). The short response is defined as an eventual decrease in IgG levels after days 45–63 post-infection, the long response is when IgG titre continuously rises even after 68 days post-infection, and episodic is when there are multiple, short periods of seroconversion (Kunstýř et al, 1986). It is still unclear why different rabbits fall into these three IgG responses, but it is thought to be influenced by individual immune system variations and exposure load (Latney et al, 2014). If IgM immunoglobulin is elevated, there is usually an acute or reactivated infection (Latney et al, 2014). Initial response and elevation of immunoglobulins post-infection can vary. One study looking at *E. cuniculi* humoral response detected IgM as early as 1-week post-infection, and IgG one week after when given high exposure loads (Jeklová, 2010). In general, IgM will increase between days 0–35 and decrease from weeks 5–18 (Latney et al, 2014). Unfortunately, the humoral responses do not appear to protect rabbits against *E. cuniculi* (Künzel and Joachim, 2010). For ocular *E. cuniculi*, a presumed diagnosis can be made based on the pathognomonic signs of cataract, uveitis, and a granuloma, and further supported with serology. However, it should be noted that a negative IgG titre does not rule out *E. cuniculi* as a potential cause of uveitis, since these cases can present chronically, and a wide variation in antibody response is reported in rabbits – with some individuals recording negative IgG titres 8 weeks post-infection (Keeble, 2013).

The diagnosis can be confirmed if phacoemulsification or enucleation is opted for with histology and immunohistochemical staining. On histopathology of removed eyes, intralenticular heterophils, foamy macrophages and fibrous tissue with lymphocytes are seen (Van Der Woerdt, 2000). Immunohistochemical staining is performed using anti-*E. cuniculi* mouse anti-serum, in order to detect the spores in macrophages, lens epithelial cells and outside cells among inflammatory debris (Giordano et al, 2005).

PCR testing on the removed ocular tissue for *E. cuniculi* spore DNA is both highly sensitive and specific (Latney et al, 2014) and is a good option for confirming the diagnosis post-

operatively. PCR testing on urine may be attempted, but is unreliable because of intermittent spore shedding (Varga, 2013).

Treatment Options

Phacoemulsification

Phacoemulsification, involving lens breakdown through high frequency ultrasound, is the gold standard of treatment for ocular *E. cuniculi* associated with a cataract. An artificial intraocular lens may be placed in the lens capsule following phacoemulsification. Prior to performing this operation, it is very important to thoroughly examine the affected eye (*Figure 5*). If the rabbit's eye exhibits lens luxation, retinal detachment or chronic changes, then they may not be suitable surgical candidates for the procedure, on account of the eye being non-visual, or alternatively they may require a modified procedure (Sanchez et al, 2017). Retinal detachment can be assessed via ophthalmoscopy and ultrasonography. There is little point in proceeding to remove the cataract and place a lens if there is a poor prognosis for vision, because of underlying retinal pathology. Luxation or subluxation (instability) of the lens may occur as rabbits with uveitis have increased aqueous humour matrix metalloproteinases that degrade the lens zonules that support the lens (Colitz and O'Connell, 2015), which may complicate treatment.

Phacoemulsification is a specialist procedure performed by veterinary ophthalmologists. The rabbit's extraocular muscles can be paralyzed with neuromuscular blocking agents to facilitate surgery. Atacurium (Felchle and Sigler, 2002) or cisatracurium (Ledbetter et al, 2018) have been described for rabbit phacoemulsification. The general procedure for cataract surgery is similar across canine, feline, rabbit and human patients. One or two small incisions are made into the eye adjacent to the limbus. The anterior chamber is stabilised with a special gel (viscoelastic) and a large circular hole is made in the anterior lens capsule. The lens material is removed via a phacoemulsification handpiece, and an artificial intraocular lens (IOL) may be placed in the now empty lens capsular bag, or, alternatively, the eye can be left aphakic. The current recommended size and dioptré of an IOL to reach emmetropia is 13 millimeters diameter, with a dioptré power of +58D (Sanchez et al, 2017). An artificial IOL will allow images projected onto the retina to be in focus, resulting in better visual acuity. In one operation, a rabbit received an artificial IOL in one eye, and had the lens removed in the other eye, with no IOL placed (aphakic). Postoperatively, the owner reported that the rabbit

preferred to use the eye containing the IOL to look at objects and the owner (Ledbetter et al, 2018). While the anecdotal evidence supports the use of an IOL to improve rabbit vision, more needs to be done to assess and quantify the extent of visual improvement achievable with this technique. If hypopyon or granulomas are present, these can be aspirated at the time of phacoemulsification (Maini and Hartley, 2019).

Figure 5. Ophthalmic examination of a rabbit's eye.



Intraoperative complications

While any surgical procedure involves anaesthetic risks, there are several intraoperative complications of rabbit phacoemulsification, which should be fully considered prior to the procedure. Iris prolapse may occur through the incision, as the rabbit has a shallower anterior chamber compared to other animals, such as the dog (Holmberg, 2007). Other intraoperative complications include lens luxation and expulsive choroidal haemorrhage (Sanchez et al, 2017). With any ocular surgery in rabbits, corneal ulceration is a risk. To prevent corneal ulcers, the downward facing eye can be protected with vacuum cushions and lubrication

(Foote, 2020) or alternatively, the eye can be lubricated and cruciate skin sutures placed on the eyelids to close the eye (Sanchez et al, 2017).

Postoperative complications

Postoperative ocular hypertension is not uncommon following phacoemulsification, with evidence suggesting a prevalence of up to 75% of canine patients (Klein, 2011). As of yet, the exact postoperative prevalence in rabbits has not been investigated, but it has been reported to occur (Ledbetter et al, 2018). In rabbits, the reference ranges for normal intraocular pressure are 15.4 mmHg +/- 2.2 mmHg with a Tono-Pen applanation tonometer and 9.5 mmHg +/- 2.2 mmHg with a TonoVet rebound tonometer (Maini and Hartley, 2019). The danger of postoperative ocular hypertension includes vision loss associated with injury to the optic nerve, retina and corneal endothelium (Miller et al, 1997). Fortunately, if postoperative ocular hypertension does occur, it is manageable. One study described successful treatment of a rabbit with brinzolamide every 8 hours, resulting in a normal intraocular pressure (Ledbetter et al, 2018). One option is to prophylactically prescribe a topical antihypertensive for 48 hours after phacoemulsification, in order to prevent postoperative hypertension from occurring (Sanchez et al, 2017). When assessing a rabbit's intraocular pressure postoperatively, the reading should ideally be taken at approximately the same time each day as diurnal variations can occur (Foote, 2020), which could lead to misinterpretation of results.

Another common postoperative complication is lens material regeneration. This phenomenon, called posterior capsular opacification (PCO), occurs when residual lens epithelial cells, attached to the lens capsule, proliferate in response to the trauma of cataract surgery (Wormstone, 2020). Rabbit lens epithelial cells may also differentiate into lens cells, that proceed to replicate, contributing to PCO, which does not occur in dogs (Williams, 2012). This may occur at varying degrees of severity, causing visual distortion as a result of the scattering of incoming light. While PCO also occurs in human and canine patients, rabbits can develop particularly rapid and severe PCO (Wormstone, 2020; Sanchez et al, 2017). It appears PCO is more likely to occur in juvenile rabbits (Ledbetter et al, 2018), which is significant as rabbits affected with *E. cuniculi* phacoclastic uveitis tend to be younger. Another possible contributing factor is that juvenile rabbits have an increased postoperative inflammatory response (Gwon, 2008). Other factors contributing to PCO include the degree of surgical trauma and the design of the IOL (Gwon, 2008).

Prognosis

It is difficult to objectively assess vision after phacoemulsification, but owners' observations of their rabbits after surgery can indicate whether there has been a good improvement in vision (Sanchez et al, 2017). Owners of rabbits with bilateral cataracts reported decreased activity, curiosity, playfulness and social interaction with other rabbits. However, after cataract surgery, owners believed their rabbits improved, with vision returning to levels similar to before cataracts developed (Sanchez et al, 2017). This anecdotal evidence suggests phacoemulsification is a worthwhile procedure to improve rabbit quality of life.

Medical therapy

If cataract surgery is not an option or the rabbit is not a suitable surgical candidate, medical therapy may be attempted, but there is little published literature on its success or effect on long-term prognosis. Fenbendazole is licensed for treatment of *E. cuniculi* infection in rabbits and can be given orally daily for 28 days, in combination with topical ocular prednisolone acetate administered two to three times a day for 8 weeks, with or without topical atropine drops daily (Keeble, 2011; Williams, 2012). Some success has been reported with systemic dexamethasone and oxytetracycline treatment, with simultaneous ocular dexamethasone and tetracycline for 14 days (Ewringmann and Gobel, 1999). However, while this resolved the uveitis, the granuloma and cataracts remained (Ewringmann and Gobel, 1999). In one study, three rabbits awaiting serological results were treated with 0.1% dexamethasone sodium phosphate and 1% atropine sulphate eye drops topically, as well as with enrofloxacin and albendazole systemically (Giordano et al, 2005). However, the ocular lesions progressed in all three rabbits, leading to enucleation, as the owners declined phacoemulsification. While both of these treatment attempts utilised dexamethasone to reduce the inflammation in the eye, steroid use in *E. cuniculi* infections is controversial. As the humoral response is not protective, the major defence against infection is T-cell mediated destruction of infected cells (Latney et al, 2014). However, T-cell function and production is negatively altered by corticosteroid administration (Künzel and Joachim, 2010), so this may affect the rabbit's ability to eliminate infection. Additionally, the use of steroids is often avoided because of their strong immunosuppressant properties in rabbits, with even ocular steroids being systemically absorbed (Latney, 2014). If steroids are used, haematology must be carefully monitored. Alternatively, ocular non-steroidal anti-inflammatories may be considered,

provided the rabbit has adequate renal function (Mancinelli, 2015). Medical therapy is not always reliable, and standard treatment protocols have not been developed. However medical treatment may be useful as an initial treatment, prior to surgery, or if other options are not possible.

Alternative treatment options

Alternatively, the blind affected eye may be left if cataract surgery is not performed and medical therapy is unsuccessful, but only provided the eye is non-painful. This is essential to determine, as rabbits are prey species and naturally hide signs of pain, which could lead to welfare concerns for the affected animal. However, rabbits can cope with blindness if they live in a familiar environment with a companion (Fehr, 2013). An uncommon complication of chronic phacoclastic uveitis in rabbits is development of an intraocular sarcoma, thought to be a result of neoplastic transformation of lens epithelial cells secondary to injury (Dickinson et al, 2013). It is still to be determined whether neoplastic transformation also occurs in *E. cuniculi*-associated phacoclastic uveitis, but this is worth considering if an affected eye is to remain in situ.

Enucleation

If the eye is painful, enucleation must be performed on welfare grounds (*Figure 6*). Signs of ocular pain in rabbits include blepharospasm, enophthalmos, and epiphora (Gelatt and Plummer, 2017). Changes indicating the requirement for enucleation include chronic synechia, phthisis bulbi, and glaucoma (Sandmeyer et al, 2011). While phthisis bulbi itself is not painful, if it causes entropion because of the eye being retracted, or it is associated with chronic inflammation, enucleation is required (Mitchell, 2008) as these conditions are associated with pain. Acute glaucoma is associated with severe pain and chronic glaucoma is associated with continuous dull pain, that is relieved after enucleation (Maggio, 2015). So again, if present, the eye should be removed on welfare grounds (*Figure 7*). The main complication in rabbit enucleation is an increased haemorrhage risk because of the orbital venous plexus behind the globe (Williams, 2012), which cannot be ligated if haemorrhaging, rather relying on pressure to control bleeding. Haemorrhage can be prevented by performing a transconjunctival enucleation rather than the transpalpebral method used in dogs and cats, as this technique involves dissecting closer to the globe, to better avoid damaging the orbital venous plexus (Diehl and McKinnon, 2016). Enucleated eyes can be submitted for PCR or immunohistochemistry to confirm *E. cuniculi*. Postoperative complications may include

infection, dehiscence, haemorrhage or, less commonly, orbital emphysema if the nasolacrimal duct remains patent (Diehl and McKinnon, 2016).

Figure 6. Enucleation of a rabbit's eye. The main potential surgical complication in this species is an increased risk of haemorrhage because of the orbital venous plexus. Intubation of the patient is essential to ensure a secure airway.

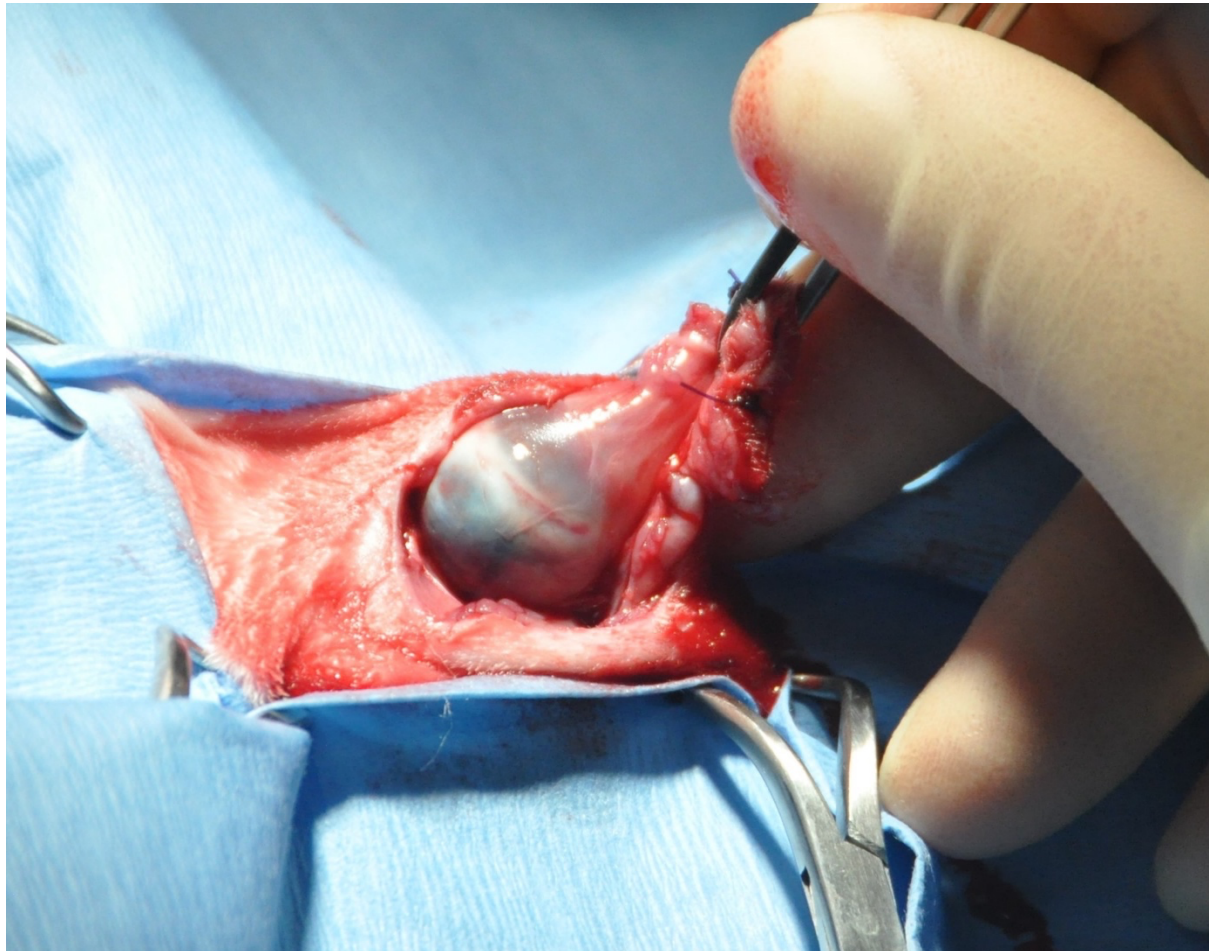
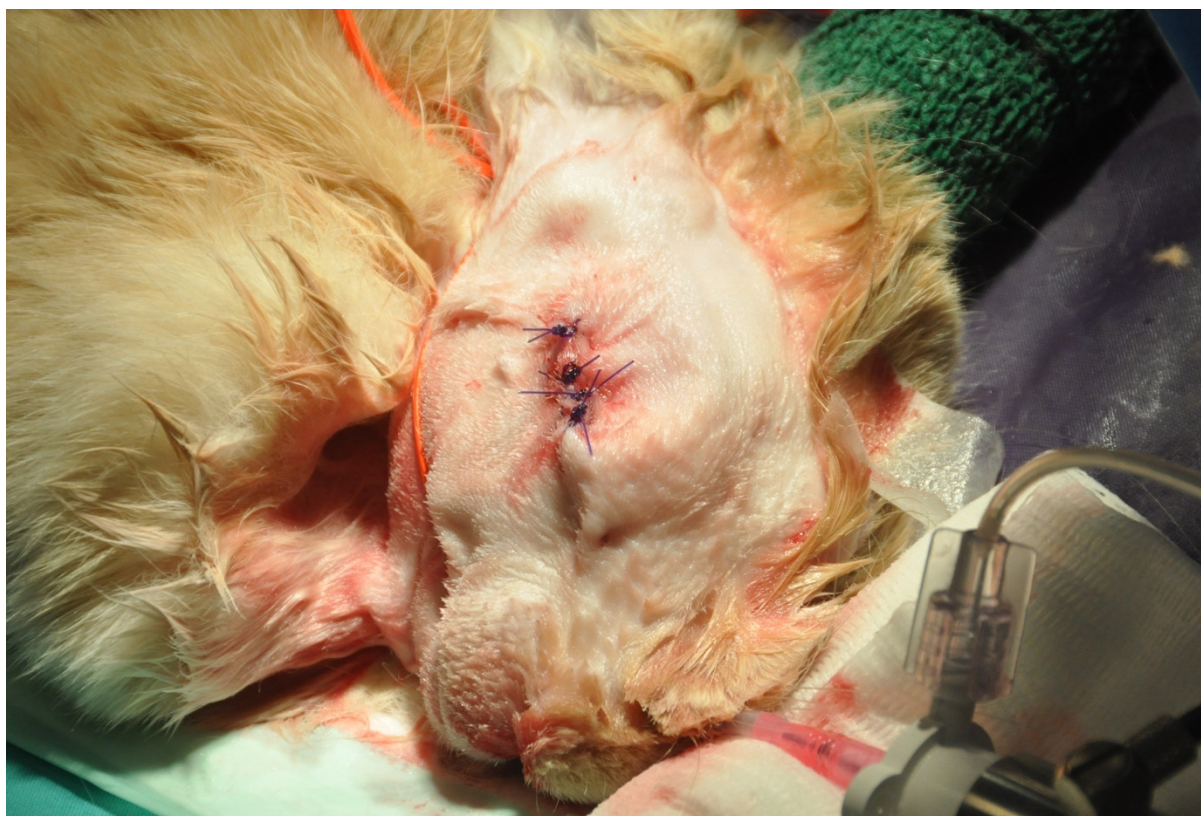

Figure 7. Postoperative appearance of wound following enucleation. Fur will regrow and the rabbit will learn to cope if kept in a familiar environment with a companion.



Conclusions

Ocular *E. cuniculi*, while not as common as the neurological presentation, still has a significant impact on rabbit health and welfare. Despite rabbits now being popular pets with dedicated owners, there are still numerous gaps in our knowledge of the disease process, treatment, and management of the ocular manifestation of this common condition in pet rabbits. Current treatment options for this condition include medical management, enucleation, and phacoemulsification, with the option of benign neglect in select cases that are veterinary assessed as non-painful. Phacoemulsification is considered the optimal treatment for rabbits affected by ocular *E. cuniculi* as it removes the source of inflammation and gives the best visual prognosis. Unfortunately, studies focused on cataract surgery in rabbits primarily have a human medical research aim, rather than being in the interest of pet rabbits. Therefore, visual acuity and its impact on quality of life in rabbits after placement of an artificial lens following phacoemulsification remains an important area for further research.

Conflicts of interest

Acknowledgements

Figure 6 and 7 were provided courtesy of Dr Jenna Richardson MRCVS.

Key points:

References

Baneux PJR, Pognan F. In utero transmission of *Encephalitozoon cuniculi* strain type I in rabbits. *Lab Anim*. 2003;37(2):132–138. <https://doi.org/10.1258/00236770360563778>

Bohne W, Böttcher K, Gross U. The parasitophorous vacuole of *Encephalitozoon cuniculi* : Biogenesis and characteristics of the host cell–pathogen interface. *Int J Med Microbiol*. 2011;301(5):395–399. <https://doi.org/10.1016/j.ijmm.2011.04.006>

Boillot T, Graille M, Williams D, Rosolen SG. Unilateral persistent hyperplastic tunica vasculosa lentis and persistent hyperplastic primary vitreous in a rabbit. *Vet Ophthalmol*. 2015;18(6):510–514. <https://doi.org/10.1111/vop.12251>

Colitz CMH, O’Connell K. Lens-Related Emergencies: Not Always So Clear. *Top Companion Anim Med*. 2015;30(3):81–85. <https://doi.org/10.1053/j.tcam.2015.08.001>

Dickinson R, Bauer B, Gardhouse S, Grahn B. Intraocular sarcoma associated with a rupture lens in a rabbit (*Oryctolagus cuniculus*). *Vet Ophthalmol*. 2013;16(Suppl 1):168–172. <https://doi.org/10.1111/vop.12049>

Didier ES, Vossbrinck CR, Baker MD, Rogers LB, Bertucci DC, Shadduck JA. Identification and characterisation of three *Encephalitozoon cuniculi* strains. *Parasitology*. 1995;11(Pt 4):411–421.

Diehl KA, McKinnon J. Eye removal surgeries in exotic pets. *Vet Clin North Am Exot Anim Pract*. 2016;19(1):245–267. <https://doi.org/10.1016/j.cvex.2015.08.003>

Donnelly TM. 2003. *Encephalitozoon cuniculi*-associated phacoclastic uveitis in the rabbit: a review. *Journal of Exotic Mammal Medicine and Surgery*. 2003;1(1):1–3.

Ewringmann A, Gobel T. Examinations on clinics and therapy of encephalitozoonosis in pet rabbits. *Kleintierpraxis*. 1999;44(5):357.

Felchle LM, Sigler RL. Phacoemulsification for the management of *Encephalitozoon cuniculi*-induced phacoclastic uveitis in a rabbit. *Vet Ophthalmol*. 2002;5(3):211–215. <https://doi.org/10.1046/j.1463-5224.2002.00240.x>

Fehr M. Eye and eyelid surgery. In: Harcourt-Brown F, Chitty J (eds). *BSAVA Manual of Rabbit Surgery* (1st edn). Quedgeley, Gloucester, England: British Small Animal Veterinary Association, 2013;233–237.

Foote AR. Nursing considerations for the ophthalmic rabbit patient. *Vet Nurse J*. 2020;35(4):100–104. <http://doi.org/10.1080/17415349.2020.1724221>

Gelatt KN. 2014. Canine lens: cataract, luxation and surgery. In: Gelatt KN (eds), *Essentials of Veterinary Ophthalmology* (3rd edn). Oxford, UK: Wiley-Blackwell, 2014;301–323.

Gelatt KN, Plummer CE. *Color Atlas of Veterinary Ophthalmology* (2nd edn). New York: John Wiley & Sons Inc, 2017.

Giordano C, Weigt A, Vercelli A, Rondena M, Grilli G, Giudice C. Immunohistochemical identification of *Encephalitozoon cuniculi* in phacoclastic uveitis in four rabbits. *Vet Ophthalmol.* 2005;8(4):271–275. <https://doi.org/10.1111/j.1463-5224.2005.00394.x>

Gwon A. The rabbit in Cataract/IOL Surgery. In: Tsonis PA (eds), *Animal Models in Eye Research*. Academic Press. 2008;184-204. <https://doi.org/10.1016/B978-0-12-374169-1.00013-8>

Harcourt-Brown FM, Holloway HKR. *Encephalitozoon cuniculi* in pet rabbits. *Vet Rec.* 2003;152(14):427–431. <https://doi.org/10.1136/vr.152.14.427>

Holmberg BJ. Ophthalmology of Exotic Pets. In: Maggs D, Miller PD, Ofri R (Eds). *Slatter's Fundamentals of Veterinary Ophthalmology* (4th edn) Saint Louis: Elsevier. 2007;427–441

Jeklová E, Levá L, Kummer V, Jekl V, Faldyna M. Immunohistochemical Detection of *Encephalitozoon cuniculi* in Ocular Structures of Immunocompetent Rabbits. *Anim (Basel).* 2019;9(11):988. <https://doi.org/10.3390%2Fani9110988>

Keeble E, Shaw DJ. Seroprevalence of antibodies to *Encephalitozoon cuniculi* in domestic rabbits in the United Kingdom. *Vet Rec.* 2006;158(16):539–544. <https://doi.org/10.1136/vr.158.16.539>

Keeble E. *Encephalitozoonosis* in rabbits – what we do and don't know. In *Pract.* 2011;33(9):426–435. <https://doi.org/10.1136/inp.d6077>

Keeble E. *Encephalitozoonosis; Rabbits*. In: Mayer J, Donnelly TM (eds). *Clinical Veterinary Advisor, Birds and Exotic Pets*. Elsevier, Missouri, 2013;371-374

Klein HE, Krohne SG, Moore GE, Stiles J. Postoperative complications and visual outcomes of phacoemulsification in 103 dogs (179 eyes): 2006-2008. *Vet Ophthalmol.* 2011;14(2):114–120. <https://doi.org/10.1111/j.1463-5224.2010.00853.x>

Kunstýř I, Lev L, Naumann S. 1986. Humoral antibody response of rabbits to experimental infection with *Encephalitozoon cuniculi*. *Vet Parasit.* 1986;21(4):223–232. [https://doi.org/10.1016/0304-4017\(86\)90048-8](https://doi.org/10.1016/0304-4017(86)90048-8)

Künzel F, Fisher PG. Clinical Signs, Diagnosis, and Treatment of *Encephalitozoon cuniculi* Infection in Rabbits. *Vet Clin North Am Exot Anim Pract.* 2018;21(1):69–82. <https://doi.org/10.1016/j.cvex.2017.08.002>

Künzel F, Joachim A. *Encephalitozoonosis* in rabbits. *Parasitol Res.* 2010;106(2):299–309. <https://doi.org/10.1007/s00436-009-1679-3>

Latney L, Bradley C, Wyre N. Encephalitozoon cuniculi in pet rabbits: diagnosis and optimal management. *Vet Med (Auckl)*. 2014;5:169–180. <https://doi.org/10.2147%2FVMMR.S49842>

Ledbetter E, De Matos R, Gomes FE. Phacoemulsification of bilateral cataracts in two pet rabbits. *Open Vet J*. 2018;8(2):125–130. <https://doi.org/10.4314%2Fovj.v8i2.2>

Maggio, Federica, 2015. Glaucomas. *Top Companion Anim Med*. 2015;30(3):86–96. <https://doi.org/10.1053/j.tcam.2015.07.011>

Maini S, Hartley C. Guide to ophthalmology in rabbits. *In Pract*. 2019;41(7):310–320.

Mancinelli E. Diagnosing Encephalitozoon cuniculi infection in rabbits. *Vet Times*. 2015;1–12.

Miller PE, Stanz KM, Dubielzig RR et al. Mechanisms of acute intraocular pressure increases after phacoemulsification lens extraction in dogs. *Am J Vet Res*. 1997;58(10):1159–1165.

Mitchell N. Enucleation in companion animals. *Irish Veterinary J*. 2008;61(2):108–114.

Özkan O, Karagoz A, Kocak N. First molecular evidence of ocular transmission of Encephalitozoonosis during the intrauterine period in rabbits. *Parasit Int*. 2019;71:1–4. <https://doi.org/10.1016/j.parint.2019.03.006>

Özkan O, Alcigir ME. Subacute stage of Encephalitozoon cuniculi infection in eye lesions of rabbit in Turkey. *Iran J Parasitol*. 2018;13(2):301–309.

Safatle AMV, de Moraes, Eyheravine AR et al. Grating Visual Acuity in phakic, aphakic, and pseudophakic Poodles. *Veterinary Ophthalmology*. 2020;23(5):879–883. <https://doi.org/10.1111/vop.12813>

Sanchez RF, Becker R, Dawson C et al. Calculation of posterior chamber intraocular lens (IOL) size and dioptric power for use in pet rabbits undergoing phacoemulsification. *Vet Ophthalmol*. 2017a;20(3):242–249. <https://doi.org/10.1111/vop.12405>

Sanchez FR, Everson R, Hedley J et al. Rabbits with naturally occurring cataracts referred for phacoemulsification and intraocular lens implantation: a preliminary study of 12 cases. *Vet Ophthalmol*. 2018;21(4):399–412.

Sandmeyer LS, Bauer BS, Grahn BH. Diagnostic Ophthalmology. *Can Vet J*. 2011;52(3):27–328.

Snowden KF, Shadduck JA. Microsporidia in Higher Vertebrates. In: Wittner M, Weiss LM. *Microsporidia and Microsporidiosis*. Chichester, UK: John Wiley & Sons, Inc. 2014;469–491.

Van Der Woerd A. Lens-induced uveitis. *Vet Ophthalmol*. 2000;3(4):227–234. <https://doi.org/10.1046/j.1463-5224.2000.00107.x>

Varga M. Infectious Diseases of Domestic Rabbits. In: Varga M. *Textbook of Rabbit Medicine* (2nd edn). Oxford UK, Butterworth-Heinemann, 2013;435–471.

Vergneau-Grosset C, Sylvain, L. Microsporidiosis in vertebrate companion exotic animals. J Fungi (Basel). 2016;2(1):3. <https://doi.org/10.3390%2Fjof2010003>

Wilcock B, Peiffer R. The Pathology of Lens-induced Uveitis in Dogs. Vet Pathol. 1987;24(6):549-553. <https://doi.org/10.3390%2Fjof2010003>

Williams DL. The Rabbit Eye. In: Ophthalmology of Exotic Pets. West Sussex, UK: John Wiley & Sons Ltd. 2012;15–55.

Wolfer J, Grahn B, Wilcock B, Percy D. Phacoclastic uveitis in the rabbit. Prog Vet Comp Ophthalmol. 1993;3(3):92-97.

Wormstone IM, Wormstone YM, Smith AJO, Eldred JA. Posterior capsule opacification: What's in the bag? Prog Retin Eye Res. 2021;82:100905. <https://doi.org/10.1016/j.preteyeres.2020.100905>