



THE UNIVERSITY *of* EDINBURGH

## Edinburgh Research Explorer

# Imaging findings and clinical outcome of foot pain attributable to insertional deep digital flexor tendon injury and/or fluid signal within the flexor surface of the distal phalanx

### Citation for published version:

Hewitt-Dedman, C, Biggi, M, Van Zadelhoff, C, Schwarz, T, Reardon, R & Taylor, S 2021, 'Imaging findings and clinical outcome of foot pain attributable to insertional deep digital flexor tendon injury and/or fluid signal within the flexor surface of the distal phalanx', *Equine Veterinary Education*.  
<https://doi.org/10.1111/eve.13503>

### Digital Object Identifier (DOI):

[10.1111/eve.13503](https://doi.org/10.1111/eve.13503)

### Link:

[Link to publication record in Edinburgh Research Explorer](#)

### Document Version:

Publisher's PDF, also known as Version of record

### Published In:

Equine Veterinary Education

### Publisher Rights Statement:

This is an open access article under the terms of the Creative Commons Attribution License, which permits use, distribution and reproduction in any medium, provided the original work is properly cited.

### General rights

Copyright for the publications made accessible via the Edinburgh Research Explorer is retained by the author(s) and / or other copyright owners and it is a condition of accessing these publications that users recognise and abide by the legal requirements associated with these rights.

### Take down policy

The University of Edinburgh has made every reasonable effort to ensure that Edinburgh Research Explorer content complies with UK legislation. If you believe that the public display of this file breaches copyright please contact [openaccess@ed.ac.uk](mailto:openaccess@ed.ac.uk) providing details, and we will remove access to the work immediately and investigate your claim.



## Original Article

# Imaging findings and clinical outcome of foot pain attributable to insertional deep digital flexor tendon injury and/or fluid signal within the flexor surface of the distal phalanx

C. L. Hewitt-Dedman<sup>†\*</sup> , M. Biggi<sup>‡</sup>, C. Van Zadelhoff<sup>†</sup>, T. S. Schwarz<sup>†</sup>, R. J. M. Reardon<sup>†</sup> and S. E. Taylor<sup>†</sup>

<sup>†</sup>Royal (Dick) School of Veterinary Studies and Roslin Institute, The University of Edinburgh, Roslin; and <sup>‡</sup>VetCT, St John's Innovation Centre, Cambridge, UK

\*Corresponding author email: charlotte.hewitt-dedman@ed.ac.uk

**Keywords:** horse; deep digital flexor tendon; prognosis; MRI; magnetic resonance imaging

## Summary

**Background:** Insertional deep digital flexor tendon (DDFT) lesions with concurrent injury to the flexor surface of the distal phalanx are uncommon and there is limited information regarding prognosis.

**Objectives:** To provide descriptive data on horses with insertional DDFT injuries and determine whether there is any association between magnetic resonance imaging (MRI) findings, and outcome.

**Study design:** Retrospective case series.

**Methods:** Horses with lameness localised to the foot that underwent low field standing MRI between January 2015 and April 2019 were included. Injury of the DDFT, presence of short tau inversion recovery (STIR) hyperintensity at the flexor surface of the distal phalanx and concurrent lesions were recorded. Follow-up information was obtained by telephone questionnaire.

**Results:** Thirty-two horses fulfilled the inclusion criteria. Thirty-one limbs had DDFT insertional lesions on MRI with three limbs showing hyperintense STIR signal of the flexor surface of the distal phalanx without a tendon lesion. Seventeen DDFT lesions were graded as mild and 14 as severe. Thirteen limbs showed hyperintense STIR signal within the tendon and 15 limbs showed hyperintense STIR signal within the flexor surface of the distal phalanx at the insertion of the DDFT and/or the distal sesamoidean impar ligament (DSIL). Eight horses returned to previous athletic function, 8 returned to a lower level of athletic activity, 4 were retired, 9 were subjected to euthanasia and 3 were lost to follow-up. No significant association was found between DDFT lesion severity, hyperintense STIR signal within the DDFT, hyperintense STIR signal at the flexor surface of the distal phalanx and outcome post-injury.

**Main limitations:** Small sample size and reliance on clients to provide accurate follow-up information.

**Conclusions:** Insertional DDF tendinopathy carries a guarded prognosis for return to previous athletic function. The presence of hyperintense STIR signal at the flexor surface of the distal phalanx did not appear to influence the prognosis.

## Clinical relevance

- This study provides further descriptive data, highlighting the role of low field MRI in the diagnosis of DDFT insertional injuries.
- Concurrent signal of the flexor surface of the distal phalanx is not well described in the current literature and, to the authors' knowledge, this is the first study reporting outcomes for DDFT injuries with and without hyperintense STIR signal of the flexor surface of the distal phalanx at the insertion of the DDFT and/or the DSIL.
- This study adds support to the use of STIR signal resolution in the DDFT as an indicator of tendon healing.

## Introduction

Deep digital flexor tendon (DDFT) injuries are a common cause of foot lameness in the horse (Dyson *et al.* 2005; Mair and Kinns 2005). DDFT tendinopathy was considered the primary cause of lameness in 33% of 199 horses with foot pain presented for MRI in one study (Dyson *et al.* 2005) and in 21% of 84 horses with undiagnosed foot pain following radiographic and ultrasonographic examination in another study (Mair and Kinns 2005). Four main lesion types have been reported in the distal DDFT: core lesions, dorsal border lesions, sagittal plane and oblique splits and insertional lesions (Schramme 2011). Insertional lesions are located in the most distal 20mm of the DDFT and include small core lesions or sagittal plane splits; concurrent osseous remodelling of the distal phalanx can occasionally be present. These lesions can be found in isolation or in association with pathology in other portions of the DDFT (Blunden *et al.* 2009; Schramme 2011). One study looking at MR images of 46 horses with lameness

localised to the foot, found of those 32 horses with a primary DDFT lesion, one was confined to the insertion (3.1%) whilst 16 horses had both insertional and more proximal lesions (50%) (Dyson *et al.* 2003). In a study examining DDFT lesion types and locations, 9% of the 168 horses diagnosed with DDFT lesions using MRI were found to have primary insertional lesions (Cillán-García *et al.* 2013). In another study evaluating 188 limbs with DDFT injury, 84 limbs had injuries distal to the navicular bone of which 63% were core lesions, 35% were sagittal splits and 2% were dorsal border lesions (Lutter *et al.* 2015).

The mainstay of treatment for horses with DDFT injuries is a long period of rest followed by a period of controlled walking exercise, usually over a period of 6–12 months (Cillán-García *et al.* 2013). Maintenance of good foot balance is essential during this time (Schramme 2011; Lutter *et al.* 2015). A guarded prognosis has been reported for return to previous levels of activity following a DDFT injury (25–39%) whilst there is a fair prognosis for return to a lower level of athletic activity (32.5–55%) (Dyson *et al.* 2005; Gutierrez-Nibeyro *et al.* 2010; Cillán-García *et al.* 2013). However, a more recent study reports better success rates for return to the previous levels of activity after DDFT injury (65%) (Lutter *et al.* 2015) which may be related to the relatively high number of Western performance horses included. A statistically significant association has been found between lesion type and outcome, with dorsal border lesions carrying a better prognosis for return to some level of athletic activity than core lesions or sagittal plane and oblique splits (Cillán-García *et al.* 2013).

Insertional DDFT lesions with concurrent injury to the flexor surface of the distal phalanx at the insertion of the DDFT and/or the DSIL is an uncommon cause of foot pain in the horse and there is limited information regarding prognosis post-injury. The presence of enthesopathy in either the presence and absence of tendinopathy as determined by increased STIR signal in the bone on MRI has been described in dogs and humans (Cunningham *et al.* 2007; de Bakker *et al.* 2014). The enthesis itself is the fibrous or fibrocartilaginous connective tissue between the bone and the tendon. The enthesis of the DDFT was considered too small to be reliably evaluated by low-field MRI; therefore, the authors chose to consider STIR signal within the flexor surface of the distal phalanx at the insertion of the DDFT or the DSIL as representative of enthesopathy or desmopathy, respectively. A micro tear of the DDFT may easily be missed on MRI whereas the fluid signal at the flexor surface is sometimes easier to see as previously described (Cunningham *et al.* 2007).

The objectives of this study were to: (1) provide descriptive data on horses with an insertional injury of the DDFT; and (2) determine whether there is any association between MRI findings, and outcome post-injury. It was hypothesised that the presence of a concurrent injury to the flexor surface of the distal phalanx in horses with a DDFT insertional lesion would not influence outcome post-injury.

## Materials and methods

### Data collection

Hospital records were reviewed for all horses presenting to The Dick Vet Equine Hospital for MRI of the foot between January 2015 and April 2019. Cases were included that

underwent low-field MRI (0.27T) of a fore or hind foot following a positive response to diagnostic analgesia of the palmar/plantar nerves at the level just proximal to the ungular cartilages or at the base of the proximal sesamoid bones, and that showed MRI evidence of insertional deep digital flexor tendinopathy and/or hyperintense STIR or T2\* signal within the spongiosa bone and/or the compacta bone of the flexor surface of the distal phalanx at the insertion of the DDFT or the DSIL as the most likely cause for the lameness. Contralateral limbs were only included if lameness was detected and a positive response to diagnostic analgesia was evident. All horses for which diagnostic analgesia of the palmar/plantar nerves at the level just proximal to the ungular cartilages was not performed underwent additional MRI examination of the pastern. Data for age, breed, sex, lameness duration, lameness grade (AAEP scale), response to diagnostic analgesia and treatment were collected from hospital records.

For the standing MRI examination, horses were sedated with acepromazine (Calmivet)<sup>1</sup> (0.4mg/kg bwt i.v.) 30 min prior to the examination. Immediately, prior to image acquisition horses were administered 40 µg/kg bwt romifidine (Sedivet)<sup>2</sup> and 0.01 mg/kg butorphanol (Butador)<sup>3</sup> intravenously. Additional romifidine and butorphanol were used as necessary to achieve an adequate plane of sedation. Unilateral or bilateral foot MRI was performed using a low field (0.27T) open magnet<sup>4</sup> using the following protocol: T1 weighted 3D gradient echo, T2 weighted fast spin echo (FSE), T2\*weighted 3D gradient echo and STIR FSE sequences in three orthogonal planes (transverse, dorsal and sagittal; **Table 1**).

The MR images for the included horses were evaluated within 24 h of the examination by a Specialist in Equine Surgery and a Specialist in Diagnostic imaging and the diagnoses agreed by consensus. For this study, the DDFT lesions were graded retrospectively by a Specialist in Equine Surgery and a Specialist in Diagnostic imaging as: mild if they were less than 30mm in length and severe if they were more than 30 mm in length (Vanel *et al.* 2012). Location of the lesion and presence of hyperintense STIR signal were recorded (**Fig 1**). The flexor surface of the distal phalanx was subjectively graded using similar criteria to those previously described (Dyson *et al.* 2010) assessing endosteal irregularity, the presence of entheseous new bone, the presence of cystic structures and the presence of hyperintense STIR signal within the compact or spongiosa bone at the insertion of the DDFT or DSIL (**Fig 1**). The presence of fluid signal was further divided based on the anatomic locations of the insertion of the DDFT and DSIL using both sagittal STIR and T2\* sequences and transverse STIR and T2\* sequences. The presence of a moderate to marked hyperintense STIR signal within the spongiosa and/or flexor cortex of the navicular bone in STIR sequences was recorded, as were other concurrent lesions. The decision regarding primary lesions was based on the presence of fluid signal (either T2\*, T2 FSE or STIR) for both tendon lesions and concurrent lesions.

All horses underwent a period of rest following the diagnosis. This included a period of 3 months box or small paddock rest with short periods of in hand walking. Lameness re-evaluation was recommended after three months, prior to increasing the amount of exercise. If the lameness had improved sufficiently then a gradual return to full work was recommended over 6–9 months. Corrective farriery was

**TABLE 1: Pulse sequence parameters for low-field (0.27T) MRI open system**

Pulse sequence	Orientation	TE (ms)	TR (ms)	FOV (mm)	Flip angle (°)	ST (mm)	Gap (mm)
T1W 3D	S/F/T	8	24	170	45	1.5	1.5
T2W FSE	S/F/T	81	1848	170	90	5.0	6.0
T2*W 3D	S/F/T	13	34	170	25	3.0	3.0
STIR	S/F	27	3348	170	90	5.0	6.0

FOV, field of view; FSE, fast spin echo; ST, slice thickness; TE, echo time; TR, repetition time.

recommended to all horses which included correction of any mediolateral imbalance and application of slightly graduated heel shoes.

Follow-up information was obtained by a telephone questionnaire to all owners at a minimum of 12 months post-diagnosis. Five telephone attempts were made before the horse was classified as lost to follow-up. The owners were asked to classify outcome as returned to work at the same or higher level as pre-injury, returned to work at a lower level, retired or subjected to euthanasia. Owners were also asked whether the horse had suffered any other medical condition or injury since the MRI examination.

### Statistical analyses

Horses that were subjected to euthanasia immediately after diagnosis were excluded from the analyses. Horses that returned to work at the same or higher level were classified as Group 1 and horses that returned to work at a lower level, were retired or subjected to euthanasia following completion of the rehabilitation programme were classified as Group 2.

Fisher's exact tests were performed for lesion severity, presence of hyperintense STIR signal in the DDFT, presence of endosteal irregularity of the distal phalanx, presence of hyperintense STIR signal in the flexor surface of the distal phalanx at the insertion of the DDFT and/or the DSIL, presence of hyperintense STIR signal in the navicular bone, age, sex, lameness grade, lameness duration and outcome (Group 1 or 2) post-injury in all included horses for which follow-up was available. A  $p$ -value  $\leq 0.05$  was considered significant.

## Results

### Signalment and history

A total of 655 horses underwent MRI of the foot between January 2015 and April 2019 with 32 horses (4.9%) fulfilling the inclusion criteria. Of these 32 horses, 11 had bilateral front feet MRI studies, 18 had a unilateral forelimb MRI study and 3 had a unilateral hindlimb MRI study. Insertional deep digital flexor tendinopathy and/or hyperintense STIR signal of the flexor surface of the distal phalanx at the insertion of the DDFT and/or the DSIL was seen in 34 limbs. There were 18 geldings and 14 mares; the median age of included horses was 11 years (range 4–21 years). Breeds included 8 Warmbloods/Warmblood crosses, 6 Thoroughbred/Thoroughbred crosses, 6 Irish Sports Horses, 2 Arab crosses, 3 native breeds, 1 Cob and 6 of unknown breed. Nine horses were used for general purpose riding and hacking, 7 horses were used for dressage, 10 horses were used for jumping, 3 horses were used for eventing, 1 horse was used for hunting, 1 horse was used for endurance and the use of 1 horse was unknown. For the 23 horses for which lameness duration was recorded, 18 horses

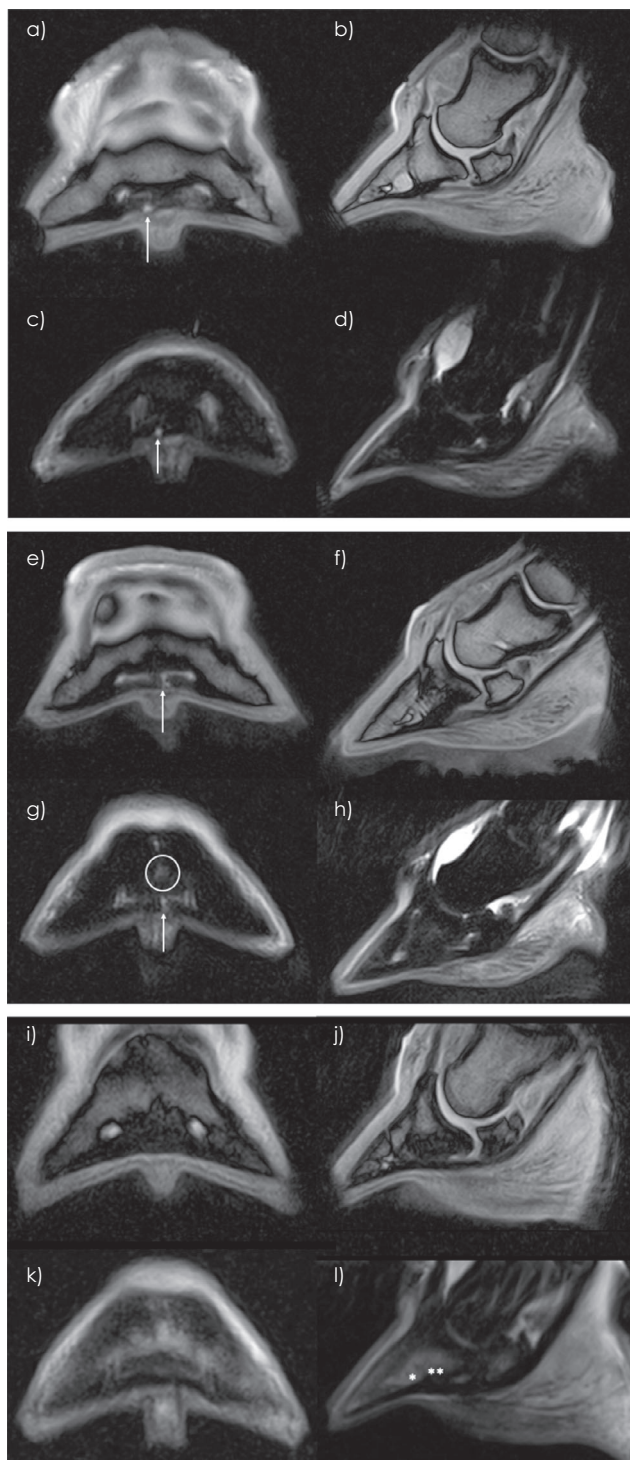
were presented for MRI examination within eight weeks of onset, whilst 5 horses were referred more than 8 weeks after onset of lameness. For the 18 horses for which lameness grade at presentation was recorded, a grade 2/5 was most common (range 1–3/5). Thirty horses had a unilateral lameness, 21 showed a positive response following a palmar digital nerve block and 9 showed a positive response following an abaxial sesamoid nerve block. Two horses were bilaterally lame and became sound following bilateral palmar digital nerve blocks.

### MRI findings

Thirty-one limbs showed evidence of a DDFT insertional lesion, 12 of which had hyperintense STIR signal of the flexor surface of the distal phalanx at the insertion of the DDFT and/or the DSIL and 3 limbs showed evidence of hyperintense STIR signal of the flexor surface of the distal phalanx at the insertion of the DDFT and/or the DSIL without evidence of a tendon lesion (**Fig 1**). Seventeen out of 31 (54.8%) DDFT insertional lesions were graded as mild whilst 14 were graded as severe. Ten limbs had dorsal border lesions, 9 limbs had parasagittal splits and 12 limbs had core lesions. Of the 14 limbs with severe DDFT lesions extending more proximally, 2 had only a dorsal border lesion, 1 had only a parasagittal split, 2 had only a core lesion, 2 had a parasagittal lesion at the insertion with a dorsal border lesion more proximally, 1 had a core lesion at the insertion and a parasagittal split more proximally, 2 had a dorsal border lesion at the insertion and both a core and dorsal border lesion evident more proximally, 2 had a core lesion at the insertion and both a core and dorsal border lesion evident more proximally, 1 had a parasagittal split at the insertion and both a dorsal border and parasagittal split more proximally and 1 had a core lesion at the insertion and both a parasagittal split and core lesion more proximally. The lateral lobe of the DDFT was affected in 20 limbs, the medial lobe was affected in 6 limbs and both lobes were affected in 5 limbs. Thirteen limbs showed hyperintense STIR signal within the tendon. When assessing the distal phalanx in all included limbs, there was no evidence of enthesioid new bone formation, however, 27 limbs showed evidence of endosteal irregularity of the flexor surface with 10 graded subjectively as mild, 12 as moderate and 5 as severe. Three limbs were found to have a cystic structure within the distal phalanx at the DDFT insertion. Fifteen limbs showed hyperintense STIR signal at the flexor surface of the distal phalanx. Four cases had STIR signal at the entheses of both the DDFT and DSIL, two cases had STIR signal at the enthesis of the DDFT but not the enthesis of the DSIL and nine cases had STIR signal at the enthesis of the DSIL but not the DDFT (**Supplementary Item 1**). Sixteen limbs had moderate or marked hyperintense STIR signal within the navicular bone that was considered clinically significant; 11 limbs had hyperintense STIR signal within the

spongiosa, 3 limbs had hyperintense STIR signal within the flexor cortex and 2 limbs had hyperintense STIR signal in both the spongiosa and palmar compacta.

Two limbs were found to have fragmentation of the distal border of the navicular bone, 1 limb was found to have fragmentation of the distal border of the navicular bone and navicular bursitis, 1 limb was found to have suspected navicular bursa fibrosis and 2 limbs (5.7%) had suspected

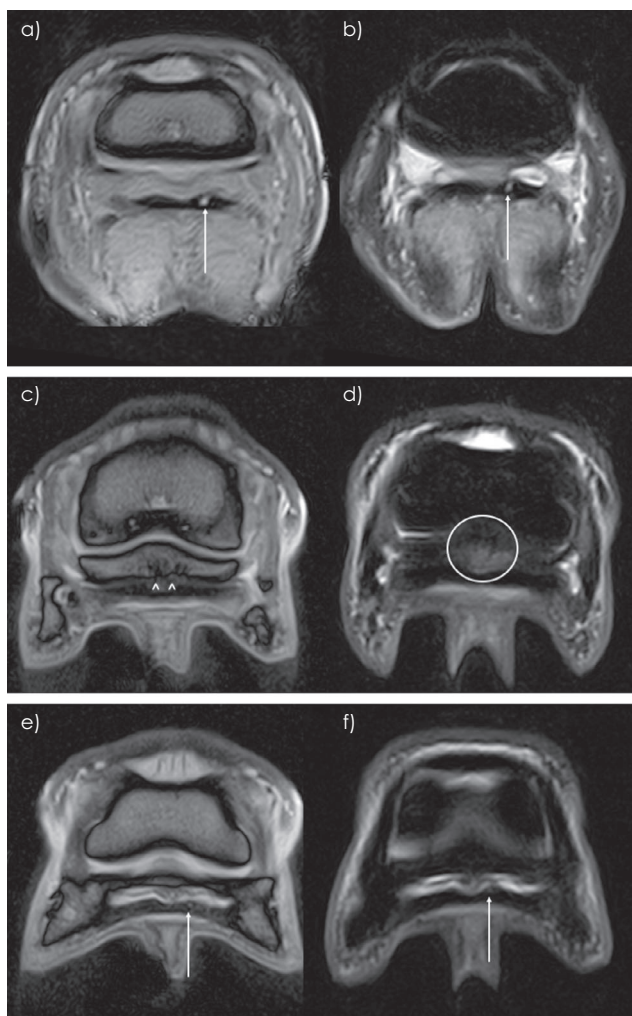


**Fig 1:** Transverse (a, e & i) and sagittal (b, f & j) T2\* weighted gradient echo high resolution and transverse (c, g & k) and sagittal (d, h & l) STIR fast spin echo sequences of three different horses acquired at the insertion of the deep digital flexor tendon (DDFT). a–d) Right front foot of horse one showing active insertional injury in the lateral lobe of the DDFT with increased signal intensity seen within the tendon on both sequences (arrows) and normal appearance of the flexor surface of the distal phalanx. e–h) Left front foot of horse two showing similar insertional injury in the lateral lobe of the DDFT (arrows) and presence of hyperintense STIR signal within the flexor surface of the distal phalanx (circled) at the insertion of the DSIL. i–l) Left hind foot of horse three showing marked increase in STIR signal and reduction in T2\* signal at the flexor surface of the distal phalanx at the insertions of both the DDFT(\*) and DSIL(\*\*). No increase in signal was identified within the DDFT of horse 3 on any sequence type.

adhesions (**Fig 2**) between the navicular bone and the DDFT. Other abnormalities included osteoarthritis of the distal interphalangeal joint (n = 6), osteoarthritis of the proximal interphalangeal joint (n = 3), desmopathy of the DSIL (n = 12), desmopathy of the lateral collateral ligament of the distal interphalangeal joint (n = 1) and chronic enthesopathy of the lateral collateral ligament of the distal interphalangeal joint (n = 1).

Five horses underwent repeat MRI examination 3–11 months following the first examination. Three of these horses showed minimal improvement in MRI findings and were still lame. One of these horses was subjected to euthanasia after the re-examination, one returned to light work and the other eventually returned to previous levels of activity. Two of the five horses were clinically sound at the examination and showed an improvement in MRI findings. One of these horses showed evidence of a DDFT insertional lesion with the presence of hyperintense STIR signal within the tendon during the first examination with the STIR signal having resolved by the second examination at 3 months. The other horse showed evidence of hyperintense STIR signal of the flexor surface of the distal phalanx at the enthesis of the DDFT without evidence of a tendon lesion. This hyperintense STIR signal had significantly reduced by the re-examination at 3 months. Both of these horses returned to their previous levels of work. One horse had two repeat MRI examinations at four and nine months after the first examination. At both examinations, the horse was sound at walk but remained lame at trot and an improvement in STIR signal in the distal phalanx was evident at the first rescan, however, the insertional DDFT lesion appeared unchanged on both rescans and the horse was subjected to euthanasia due to ongoing lameness. One horse had three repeat MRI examinations at 3, 10 and 23 months after the first examination (**Fig 3**). At three months, the horse was still lame and the DDFT lesion appeared more extensive with an increase in hyperintense signal on T2 FSE and STIR sequences as well hyperintense STIR signal at the flexor surface of the distal phalanx at the insertion of the DSIL. At 10 months, the DDFT lesion was still visible but had reduced in cross-sectional area. The hyperintense signal on T2\* and STIR sequences was less severe and the hyperintense STIR signal within the distal phalanx had resolved. By 23 months, the lesion had improved





**Fig 2:** Transverse T2\* weighted gradient echo high resolution (a, c, e) and STIR sequences (b, d, f) of the right fore foot. a and b) level of the proximal recess of the navicular bursa. A dorsal border lesion with an active core lesion, hyperintense on both T2\* and STIR images, is present in the medial lobe (arrows). c and d) level of the navicular bone. The flexor surface of the navicular bone is irregular and the borders of the DDFT and navicular bone are poorly defined suggestive of adhesion formation (arrowheads); moderate increased STIR signal intensity is present in the axial portion of the navicular bone spongiosa (circled). e and f) level with the distal sesamoidean impar ligament. A small T2\* and hyperintense STIR lesion is present in the dorsal aspect of the medial lobe of the tendon (arrows).

with resolution of hyperintense T2\* and STIR signal (**Fig 3**). The horse was sound at the third scan and has since returned to previous levels of work.

### Outcome

Follow-up data were available for 29/32 horses. The median follow-up time was 3 years with a range of 12 months to 5 years. Five horses were subjected to euthanasia at the time of diagnosis at the owners request due to the guarded prognosis given and prolonged rehabilitation required. Of the remaining horses, 8/24 horses (33.3%) returned to work at the same level, 8 horses (33.3%) returned to work at a lower level,

4 horses (16.7%) were retired and 4 horses (16.7%) were subjected to euthanasia after completion of the initial rehabilitation programme. For the purposes of statistical analysis, 8 (33.3%) horses were in Group 1 and 12 (66.7%) were in Group 2.

### Statistical analysis

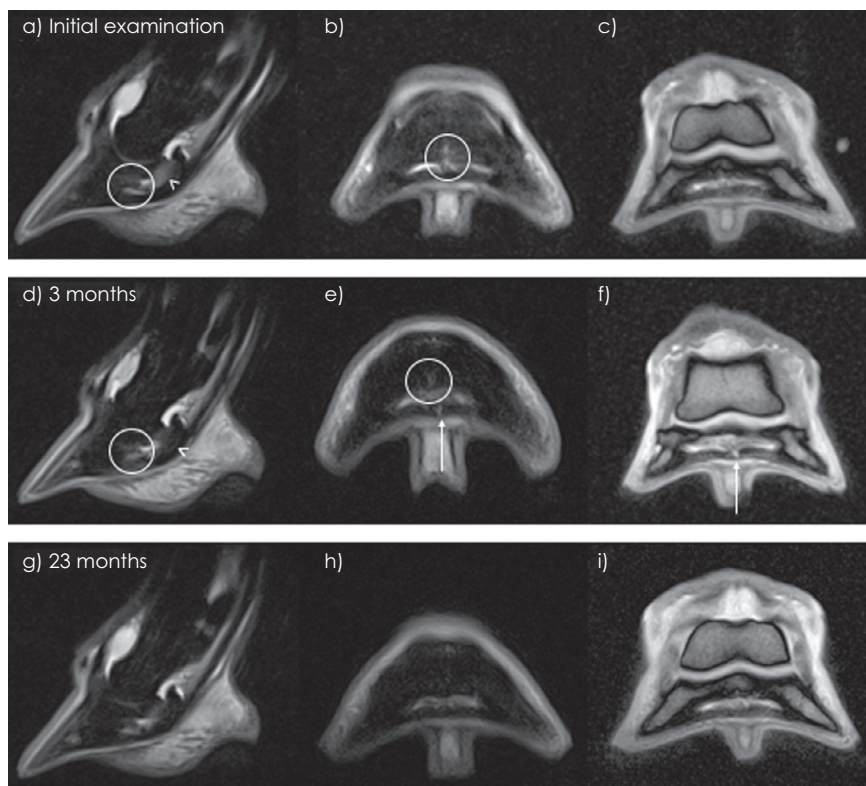
Twenty-four horses with follow-up data were included in the analysis (**Table 2**). Of the 8 horses with both a DDFT insertional lesion and hyperintense STIR signal of the flexor surface of the distal phalanx at the insertion of the DDFT and/or the DSIL, 3 (37.5%) returned to work at previous levels, 3/13 horses (23.0%) with only a DDFT insertional lesion returned to work at previous levels and 2/3 horses (66.6%) with only STIR signal of the flexor surface of the distal phalanx at the insertion of the DDFT and/or the DSIL returned to work at previous levels ( $p = 0.36$ ). No significant associations were found between outcome post-injury and: the severity of the DDFT lesion ( $p = 0.43$ ), the presence of hyperintense STIR signal within the DDFT ( $p = 0.39$ ), the presence of hyperintense STIR signal at the flexor surface of the distal phalanx at the insertion of the DDFT and/or the DSIL ( $p = 0.39$ ), the presence of endosteal irregularity and their severity ( $p = 0.24$ ), concurrent navicular bone abnormalities ( $p = 0.41$ ), the presence of hyperintense STIR signal within the navicular bone ( $p = 1.0$ ), age ( $p = 1.0$ ), sex ( $p = 0.39$ ), lameness grade ( $p = 0.09$ ) or duration of lameness ( $p = 1.0$ ).

### Discussion

This study found no association between the presence of hyperintense STIR signal at the flexor surface of the distal phalanx at the insertion of the DDFT and/or the DSIL and outcome post-injury suggesting that the presence of a concurrent injury to the flexor surface of the distal phalanx in horses with a DDFT insertional lesion does not influence outcome post-injury, albeit in a relatively small number of horses. In this study, the presence of STIR signal of the flexor surface of the distal phalanx at the insertion of the DDFT or the DSIL without a concurrent tendon lesion had a good prognosis (66.6%) for return to previous levels of work. Concurrent signal of the flexor surface of the distal phalanx is not well described in current literature and, to the authors' knowledge, this is the first study reporting outcomes for DDFT injuries with and without hyperintense STIR signal of the flexor surface of the distal phalanx at the insertion of the DDFT or the DSIL.

Only 32/655 (4.9%) horses were found to have insertional lesions of the DDFT. This is lower than previously reported by others: 37.1% (Dyson and Murray 2007) and 9% (Cillán-García *et al.* 2013), with a study looking at DDFT lesions diagnosed on high-field MRI reporting that 44.7% of lesions were located distal to the navicular bone (Lutter *et al.* 2015). This difference in frequency may be due to the horse populations, magnet field strength affecting slice thickness or perhaps the inclusion criteria. Additionally, the earlier study included lesions that were not considered the likely cause of lameness (Dyson and Murray 2007).

The current study found that overall 33.3% of horses with insertional lesions returned to work at the same level. However, it should be remembered that 5 horses of a relatively small population were excluded from analyses as they were subjected to euthanasia at the owners' request



**Fig 3:** Sagittal STIR (a,d,g), transverse STIR (b,e,h) and T2\*W GRE high resolution (c,f,i) sequences at the level of the deep digital flexor tendon insertion of the left front foot showing lesion progression from initial injury up to 23 months post-injury. a and b) Hyperintense STIR signal intensity is present in the flexor surface of the distal phalanx (circled) and in the navicular bone (arrowhead). The deep digital flexor tendon is normal. d–f) Images acquired 3 months post-diagnosis; a small core lesion is visible at the DDFT insertion axially hyperintense in both T2\*GRE and STIR sequences (arrows). The STIR signal within the flexor surface of the distal phalanx (circled) and navicular bone (arrowhead) is slightly improved but still present. g–i) Images acquired 23 months post-diagnosis; the tendon lesion is no longer active and the STIR signal intensity in the flexor surface has reduced; mild STIR signal remains in the navicular bone.

introducing bias to the study. It is unknown if this has negatively or positively influenced the findings of the current study. The rate of return to work at the previous level was the same for the horses where only the insertional part of the DDFT was involved as well as the horses with severe insertional lesions where other portions of the DDFT were also affected. This is similar to the range of values previously reported when considering all types of DDFT lesions: 25% (Cillán-García *et al.* 2013), 28% (Dyson *et al.* 2005) and 39.3% (Gutiérrez-Nibeyro *et al.* 2010). One study of mostly Quarter Horses reported a significantly better rate of return to previous activity (65%), with a non-significantly higher percentage of horses with lesions distal to the navicular bone returning to work (83%) compared to those with lesions above the navicular bone (53%) (Lutter *et al.* 2015). Follow-up time, outcome measures and horse population differ between these studies therefore direct comparisons are difficult.

The current study suggests that insertional lesions carry a guarded prognosis for return to previous levels of work in line with all types of DDFT injury in other studies; however, further studies with more horses, a veterinary recheck evaluation and a longer follow-up period would be required to confirm this. Forty percent of horses in this study returned to a lower level of work suggesting that horses with DDFT insertional lesions with or without hyperintense STIR signal of the flexor surface of the distal phalanx at the insertion of the DDFT or the DSIL

have a good prognosis for a return to work at some level. This is similar to previously reported results for rate of return to work at a lower level in horses with all types of DDFT lesion: 55% (Cillán-García *et al.* 2013) and 32.2% (Gutiérrez-Nibeyro *et al.* 2010). It was also previously shown that horses with a DDFT lesion at the level of the navicular bone were more likely to return to work at the previous level compared to horses with lesions in other locations including insertional lesions (Cillán-García *et al.* 2013).

No association was found between lesion severity and outcome post-injury. In this study lesion severity was determined by lesion length with severe lesions classified as >30 mm in length. Previously, a negative association has been found between lesion length and outcome with no horse with a lesion >30 mm in length returning to previous levels of activity (Vanel *et al.* 2012). Additionally, in a study looking at endoscopic evaluation of the navicular bursa, horses with extensive DDFT tears were less likely to return to soundness (54%) than horses with small tears (92%) (Smith and Wright 2012). The same conclusion cannot be drawn from the current study when solely considering lesions that affect the insertional portion of the DDFT.

No association was found between the presence of hyperintense signal within the DDFT at STIR sequences and outcome post-injury. A previous study (Vanel *et al.* 2012) found an association between resolution of signal within

**TABLE 2: Relationship between specific MRI findings and outcome for the 24 horses included in Group 1 and Group 2. Horses that were euthanised immediately following diagnosis (n = 5) or horses that were lost to follow-up (n = 3) are excluded from this analysis**

Variable	Group 1	Group 2	p value
	Horses that returned to work at same level (n)	Horses that returned to work at lower level or were retired (n)	
DDFT Lesion (n = 24)			
Absent	2	1	0.43
Mild	3	9	
Severe	3	6	
STIR Signal in DDFT (n = 24)			
Yes	5	6	0.39
No	3	10	
STIR Signal in flexor surface of distal phalanx (n = 24)			
Yes	5	6	0.39
No	3	10	
DDFT Lesion and STIR Signal in flexor surface of distal phalanx (n = 24)			
DDFT insertional lesion with STIR signal in flexor surface of distal phalanx	3	5	0.36
DDFT insertional lesion alone	3	10	
STIR signal in flexor surface of distal phalanx alone	2	1	
Endosteal Irregularity (n = 24)			
Absent	0	6	0.24
Mild	3	4	
Moderate	5	3	
Severe	0	3	
Concurrent navicular bone pathology (n = 24)			
Yes	4	11	0.41
No	4	5	
STIR signal in navicular bone (n = 24)			
Yes	3	6	1.00
No	5	10	
Age (n = 24)			
Less than 11 years	3	5	1.00
11 years and over	5	11	
Sex (n = 24)			
Gelding	6	8	0.39
Mare	2	8	
Lameness grade (n = 14)			
1/5	0	4	0.09
2/5	5	3	
3/5	0	2	
4/5	0	0	
5/5	0	0	
Duration of lameness (n = 18)			
0-8 weeks	4	10	0.57
>8 weeks	2	2	

tendons and ligaments on STIR sequences and return to soundness, however, a similar association was not found for STIR signal within bone, although this study did not include any bone lesions within the distal phalanx (Holowinski *et al.* 2010). In the current study, findings from 7 horses that underwent follow-up MRI scans have been reported. For all horses that appeared sound at repeat MRI examination, STIR signal within the tendon had either resolved or was not reported on the first scan and STIR signal within the flexor surface of the distal phalanx had either resolved or significantly improved. It is thought that the resolution of STIR signal within a tendon or ligament is indicative of chronic tissue remodelling and this is supported by a study comparing MRI findings and histopathology where tissue necrosis was seen as an area of increased signal on STIR sequences and areas of fibroplasia and fibrocartilaginous metaplasia

appeared normal on STIR sequences (Blunden *et al.* 2009; Holowinski *et al.* 2010).

Of the 35 limbs with DDFT insertional lesions examined, 16 showed hyperintense signal within the navicular bone on STIR sequences. A mild increase in signal in the navicular bone for STIR sequences without other abnormalities has been reported as a common, non-significant finding, therefore only limbs with a moderate to marked increase in signal intensity were recorded in this study (Dyson *et al.* 2005). In that study, 14% of horses had lesions of both the DDFT and the navicular bone whilst an earlier paper by the same authors reported that 30.4% of horses had lesions of both the DDFT and navicular bone. The proportion was higher in the present study (45.7%). A previous study describing histopathological abnormalities of the DDFT has shown a strong correlation between lesions of the DDFT and lesions of the flexor aspect



of the navicular bone, suggesting that the disease process is linked (Blunden *et al.* 2006). Lesions of the DDFT at the level of the collateral sesamoidean ligament, distal sesamoidean ligament and navicular bone were more likely to be associated with navicular bone lesions than those located at the level of the insertion (Dyson and Murray 2007). Horses with lesions of both the DDFT and concurrent navicular bone pathology have been shown to be less likely to return to work at the same level compared with DDFT lesions alone (Smith and Wright 2012; Cillán-García *et al.* 2013). In the current study, only 28.6% of horses with concurrent navicular bone pathology returned to work at the same level compared to 66.7% of horses without navicular bone changes, however, this was not found to be statistically significant, likely because of the relatively small numbers of cases in this study.

A previous study has shown that increasing horse age and duration of lameness greater than 8 weeks prior to the first MR examination are negatively associated with prognosis (Cillán-García *et al.* 2013). Neither of these associations were found in the current study, however, only five horses presented with a lameness duration of greater than eight weeks therefore the number of horses for comparison was very low. This may have also led to a higher number of cases with hyperintense STIR signal at the flexor surface of the distal phalanx at the insertion of the DDFT or the DSIL, as, in our experience this can be associated with recent injury. Additionally, given that a longer duration of lameness is associated with a negative prognosis, this might also contribute to the slightly better outcome in the present study. A higher proportion (57.1%) of horses that were less than 11 years of age returned to work at previous levels compared to 30.8% of horses aged 11 years and over. Additionally, 50% of geldings were shown to return to work at the same level compared to only 25% of mares. These findings, although non-significant might be because owners elect to retire older horses or mares to become broodmares; however, DDFT age degeneration and loss of regenerative potential may also be considered (Smith *et al.* 1997; Ribitsch *et al.* 2020).

The major limitation in this study was the low number of horses that fit the inclusion criteria. Additionally, the retrospective nature of this study meant that factors such as time from injury to MRI examination as well as rehabilitation time were not consistent for each horse. The use of an owner questionnaire to assess outcome is not as accurate as a veterinary assessment. As previously discussed, insertional injuries of the DDFT are uncommon. As such, this study has looked at cases that showed MRI evidence of insertional deep digital flexor tendinopathy and/or hyperintense STIR or T2\* signal within the spongiosa bone and/or the compacta bone of the flexor surface of the distal phalanx at the insertion of the DDFT or the DSIL all together due to the low number of cases. It should be noted that each of these findings may have different implications on prognosis. Further investigation of insertional injuries is warranted with a larger population of horses and a longer follow-up time. Follow-up MRI scans would also be helpful to monitor injury progression in a larger number of cases. It should also be considered that the slice thickness of STIR sequences (5mm) and motion are inherent limitations of low-field MRI meaning that some lesions will have been undetected that may have been evident with high field MRI.

This study suggests that the presence of hyperintense STIR signal within the flexor surface of the distal phalanx at the insertion of the DDFT or the DSIL does not influence the

outcome for cases with insertional lesions of the DDFT. Additionally, horses with DDFT insertional lesions have a guarded prognosis for return to work at the same level as prior to injury and a good prognosis for return to work at some level. As previously reported, this study adds some support to the use of STIR signal resolution in the DDFT for prognosis formulation. Clarification of tendon healing would require histological analysis that was not possible in these clinical cases. Future work could aim to identify if this STIR signal within the flexor surface of the distal phalanx is an indication of injury to the distal sesamoidean impar ligament that may be underrepresented on low-field MRI using histology as the gold standard.

### Authors' declaration of interests

No conflicts of interest have been declared.

### Ethical animal research

Ethical approval to carry out this study was obtained from the Human Ethical Review Committee (HERC) at The Royal (Dick) School of Veterinary Studies, The University of Edinburgh. Project number: HERC\_366\_19.

### Acknowledgements

We would like to acknowledge the Horseracing Betting Levy Board for their generous funding of Charlotte Hewitt-Dedman's Clinical Scholarship.

### Authorship

C. Hewitt-Dedman, M. Biggi and S. Taylor coordinated the study design and study execution. M. Biggi and S. Taylor interpreted the magnetic resonance imaging scans with T. Schwarz and C. Van Zadelhoff also advising in this area. R. Reardon and C. Hewitt-Dedman performed the data analysis. All authors involved in preparation of the manuscript, primarily coordinated by C. Hewitt-Dedman and all authors approved the final manuscript.

### Manufacturers' addresses

<sup>1</sup>Vétoquinol, Towcester, UK.

<sup>2</sup>Boehringer Ingelheim, Bracknell, Berks., UK.

<sup>3</sup>Chanelle Pharma, Loughrea, Co Galway, Ireland.

<sup>4</sup>Hallmarq Veterinary Imaging, Guildford, UK.

### References

- Blunden, A., Dyson, S., Murray, R. and Schramme, M. (2006) Histopathology in horses with chronic palmar foot pain and age-matched controls. Part 2: the deep digital flexor tendon. *Equine Vet. J.* **38**, 23-27.
- Blunden, A., Murray, R. and Dyson, S. (2009) Lesions of the deep digital flexor tendon in the digit: a correlative MRI and post mortem study in control and lame horses. *Equine Vet. J.* **41**, 25-33.
- Cillán-García, E., Milner, P.J., Talbot, A., Tucker, R., Hendej, F., Boswell, J., Reardon, R.J.M. and Taylor, S.E. (2013) Deep digital flexor tendon injury within the hoof capsule; does lesion type or location predict prognosis? *Vet. Rec.* **173**, 70.
- Cunningham, P.M., Brennan, D., O'Connell, M., MacMahon, P., O'Neill, P. and Eustace, S. (2007) Patterns of bone and soft-tissue injury at the symphysis pubis in soccer players: observations at MRI. *Am. J. Roentgenol.* **188**, W291-W296.

- De Bakker, E., Gielen, I., Kromhout, K., van Bree, H. and van Ryssen, B. (2014) Magnetic resonance imaging of primary and concomitant flexor enthesopathy in the canine elbow. *Vet. Radiol. Ultrasound* **55**, 56-62.
- Dyson, S., Murray, R., Schramme, M. and Branch, M. (2003) Lameness in 46 horses associated with deep digital flexor tendonitis in the digit: diagnosis confirmed with magnetic resonance imaging. *Equine Vet. J.* **35**, 681-690.
- Dyson, S.J., Murray, R. and Schramme, M.C. (2005) Lameness associated with foot pain: results of magnetic resonance imaging in 199 horses (January 2001-December 2003) and response to treatment. *Equine Vet. J.* **37**, 113-121.
- Dyson, S. and Murray, R. (2007) Magnetic resonance imaging evaluation of 264 horses with foot pain: the podotrochlear apparatus, deep digital flexor tendon and collateral ligaments of the distal interphalangeal joint. *Equine Vet. J.* **39**, 340-343.
- Dyson, S., Pool, R., Blunden, T. and Murray, R. (2010) The distal sesamoidean impar ligament: comparison between its appearance on magnetic resonance imaging and histology of the axial third of the ligament. *Equine Vet. J.* **42**, 332-339.
- Gutierrez-Nibeyro, S.D., White, N.A. II and Werpy, N.M. (2010) Outcome of medical treatment for horses with foot pain: 56 cases. *Equine Vet. J.* **42**, 680-685.
- Holowinski, M., Judy, C., Saveraid, T. and Maranda, L. (2010) Resolution of lesions on stir images is associated with improved lameness status in horses. *Vet. Radiol. Ultrasound* **51**, 479-484.
- Lutter, J.D., Schneider, R.K., Sampson, S.N., Cary, J.A., Roberts, G.D. and Vahl, C.I. (2015) Medical treatment of horses with deep digital flexor tendon injuries diagnosed with high-field-strength magnetic resonance imaging: 118 cases (2000-2010). *J. Am. Vet. Med. Assoc.* **247**, 1309-1318.
- Mair, T.S. and Kinns, J. (2005) Deep digital flexor tendonitis in the equine foot diagnosed by low-field magnetic resonance imaging in the standing patient: 18 cases. *Vet. Radiol. Ultrasound* **46**, 458-466.
- Ribitsch, I., Gueltekin, S., Keith, M.F., Minichmair, K., Peham, C., Jenner, F. and Egerbacher, M. (2020) Age-related changes of tendon fibril micro-morphology and gene expression. *J. Anatomy* **236**, 688-700.
- Schramme, M.C. (2011) Deep digital flexor tendonopathy in the foot. *Equine Vet. Educ.* **23**, 403-415.
- Smith, M.R.W. and Wright, I.M. (2012) Endoscopic evaluation of the navicular bursa: Observations, treatment and outcome in 92 cases with identified pathology. *Equine Vet. J.* **44**, 339-345.
- Smith, R.K.W., Zunino, L., Webbon, P.M. and Heinegård, D. (1997) The distribution of Cartilage Oligomeric Matrix Protein (COMP) in tendon and its variation with tendon site, age and load. *Matrix Biol.* **16**, 255-271.
- Vanel, M., Olive, J., Gold, S., Mitchell, R.D. and Walker, L. (2012) Clinical significance and prognosis of deep digital flexor tendonopathy assessed over time using MRI. *Vet. Radiol. Ultrasound* **53**, 621-627.

### Supporting information

Additional Supporting Information may be found in the online version of this article at the publisher's website:

**Supplementary Item 1:** Distribution of hyperintense STIR signal and T2\* signal at the entheses of the deep digital flexor tendon (DDFT) and distal sesamoidean ligament (DSIL).