



THE UNIVERSITY *of* EDINBURGH

Edinburgh Research Explorer

Comparison of three methods of injecting the proximal interphalangeal joint in horses

Citation for published version:

Poore, LAB, Lambert, KL, Shaw, DJ & Weaver, M 2011, 'Comparison of three methods of injecting the proximal interphalangeal joint in horses', *Veterinary Record*, vol. 168, no. 11, pp. 302+. <https://doi.org/10.1136/vr.c6676>

Digital Object Identifier (DOI):

[10.1136/vr.c6676](https://doi.org/10.1136/vr.c6676)

Link:

[Link to publication record in Edinburgh Research Explorer](#)

Document Version:

Publisher's PDF, also known as Version of record

Published In:

Veterinary Record

General rights

Copyright for the publications made accessible via the Edinburgh Research Explorer is retained by the author(s) and / or other copyright owners and it is a condition of accessing these publications that users recognise and abide by the legal requirements associated with these rights.

Take down policy

The University of Edinburgh has made every reasonable effort to ensure that Edinburgh Research Explorer content complies with UK legislation. If you believe that the public display of this file breaches copyright please contact openaccess@ed.ac.uk providing details, and we will remove access to the work immediately and investigate your claim.



PAPER

Comparison of three methods of injecting the proximal interphalangeal joint in horses

L. A. B. Poore, K. L. Lambert, D. J. Shaw, M. P. Weaver

Veterinary Record (2011) 168, 302
cite as doi:
10.1136/vr.c6676

L. A. B. Poore,
K. L. Lambert,
D. J. Shaw,
M. P. Weaver,
Royal (Dick) School
of Veterinary Studies,
University of Edinburgh,
UK

E-mail for
correspondence:
martin.weaver@
ed.ac.uk

This is a summary
of a paper that is
published in full at
veterinaryrecord.bvpublications.com

Published Online First
March 9, 2011

Context

Injection of the proximal interphalangeal (PIP; pastern) joint with local anaesthetic agent may be necessary as part of lameness diagnosis in horses and arthrocentesis for analysis of synovial fluid may be required in animals with wounds in the pastern region. Perceptible effusion of the joint is rare and injection or arthrocentesis of the joint technically more demanding than for most of the other limb joints. Selection of the optimal approach is therefore important.

Three different approaches to the PIP joint have been described: dorsal midline through the common digital extensor tendon (CDE), dorsolateral (or dorsomedial) adjacent to the CDE, and palmaroproximal.

The objective of this study was to investigate the efficacy of the dorsal (midline), dorsolateral and proximal palmar approaches to the PIP joint using contrast radiography, as an aid to clinicians performing arthrocentesis or injection, especially for those with little or no prior experience of injecting this joint.

Main conclusion

If arthrocentesis or injection into the dorsal PIP pouch is to be performed then the dorsolateral approach is likely to have a higher success rate when used by inexperienced clinicians. If the palmaroproximal approach is used, a small volume of radiographic contrast agent should be included with the injection to allow subsequent radiographic monitoring of the injection location, regardless of operator experience.

Approach

Seventy-five equine distal limbs were collected from an abattoir. The limbs were clipped and the skin of the pastern region was prepared as for standard aseptic joint injection. Fifteen groups of five randomly allocated limbs were created. The operators were five veterinary students in their fifth year of study with no prior experience of joint injection. Each operator performed each of the three techniques on five limbs in a random order, determined by a simple draw before the first technique was performed.

The number of attempts required to insert the needle for each approach was recorded by observation. For all injections, 38 mm 20 gauge hypodermic needles (Kendall Monoject; Tyco Healthcare) were used. Once the needle was inserted to the satisfaction of the operator, 5 ml of iodixanol (Visipaque; Amersham Health) were injected. Subsequently, a lateromedial computed radiograph (CR) was obtained of each limb using a Gigantos x-ray generator (Siemens Aktiengesellschaft) centred on the PIP joint at a film-focus distance of 70cm and exposed at 60kV and 6mAs. The presence of contrast agent only in the joint, with no contrast agent in the digital flexor tendon sheath (DFTS), was considered confirmation of a successful injection.

Results

Levels of accuracy for the dorsal, dorsolateral and palmaroproximal approaches were 32, 48 and 36 per cent, respectively (Table 1). There was inadvertent injection of the DFTS using the palmaroproximal approach in 64 per cent

TABLE 1: Number of successful and unsuccessful needle insertions and inadvertent injections of the digital flexor tendon sheath (DFTS) in 75 equine limbs subdivided into the three described techniques

Technique	Number of successful needle insertions in 25 limbs (also expressed as % [95% exact binomial confidence interval] of attempts)	Number of unsuccessful needle insertions per limb	
		With inadvertent injection of DFTS	Without inadvertent injection of DFTS
Dorsal	8 (32 [14-54])	0	17
Dorsolateral	12 (48 [27-69])	0	13
Palmaroproximal	9 (36 [17-57])	16*	0

*Five of these attempts had contrast agent within the DFTS and the proximal interphalangeal joint so were classed as unsuccessful

of injections. The dorsolateral approach was associated with fewer needle manipulations.

Interpretation

The PIP joint was injected successfully using all three approaches. However, only the palmaroproximal approach resulted in contrast within the DFTS, and when the dorsal pouch of the joint was being injected, the dorsolateral approach required a lower mean number of needle manipulations. This is of relevance for the clinical situation, where reducing the time required and the necessity for potentially painful needle repositioning are important safety considerations for both the clinician and the patient.

A previous study comparing two approaches to the PIP joint found clear advantages to the palmaroproximal approach and did not report inadvertent injection of the tendon sheath. However, there were differences in methodology, with the previous study using dye injection and manual dissection of the joint and extracapsular tissues. We believe that contrast injection followed by radiography is a superior method of detecting extra-articular injection as dissection depends on every plane of tissue being meticulously exposed whereas any radiographic contrast is easily detected on a single radiograph. The authors suggest that the synovial fluid obtained more frequently via the palmaroproximal approach may in some instances originate not from the joint but from the sheath.

Inadvertent entry into the DFTS when injecting the PIP joint is a complication that has not been previously reported. One of the reasons for initiating the present study was a clinical case with a positive PIP joint block (using the palmaroproximal approach) where the site of pain was eventually confirmed to be necrosis of the proximal sesamoid bones. This study has shown how such a diagnostic error could occur. Accidental injection of nearby structures has been reported for other synovial injection techniques. When performing diagnostic analgesia to localise lameness in horses it is essential for diagnostic accuracy to know where local anaesthetic is being placed.

The relatively low rate of success with all three techniques is most likely a reflection of the operators' lack of experience combined with the challenging nature of injecting the PIP joint.



Comparison of three methods of injecting the proximal interphalangeal joint in horses

L. A. B. Poore, K. L. Lambert, D. J. Shaw, et al.

Veterinary Record 2011 168: 302 originally published online March 9, 2011

doi: 10.1136/vr.c6676

Updated information and services can be found at:

<http://veterinaryrecord.bmj.com/content/168/11/302.full.html>

These include:

References

This article cites 14 articles

<http://veterinaryrecord.bmj.com/content/168/11/302.full.html#ref-list-1>

Email alerting service

Receive free email alerts when new articles cite this article. Sign up in the box at the top right corner of the online article.

Notes

To request permissions go to:

<http://group.bmj.com/group/rights-licensing/permissions>

To order reprints go to:

<http://journals.bmj.com/cgi/reprintform>

To subscribe to BMJ go to:

<http://group.bmj.com/subscribe/>

Papers

Comparison of three methods of injecting the proximal interphalangeal joint in horses

L. A. B. Poore, K. L. Lambert, D. J. Shaw, M. P. Weaver

The efficacy of three methods of injecting the equine proximal interphalangeal (pastern) joint was compared using cadaver limbs. Five veterinary students without prior experience attempted to inject an aqueous radiographic contrast medium into the joint using five limbs for each technique. The number of attempts was recorded and successful injection of the joint was confirmed by the presence of intra-articular contrast on radiographic examination. Levels of accuracy for the dorsal, dorsolateral and palmaroproximal approaches were 32, 48 and 36 per cent, respectively. There was inadvertent injection of the digital flexor tendon sheath using the palmaroproximal approach in 64 per cent of injections. The dorsolateral approach was associated with fewer needle manipulations.

INJECTION of the proximal interphalangeal (pastern) joint with local anaesthetic agent may be necessary as a part of lameness diagnosis in horses, and arthrocentesis for analysis of synovial fluid may be required in animals with wounds located in the pastern region. The low-motion proximal interphalangeal joint is relatively narrow and is surrounded by dense ligaments and connective tissues (McIlwraith and Goodman 1989). Coursing over the dorsal pouch of the joint is the broad common digital extensor tendon. The palmar/plantar pouch, which extends proximally, is protected by the distal digital annular ligament, proximal attachment of the digital cushion and the deep digital flexor tendon within its sheath (Denoi 2000). Further support is provided by the medial and lateral collateral ligaments, which course obliquely in a palmaro- (plantaro-) distal direction from the distal depression and tuberosity on the first phalanx to their insertion on a similar tuberosity on the second phalanx (Ruggles 2003). The smaller axial and abaxial palmar/plantar ligaments are located just palmar (plantar) to the collateral ligaments (Nickel and others 1986, Ruggles 2003). The joint is innervated by the medial and lateral palmar (plantar) digital nerves and their dorsal branches (Sack 1975). The surrounding dense connective tissues mean perceptible effusion of the joint is rare (Miller and others 1996), and injection or arthrocentesis of the joint is technically more demanding than for most of the other limb joints (Bassage and Ross 2003). Therefore, selection of the optimal approach is important.

Three different approaches to the proximal interphalangeal joint have been described: dorsal midline through the common digital extensor tendon (Wheat and Jones 1981, Stashak 1987); dorsolateral (or dorsomedial) adjacent to the common digital extensor (Nickel and others 1986, Bassage and Ross 2003); and palmaroproximal (Miller

and others 1996). The proximopalmar (plantar) pouch is larger than the dorsal pouch (Boening 2005), suggesting that injection at this location may be more successful. Furthermore, the palmaroproximal approach was recommended following comparison with the dorsal (midline) approach using intra-articular dye injections because it was associated with fewer needle manipulations in both cadaver limbs and live horses and was more likely to result in synovial fluid at the needle hub (Miller and others 1996); however, the dorsolateral approach was not evaluated in that study.

The objective of this study was to investigate the efficacy of the dorsal (midline), dorsolateral and proximopalmar approaches to the proximal interphalangeal joint using contrast radiography, as an aid to clinicians performing arthrocentesis or injection, especially for those with little or no prior experience of injecting this joint.

Materials and methods

A total of 75 equine distal limbs were collected from an abattoir. The lameness history of the animals was unknown but none of the limbs had palpable abnormalities in the pastern region. The limbs were frozen at -20°C and subsequently thawed for 48 hours before use. The limbs were clipped and the skin of the pastern region was prepared as for standard aseptic joint injection. Fifteen groups of five randomly allocated limbs were created. During all attempts to inject the joint the limbs were held by the same assistant. The sole of the foot was parallel to the ground to mimic the weightbearing position for the dorsal and dorsolateral approaches, and the distal limb was placed in flexion for the palmaroproximal approach (Bassage and Ross 2003).

The operators were five veterinary students in their fifth year of study with no prior experience of joint injection in either live horses or cadaver limbs. Each operator performed each of the three techniques on five limbs in a random order, determined by a simple draw before the first technique was performed. All five operators were given the same briefing and written instructions with diagrams on the three injection techniques before the start of the study. In addition, each technique was demonstrated once to all operators by one of the authors (LABP) on an additional cadaver limb.

The number of attempts required to insert the needle for each approach was recorded by observation. Any redirection of the needle from the original direction of insertion was classified as a new attempt, even if the needle was not removed from the limb. The operators were permitted to make an unlimited number of attempts and were unaware of the results until the study was complete.

Veterinary Record (2011) 168, 302

doi: [10.1136/vr.c6676](https://doi.org/10.1136/vr.c6676)

L. A. B. Poore, MA, VetMB, MRCVS,
K. L. Lambert, BSc,

D. J. Shaw, BSc, PhD,

M. P. Weaver, BVMS, PhD, DrMedVet,
DVR, MRCVS,

Department of Veterinary Clinical
Sciences, Royal (Dick) School of
Veterinary Studies, University of
Edinburgh, Large Animal Hospital,
Easter Bush Veterinary Centre, Easter
Bush, Roslin, Midlothian EH25 9RG

Correspondence to Dr Weaver, e-mail:
martin.weaver@ed.ac.uk

Provenance: not commissioned;
externally peer reviewed

Published Online First March 9, 2011

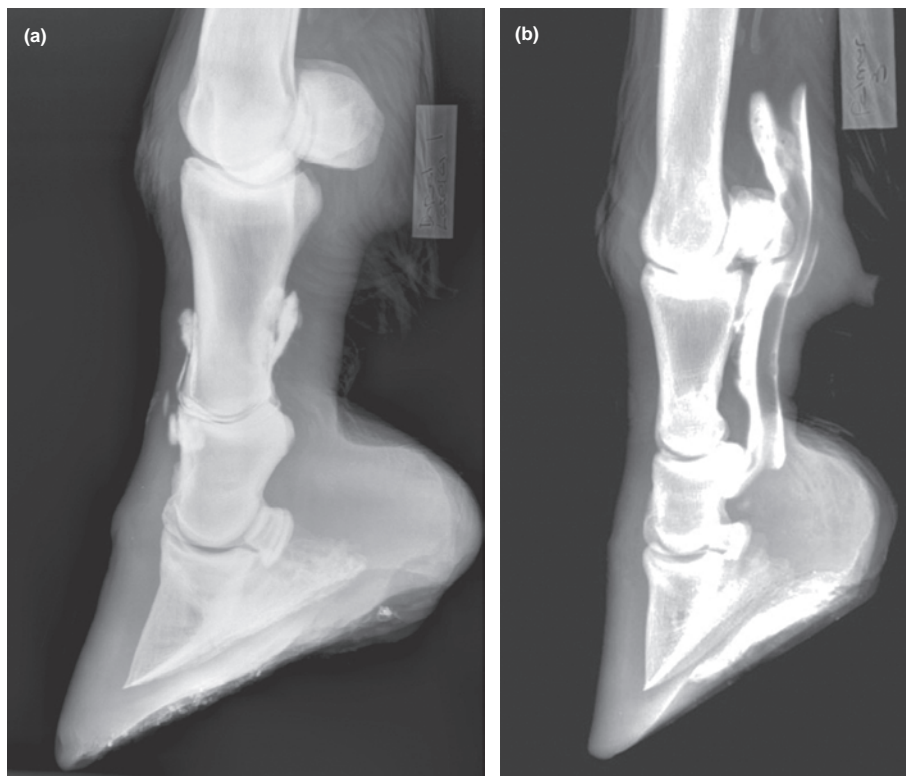


FIG 1: Lateromedial radiographic views of two cadaver distal equine limbs showing the presence of (a) contrast agent in the dorsal and palmar joint pouches following successful injection, and (b) contrast within the digital flexor tendon sheath indicating an unsuccessful injection

For the dorsal approach, the needle was inserted on the midline approximately 0.5 cm proximal to the level of the medial and lateral eminences of the proximal end of the middle phalanx. The needle was directed slightly distally and medially through the common digital extensor tendon to enter the dorsal joint pouch. To perform the dorsolateral approach, the distal lateral condylar eminence of the proximal phalanx was palpated and the needle was inserted at this level parallel to the sole and directed palmar/plantar to the edge of the common digital extensor tendon to enter the dorsal pouch. To inject the proximal interphalangeal joint using the palmaroproximal approach, the needle was inserted in a medial direction into a palpable 'V'-shaped notch formed by the palmar aspect of the proximal phalanx dorsally, the distal eminence of the proximal phalanx and the lateral branch of the superficial digital flexor tendon close to its insertion on the palmaroproximal eminence of the middle phalanx.

For all injections, 38 mm 20 gauge hypodermic needles (Kendall Monoject; Tyco Healthcare) were used. Once the needle was inserted, 5 ml iodixanol (Visipaque; Amersham Health) was injected. The needle was considered by the operator to have been inserted into the joint space if injection of the contrast agent was met with little resistance, there was visible distension of a joint pouch or fluid could be retrieved following injection. Subsequently, a lateromedial computed radiograph (CR) of each limb was obtained using a Gigantox x-ray generator (Siemens Aktiengesellschaft) centred on the proximal interphalangeal joint at a film-focus distance of 70 cm and exposed at 60 kV and 6 mA. The presence of contrast agent only in the joint (with no contrast agent in the digital flexor tendon sheath) was considered confirmation of a successful injection (Fig 1a).

Statistical analysis

The frequency of injection into the proximal interphalangeal joint for each technique was compared using generalised linear mixed-effect (GLME) models. To determine whether the number of attempts differed between approaches, GLME models with Poisson errors were used to take into account the integer nature of the 'number of attempts' dataset. For analysis of whether the correct location of contrast (yes/no) was related to the approach, GLME models with bino-

mial errors were performed. To take into account the effect of a particular operator on either successful injection or the number of attempts to inject the joint, GLME models were produced where the operator was entered as the random effect. Values of $P < 0.05$ were considered significant.

Results

No joint abnormalities were detected on any of the radiographs that could have affected injection of individual joints. In the 25 limbs used for each injection technique, the dorsal, dorsolateral and palmaroproximal approaches resulted in successful injection in eight (32 per cent), 12 (48 per cent) and nine (36 per cent) limbs, respectively (Fig 1a). The average number of attempts required to inject the joint successfully from the three approaches were seven, five and four, respectively. There were significantly fewer attempts using the dorsolateral approach compared with the dorsal approach ($P < 0.001$), but no differences between the palmaroproximal and either the dorsal or the dorsolateral approach ($P > 0.06$). There were no significant differences in the percentage of limbs with correct location of contrast, either overall between all three approaches (Table 1) ($P = 0.5$) or when only dorsal and dorsolateral approaches were compared ($P = 0.2$). In addition, there was no significant association between the number of attempts and whether there was a successful injection ($P = 0.791$), regardless of whether only data from the dorsal and dorsolateral approaches were considered ($P = 0.859$), or if each approach was considered separately ($P > 0.050$) (Fig 2). There was also no significant interaction between the number of attempts and the approach with regard to the correct location of the contrast agent ($P = 0.079$). However, 64 per cent of the palmaroproximal injections were found to have inadvertently penetrated the digital flexor tendon sheath, whereas this did not occur with any of the dorsal or dorsolateral injections (Table 1, Fig 1b).

Discussion

In this study, the proximal interphalangeal joint could be injected successfully using all three approaches. However, only the palmaroproximal approach resulted in contrast within the digital flexor tendon sheath, and when the dorsal pouch of the joint was being injected, the dorsolateral approach required a lower mean number of needle manipulations. This is of relevance for the clinical situation, where reducing the time required and the necessity for potentially painful needle repositioning are important safety considerations for both the clinician and the horse. Both the dorsolateral and palmaroproximal approaches had more distinct anatomical landmarks for percutaneous penetration than the dorsal approach, possibly accounting for the reduced number of needle manipulations required for the dorsolateral approach, although the operators were not asked for their subjective views on which landmarks they felt were more prominent.

A previous study comparing two approaches to the proximal interphalangeal joint showed clear advantages to the palmaroproximal approach and did not report inadvertent injection of the tendon sheath (Miller and others 1996). However, there were differences in methodology, with the previous study using dye injection and manual dissection of the joint and extracapsular tissues. The authors believe that contrast injection followed by radiography is a superior method of detecting extra-articular injection, as dissection depends on every plane of tissue being meticulously exposed whereas any radiographic contrast is easily detected on a single radiograph. The authors suggest that the synovial fluid obtained more frequently through the palmaro-

TABLE 1: Number of successful and unsuccessful needle insertions and inadvertent injections of the digital flexor tendon sheath (DFTS) in 75 cadaver equine distal limbs subdivided into the three described techniques

Technique	Number of successful needle insertions in 25 limbs (also expressed as percentage [95 per cent exact binomial confidence interval] of attempts)	Number of unsuccessful needle insertions per limb	
		With inadvertent injection of DFTS	Without inadvertent injection of DFTS
Dorsal	8 (32 [14-54])	0	17
Dorsolateral	12 (48 [27-69])	0	13
Palmaroproximal	9 (36 [17-57])	16*	0

* Five of these attempts had contrast agent within the DFTS and the proximal interphalangeal joint, so were classed as unsuccessful

proximal approach may, in some instances, originate not from the joint but from the tendon sheath.

Inadvertent entry into the digital flexor tendon sheath when injecting the proximal interphalangeal joint is a complication that has not been previously reported. One of the reasons for initiating this study was a clinical case with a positive proximal interphalangeal joint block (using the palmaroproximal approach), where the site of pain was eventually confirmed to be necrosis of the proximal sesamoid bones. This study has shown how such a diagnostic error could occur. Accidental injection of nearby structures has been reported for other synovial injection techniques. Using a lateral approach to the distal interphalangeal joint in eight equine cadaver limbs resulted in radiographic contrast agent in the navicular bursa in two limbs and within the digital flexor tendon sheath in one limb, with similar results in vivo (Vazquez de Mercado and others 1998). Attempts to inject radiographic contrast into the navicular bursa of 33 feet in standing horses using two techniques (Piccot-Cr  zollet and others 2005) resulted in extrabursal contrast in 11 feet, including four cases with contrast within the distal interphalangeal joint. Similarly, injections of dye into the proximal palmar metacarpal region to investigate three techniques for analgesia produced distal carpal intra-articular dye at frequencies of 17 to 37 per cent, depending on technique (Ford and others 1989). When performing diagnostic analgesia to localise lameness in horses, it is essential for diagnostic accuracy to know where the local anaesthetic is being placed.

Other investigations of injection techniques have also used cadaver limbs, either exclusively (Ford and others 1989, Schramme and others 2000, Castro and others 2005) or in combination with standing horses (Miller and others 1996, Vazquez de Mercado and others 1998, Gandini 2007, Just and others 2007). Use of cadaver limbs eliminates some of the inherent variables in a study of this type, such as the temperament of live horses, which may be such that the investigation cannot be completed (Piccot-Cr  zollet and others 2005), or different clinical indications for arthrocentesis or injection (wounds, periarticular new bone). Also, current animal welfare legis-

lation in the UK would preclude performing this study in horses without clinical indication. Although the proximal interphalangeal joint is relatively small, the degree of joint distension is likely to be different in standing, weightbearing horses; however, the results of this cadaver study, such as the number of needle manipulations required, have direct relevance to the clinical situation with standing horses.

The use of students as operators in this study is perhaps a little more controversial. Comparable studies have used either experienced clinicians (Ford and others 1989, Dyson and Romero 1993, Schramme and

others 2000, Castro and others 2005, Piccot-Cr  zollet and others 2005, Gandini 2007, Just and others 2007), clinicians with no prior experience of injecting the structure under investigation (Schumacher and others 2007), students with no experience (Schramme and others 2000), a combination of students with a clinician (Gandini 2007) and some authors did not describe the prior experience of their operators (Miller and others 1996, Vazquez de Mercado and others 1998, Piccot-Cr  zollet and others 2005, Just and others 2007). The rationale for using inexperienced operators is that it eliminates another important variable: the level of prior experience with one of the three techniques being studied, as most experienced clinicians will favour one particular technique. It would be expected that operators with no experience would require more manipulations to achieve injection, and this was indeed the case. Depending on the technique, the operators in this study required a mean of four to seven attempts per injection, compared with mean values of 2.4 and 1.5 for cadaver injections by experienced clinicians in another study (Miller and others 1996). In contrast to the students reported here, five students injecting the navicular bursa took between 1.1 and 1.6 attempts to introduce the needle (Schramme and others 2000). One possible reason for this is that it is likely that the operators in the navicular bursa study took greater care to insert the needle, given the much greater depth of insertion using a longer needle (90 mm v 38 mm). The relatively low rate of success using all three techniques in the present study is most likely a reflection of the operators' lack of experience combined with the challenging nature of injecting this joint (Bassage and Ross 2003).

In conclusion, based on the results it is recommended that if the palmaroproximal approach is used, a small volume of radiographic contrast agent should be included with the injection to allow subsequent radiographic monitoring of the injection location, regardless of the operator's experience. If arthrocentesis or injection into the dorsal proximal interphalangeal pouch is to be performed, then the dorsolateral approach is likely to have a higher success rate when used by inexperienced clinicians.

Acknowledgements

The authors thank the final-year students who assisted with this study. LABP's residency was funded in part by World Horse Welfare.

References

- BASSAGE, L. H. & ROSS, M. W. (2003) Diagnostic analgesia. In *Diagnosis and Management of Lameness in the Horse*. Eds M. W. Ross, S. J. Dyson. Saunders. pp 93-124
- BOENING, K. J. (2005) Arthroscopic surgery of the distal and proximal interphalangeal joints. In *Diagnostic and Surgical Arthroscopy in the Horse*. Eds C. W. McIlwraith, A. J. Nixon, I. M. Wright, K. J. Boening. Mosby Elsevier. pp 347-364
- CASTRO, F. A., SCHUMACHER, J. S., PAUWELS, E & BLACKFORD, J. T. (2005) A new approach for perineural injection of the lateral palmar nerve in the horse. *Veterinary Surgery* **34**, 539-542
- DENOIX, J. M. (2000) The equine pastern. In *The Equine Distal Limb. An Atlas of Clinical Anatomy and Comparative Imaging*. Ed J. M. Denoix. Manson Press. pp 152-155
- DYSON, S. J. & ROMERO, J. M. (1993) An investigation of injection techniques for local analgesia of the equine distal tarsus and proximal metatarsus. *Equine Veterinary Journal* **25**, 30-35
- FORD, T. S., ROSS, M. W. & ORSINI, P. G. (1989) A comparison of methods for proximal palmar metacarpal analgesia in horses. *Veterinary Surgery* **18**, 146-150
- GANDINI, M. (2007) Comparison of three dorsal techniques for arthrocentesis of the distal interphalangeal joint in horses. *Journal of the American Veterinary Medical Association*

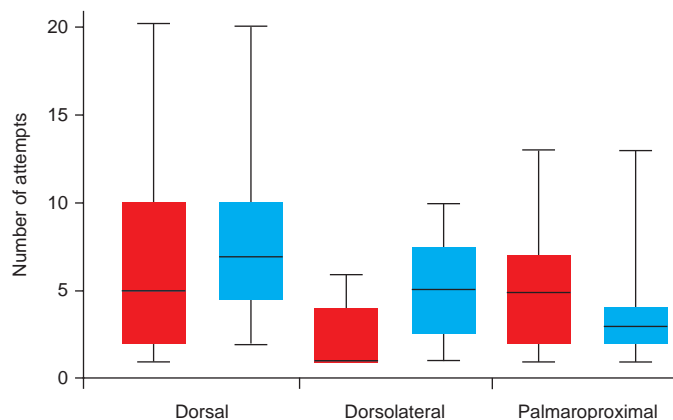


FIG 2: Boxplots of the number of attempts for successful (blue) and unsuccessful (red) injections of the proximal interphalangeal joint for each of the three techniques used in this study

- 231, 254-258
- JUST, E. M., PATAN, B. & LICKA, T. F. (2007) Dorsolateral approach for arthrocentesis of the centrodistal joint in horses. *American Journal of Veterinary Research* **68**, 946-952
- MCILWRAITH, C. W. & GOODMAN, N. L. (1989) Conditions of the interphalangeal joints. *Veterinary Clinics of North America: Equine Practice* **5**, 161-178
- MILLER, S. M., STOVER, S. M., TAYLOR, K. T. & ZARUCCO, L. A. (1996) Palmarproximal approach for arthrocentesis of the proximal interphalangeal joint in horses. *Equine Veterinary Journal* **28**, 376-380
- NICKEL, R., SCHUMMER, A., WILLE, K. H. & WILKENS, H. (1986) Digital joints of the horse. In *The Anatomy of the Domestic Animals*. Vol 1. Eds R. Nickel, A. Schummer, K. H. Wille, H. Wilkens. Paul Parey. pp 197-201
- PICCOT-CRÉZOLLET, C., CAUVIN, E. R. & LEPAGE, O. M. (2005) Comparison of two techniques for injection of the podotrochlear bursa in horses. *Journal of the American Veterinary Medical Association* **226**, 1524-1528
- RUGGLES, A. J. (2003) The proximal and middle phalanges and proximal interphalangeal joint. In *Diagnosis and Management of Lameness in the Horse*. Eds M. W. Ross, S. J. Dyson. Saunders. pp 342-348
- SACK, W. O. (1975) Nerve distribution in the metacarpus and front digit of the horse. *Journal of the American Veterinary Medical Association* **167**, 298-305
- SCHRAMME, M. C., BOSWELL, J. C., HAMHOUGIAS, K., TOULSON, K. & VIITANEN, M. (2000) An in vitro study to compare 5 different techniques for injection of the navicular bursa in the horse. *Equine Veterinary Journal* **32**, 263-267
- SCHUMACHER, J., LIVESEY, L., BRAWNER, W., TAINTOR, J. & PINTO, N. (2007) Comparison of 2 methods of centesis of the bursa of the biceps brachii tendon of horses. *Equine Veterinary Journal* **39**, 356-359
- STASHAK, T. S. (1987) Diagnosis of lameness. In *Adam's Lameness in Horses*. 4th edn. Ed T. S. Stashak. Lea & Febiger pp 146-147
- VAZQUEZ DE MERCADO, R., STOVER, S. M., TAYLOR, K. T., ZARUCCO, L. & WILLITS, N. H. (1998) Lateral approach for arthrocentesis of the distal interphalangeal joint in horses. *Journal of the American Veterinary Medical Association* **212**, 1413-1418
- WHEAT, J. D. & JONES, K. (1981) Selected techniques of regional anesthesia. *Veterinary Clinics of North America: Equine Practice* **3**, 223-230



Comparison of three methods of injecting the proximal interphalangeal joint in horses

L. A. B. Poore, K. L. Lambert, D. J. Shaw, et al.

Veterinary Record 2011 168: 302 originally published online March 9, 2011

doi: 10.1136/vr.c6676

Updated information and services can be found at:

<http://veterinaryrecord.bmj.com/content/168/11/302.full.html>

These include:

References

This article cites 14 articles

<http://veterinaryrecord.bmj.com/content/168/11/302.full.html#ref-list-1>

Email alerting service

Receive free email alerts when new articles cite this article. Sign up in the box at the top right corner of the online article.

Notes

To request permissions go to:

<http://group.bmj.com/group/rights-licensing/permissions>

To order reprints go to:

<http://journals.bmj.com/cgi/reprintform>

To subscribe to BMJ go to:

<http://group.bmj.com/subscribe/>