



THE UNIVERSITY *of* EDINBURGH

Edinburgh Research Explorer

Accuracy of ultrasound vs computed tomography scan for upper urinary tract malignancies and development of a risk-based diagnostic algorithm for haematuria in a UK tertiary centre

Citation for published version:

David, RA, James, B, Adeloje, D, Bose, P, Rai, B & Kandaswamy, GV 2020, 'Accuracy of ultrasound vs computed tomography scan for upper urinary tract malignancies and development of a risk-based diagnostic algorithm for haematuria in a UK tertiary centre', *International urology and nephrology*. <https://doi.org/10.1007/s11255-020-02615-7>

Digital Object Identifier (DOI):

[10.1007/s11255-020-02615-7](https://doi.org/10.1007/s11255-020-02615-7)

Link:

[Link to publication record in Edinburgh Research Explorer](#)

Document Version:

Peer reviewed version

Published In:

International urology and nephrology

General rights

Copyright for the publications made accessible via the Edinburgh Research Explorer is retained by the author(s) and / or other copyright owners and it is a condition of accessing these publications that users recognise and abide by the legal requirements associated with these rights.

Take down policy

The University of Edinburgh has made every reasonable effort to ensure that Edinburgh Research Explorer content complies with UK legislation. If you believe that the public display of this file breaches copyright please contact openaccess@ed.ac.uk providing details, and we will remove access to the work immediately and investigate your claim.



TITLE: Accuracy of ultrasound vs computed tomography scan for upper urinary tract malignancies and development of a risk-based diagnostic algorithm for haematuria in a UK tertiary centre

AUTHORS AND INSTITUTIONS

RA David^{a#,b}, B James^b, D Adeloey^c, P Bose^b, B Rai^d, GV KandaSwamy^b

^aUrology Department, Royal Bournemouth Hospital, Bournemouth, United Kingdom

^bUrology Department, Morriston Hospital, Swansea Bay University Health Board, Swansea, United Kingdom

^cCentre for Global Health, Usher Institute, University of Edinburgh, United Kingdom

^dUrology Department, Freeman Hospital, Newcastle Upon Tyne, United Kingdom

[#]Current address

CORRESPONDENCE

Dr Rotimi David

Department of Urology, Royal Bournemouth Hospital, United Kingdom

oluwarotimaaa@gmail.com

ORCID: <https://orcid.org/0000-0003-1823-4625>

ABSTRACT

Purpose: There is no consensus across guidelines on a diagnostic algorithm for upper urinary tract (UUT) evaluation following presentation with haematuria. Our aim is to compare the diagnostic accuracy of Ultrasound (USS) compared to CT-scan for UUT malignancies and also determine the considerations important for a risk-based diagnostic protocol for haematuria.

Methods: We reviewed our 'haematuria clinic' database to identify patients who had both USS and CT-scan for UUT evaluation between September 2015 and August 2017; and calculated the diagnostic accuracy of these imaging modalities for histologically confirmed UUT cancers. Furthermore, we identified risk factors in our diagnostic algorithm for haematuria and conducted regression analysis to determine their ability to predict UUT malignancies.

Results: Overall, 575 patient records were studied. Age range was 21 – 92 years, M:F was 1.4:1, majority (81.2%) had visible haematuria and 12 (2.1%) UUT cancers were diagnosed [Renal cell carcinoma- 1.4%; Upper tract urothelial cancer 0.7%]. USS and CT-scan had diagnostic accuracy for UUT cancers of 95.8% and 99.1% respectively ($p < 0.001$). Haematuria type was a significant consideration only on univariate analysis while multivariate binary logistic regression showed that male gender, smoking, occupational exposure and positive urologic history were the main risk-factors associated with UUT malignancies.

Conclusion: USS and CT-scan have comparably high diagnostic accuracy for detecting UUT malignancies. USS may therefore be considered as first-line UUT imaging modality when

utilized in a risk-based diagnostic algorithm. Larger, multicentred studies are needed to validate our findings and influence guideline development.

KEYWORDS: Ultrasound; CT-scan; Diagnostic algorithm; Accuracy; Haematuria; upper urinary tract cancer

DECLARATIONS:

Funding: Nil

Conflicts of Interests: None

Ethical approval: This study was approved by the clinical audit and effectiveness department of our hospital and was conducted in accordance with the ethical standards stated in the 1964 Helsinki declaration and its later amendments.

Consent: This study involved a retroactive review of de-identified data from an electronic database, so informed consent was waived.

INTRODUCTION

Haematuria is common, and may account for up to 10% of referrals to a urology service [1],[2]. Though it is generally accepted that cystoscopy is gold-standard for lower urinary tract evaluation following presentation with haematuria, the choice of diagnostic modality for the upper urinary tract (UUT) remains difficult and somewhat controversial [3]. This is because rationale for UUT imaging is multifactorial and depends on clinical presentation, renal function, pregnancy status, availability of resources, cost implication and local policy [2].

There is no consensus across urologic guidelines on a diagnostic algorithm for UUT evaluation in patients with haematuria (Table 1). The American Urology Association (AUA) Guidelines (2012 - 2019) recommend contrast-enhanced computerized tomography scan (CT-scan) for all patients above 35 years, with caveat for clinicians to individualize management when necessary based on patient's history and context of available resources [4]. Guidelines across Europe, Asia and other parts of the world on the other hand are either silent, or recommend a stratified approach with renal ultrasound (USS) as initial investigative modality for the UUT [2],[5],[6],[7].

USS therefore remains popular among General practitioners (GPs), Nephrologists and Urologists in most parts of the globe and is attractive because it is relatively cheap, readily available (including in the office), has no adverse effects on renal function, does not involve radiation exposure and has good ability to assess the renal parenchyma for masses and also exclude hydronephrosis [2],[8],[9],[10]. In addition, USS is helpful for evaluating hyperattenuating renal lesions detected on CT-scan in order to distinguish benign hyperdense cysts from complex or solid renal lesions [11]. It is thus not surprising that a fairly large number of

USS evaluations are carried out yearly on a global scale. For instance, a National Health Service (NHS) dataset revealed about 462,585 renal and bladder USS examinations were carried out in England during the 2016-2018 period [12]. Recent data from the United States and Canada equally suggest a similar high usage of USS in the North American sub-region [13]. Such significant utilization of USS examinations therefore justifies a need for validation studies to assess the diagnostic performance of this imaging modality in order to determine its continued relevance in the real-world.

Generally, it is believed that imaging with CT-scan is best for UUT evaluation following presentation with haematuria [14],[15]. However, large studies have confirmed that UUT cancers are rare, with prevalence only between 2.14 and 2.60% [3],[16]. Most scans will therefore be unsurprisingly negative and research has suggested that up to 1,018 CT-scan evaluations may be necessary to diagnose an additional UUT malignancy [17]. To the best of our knowledge, there are no risk prediction models for UUT cancers in patients with haematuria. We however believe it is important to explore ways of improving patient selection for UUT imaging so as to avoid exposing patients unduly to potential hazards including radiation-induced secondary malignancies, contrast nephropathy and anaphylactic contrast reaction [14],[18].

The aim of this study was therefore to evaluate the accuracy of USS compared to CT-scan for UUT malignancies and also determine the important considerations that could be used to predict UUT cancers in a risk-based diagnostic algorithm for haematuria.

MATERIAL AND METHODS

Participants and Imaging modalities

The database of all patients evaluated for visible or non-visible haematuria in our university hospital between September 2015 and August 2017 was reviewed after obtaining approval from our clinical audit and effectiveness department. Patients were referred to our urology service by GPs, emergency physicians and consultants in other specialties if they met diagnostic criteria for haematuria spelt out in the guidelines of the National Institute for Health and Care Excellence (NICE)- Figure 1 [19]. Visible haematuria was self-reported by patients to the referring physician, while non-visible haematuria was defined as $\geq 1+$ red blood cells on urine dipstick on at least two occasions.

Our diagnostic algorithm is summarized in Figure 1 and involves clinical evaluation, flexible cystoscopy for the lower tracts and USS for UUT assessment in all patients; usually on same day in a 'haematuria clinic' setting. Contrast enhanced CT-scan for further UUT evaluation was thereafter performed within a few days in patients categorized as high-risk for UUT malignancy. In our practice, these are patients with significant smoking history and other risk factors similar to those in the best practice policy of the AUA [20]; those with UUT abnormalities on USS and individuals with a positive urologic history. For the purpose of this study, urologic history was defined as any of loin pain, recurrent urinary tract infections, history of urinary tract stones or concomitant/prior history of urologic malignancy.

The USS evaluations were carried out by highly skilled sonographers (with 12-25 years' experience) using either a Phillips Epiq 5G or a Toshiba Aplio 500 ultrasound machine and a

3.5 MHz curvilinear probe. Contrast or doppler interrogation were used if necessary, though not as routine. The acquired ultrasound images were stored so could be further reviewed in our multidisciplinary team (MDT) meetings if required.

Our local CT-scan protocol for haematuria involves an initial unenhanced scan, followed by a contrast scan using split bolus technique in order to combine nephrogenic and excretory phases in a single acquisition; thereby **minimizing** radiation exposure. The patients were asked to drink about 1.5L of water over the two hours prior to their appointment. We inject 30-35 mls of Omni 300 into a vein on the upper limb, wait 12 minutes and then inject an additional 50mls at 1.5mls per second using a pressure injector. There is a 75 sec delay before the scanner starts to achieve a portal venous phase. We utilize either the 'Toshiba Aquillion One' (320 slice) or the 'Toshiba Aquillion 64' (64 slice) for the CT-scans and they were all carried out with the patient in the supine position.

Suspected UUT malignancies on imaging were reviewed by uro-radiologists in our MDT meetings and histologic confirmation and subsequent management such as renal biopsy, diagnostic ureteroscopy, nephrectomy or nephroureterectomy was thereafter carried out as appropriate.

De-identified records of patients who had both USS and CT-scan were extracted from our electronic database and demographic characteristics, identifiable risk factors, USS/CT-scan outcomes and final histology were exported for analysis.

Statistical analysis

This was conducted using the Statistical Package for Social Sciences version 21.0 (IBM Corp., Armonk, New York, USA). Statistical significance was set at $p < 0.05$ and 95% confidence interval. Means and standard deviations were calculated for continuous variables. The relationship between risk factors and histologically confirmed UUT malignancy was evaluated using univariate and multivariate analysis. Univariate association was determined using independent sample t-test for parametric continuous variables and cross-tabulation utilizing likelihood ratio or Pearson's Chi-square for categorical variables. Multivariate binary logistic regression was carried out to determine significant associations between risk factors and confirmed UUT cancers. Furthermore, the likelihood ratio, sensitivity, specificity, positive predictive value (PPV), negative predictive value (NPV) and diagnostic accuracy of USS and CT-scan for UUT malignancies were determined. The STARD checklist [21] was completed since this was a diagnostic accuracy study (Online Resource 1).

RESULTS

There were 580 patients who had both USS and CT-Scan for UUT evaluation during the study period and their outcomes are summarized in Figure 2. Five individuals with suspicious imaging findings but no histologic confirmation of malignancy were excluded, leaving data of 575/580 (99.1%) patients for analysis.

The age range of studied patients was 21 – 92 years, male to female ratio was 1.4:1 and majority (81.2%) had visible haematuria. We diagnosed 12/575 (2.1%) UUT cancers, with male preponderance of cases (11/12; 91.7%). They all had visible haematuria (12/12; 100%) and no UUT cancer was diagnosed in patients with non-visible haematuria. Multivariate analysis

showed that male gender, smoking (>20 pack year), occupational exposure and positive urologic history were the significant high-risk features associated with histologically confirmed UUT cancers (Table 2).

A comparison of USS and CT-scan performance for detecting UUT malignancies is presented in Table 3. In summary, USS and CT-scan have accuracy of 95.8% and 99.1% respectively. All patients diagnosed with an UUT cancer had a suggestive abnormality on both USS and CT-scan images (Online resource 2).

DISCUSSION

There are three principal outcomes from this study. First, we have presented our diagnostic algorithm for UUT evaluation following presentation with haematuria. Second, we found that the significant high-risk features associated with UUT cancers are male gender, smoking, occupational exposure and a prior or concomitant urologic history. Third, our data suggests that USS has comparable diagnostic accuracy to CT-scan for detecting UUT malignancies in patients with haematuria.

The significant high-risk features for UUT cancers identified in our study are not surprising, but consistent with previous documentation in literature [20],[22]. Age was not recognized as a significant risk factor in this study and our sub-analysis did not identify a specific cut-off age for occurrence of UUT cancers. The UK NICE guideline for haematuria was last updated in 2015 and age threshold of 45-years was introduced at the time on the premise that PPV of any haematuria was low below this age (0.99 for men and 0.22 for women) [19]. We had a

couple of patients (15, 2.6%) below 45-years recruited into our study around time of transition to current updated NICE guideline. Our youngest patient with UUT cancer was only 33-years old, younger than the threshold for evaluation of haematuria recommended in the AUA or NICE guidelines; and a pointer towards difficulty associated with basing threshold for patient evaluation on a fixed age alone.

Though the haematuria type (visible vs non-visible) was a significant univariate predictor for UUT cancers; this association surprisingly disappeared on multivariate analysis and we speculate that this is because haematuria type is less specific than other identified risk factors as a pointer toward UUT malignancies. There are many possible benign urologic or systemic aetiologies for haematuria, and it is also possible that visible haematuria is a progression of non-visible haematuria in patients with UUT cancers. It is however important to highlight that no UUT mitotic lesion was diagnosed following presentation with non-visible haematuria in this study; supporting previous publications demonstrating that UUT malignancies are a rare occurrence in non-visible haematuria [3],[23].

Our study showed that USS and CT-scan both have significantly high accuracy for UUT malignancies. Since all patients diagnosed with an UUT cancer had abnormalities on their USS and CT-scan, both imaging modalities therefore had a NPV of 100% which could give some reassurance following negative UUT evaluation in patients with haematuria. CT-scan correctly identified all patients with RCC; but five patients with suspected UTUC were re-classified as normal following ureteroscopy, giving CT-scan a positive predictive value (PPV) of 70.6%. This PPV of CT-scan is better than values previously reported in literature. Cauberg et al [14] found CT-scan PPV of 22%, so we attribute the improved PPV outcome in this study to better patient

selection using our risk-based individualized algorithm. We believe our approach was able to prevent many unnecessary and potentially harmful invasive diagnostic procedures that would have been associated with a lower PPV of CT-scan. USS on the other hand was less specific, with PPV of only 33.3%. Abnormalities on USS is trigger for further diagnostic imaging, so the low PPV of USS probably increased the yield from our CT-scan evaluations. We excluded 5 (0.9%) patients without histology but considering they also all had findings suggestive of UUT cancer on their USS images means our outcomes would not have been significantly different if they were included in our analysis.

Considering that about 98% of CT-scans in our study were negative and no new UUT malignancy was detected following a completely normal renal USS evaluation raises the possibility that carrying out CT-scan may have been an 'over-investigation' for some patients. We therefore argue that choice of UUT imaging modality be individualized based on patients' risk-assessment. Though there is a possibility that USS may miss very small RCC (below 3cm) or early UTUC that is not causing fullness or dilatation of the collecting system, our data suggests that such patients are likely to be in the high-risk category of our algorithm and would still require further imaging with CT-scan following a supposedly normal USS examination.

We postulate that a practicable risk-based algorithm for UUT evaluation like ours would improve selection of patients who would benefit maximally from CT-scan evaluation while limiting undue risks from radiation or contrast exposure. Our study supports the use of USS for first-line UUT imaging in patients with haematuria and we believe it may potentially be sole imaging modality required for selected patients who have no high-risk features. A

potential modification of our algorithm would involve offering patients classified as high-risk an upfront CT-scan without prior renal USS evaluation. In our practice, this was not the case because the initial USS evaluation was done in an 'Haematuria clinic' setting so didn't pose any additional logistical challenges and we have found the ancillary information such as post-void residual volume measurement derived from the USS evaluation useful for holistic evaluation of our patients.

Some limitations of our study must be recognized. The research was conducted in a single institution so our experience may not necessarily be generalizable to other environments or sub-populations considering there may be differences associated with USS operator experience, UUT cancer incidence and risk factor profile in patients across different geographical locations. Second, the USS results were known by Radiologists while reporting the CT-scan images and may have led to some bias and reduction in false negative rates of CT-Scan in our study. Furthermore, patients with normal CT-scan did not routinely have additional UUT evaluation, and this may have impacted on our sensitivity and diagnostic accuracy calculations. Lastly, the final outcomes of patients who had only USS for UUT evaluation was not reported as beyond the scope of this study. We have however previously studied the long-term outcomes of similar patient cohort and found our practice to be safe [24],[25].

CONCLUSIONS

UUT malignancies are uncommon and in order to minimize risks associated with aggressive patient evaluation following presentation with haematuria, we recommend that choice of UUT imaging modality should be individualized using a risk-based algorithm. Based on our data, USS and CT-scan both have comparably high accuracy for UUT malignancies so USS should remain first-line UUT investigation of choice and may be considered as an adequate modality in selected low-risk patients. High-risk considerations identified in our study are male gender, smoking, occupational exposure and a prior or concomitant urologic history and clinicians should have a low threshold to offer CT-scan imaging in this cohort. Larger, multicentred studies across different populations are needed to validate our findings and guide future guideline development.

Contributions

All the authors have contributed to this study in ways that conform to ICMJE authorship criteria. RAD and BJ retrieved the data. RAD and DA carried out the statistical analysis. All authors had input in article draft/revision and approved the final version of the manuscript

LEGENDS TO TABLES, FIGURES AND ONLINE RESOURCES (SUPPLEMENTS)

- Table 1: Summary of guideline recommendations for first line upper urinary tract imaging for haematuria evaluation
- Table 2: Demographic characteristics and risk-factors for upper urinary tract malignancies
- Table 3: Diagnostic accuracy of Ultrasound and CT-scan for upper urinary tract malignancies

Fig. 1: Diagnostic algorithm for Haematuria

Fig. 2: Flow diagram of results

Online resource 1: STARD checklist

Online resource 2: Breakdown of upper urinary tract cancers diagnosed

REFERENCES

1. Bolenz C, Schroppel B, Eisenhardt A, et al (2018) The Investigation of Hematuria. *Dtsch Arztebl Int* 115:801–807. <https://doi.org/10.3238/arztebl.2018.0801>
2. Moloney F, Murphy KP, Twomey M, et al (2014) Haematuria: An Imaging Guide. *Adv Urol* 2014:9. <https://doi.org/10.1155/2014/414125>
3. Tan WS, Sarpong R, Khetrupal P, et al (2018) Can Renal and Bladder Ultrasound Replace Computerized Tomography Urogram in Patients Investigated for Microscopic Hematuria? *J Urol* 200:973–980. <https://doi.org/10.1016/j.juro.2018.04.065>
4. Davis R, Jones JS, Barocas DA, et al (2012) Diagnosis, evaluation and follow-up of asymptomatic microhematuria (AMH) in adults: AUA guideline. *J Urol* 188:2473–2481. <https://doi.org/10.1016/j.juro.2012.09.078>
5. Edwards TJ, Dickinson AJ, Natale S, et al (2006) A prospective analysis of the diagnostic yield resulting from the attendance of 4020 patients at a protocol-driven haematuria clinic. *BJU Int* 97:301–305
6. Horie S, Ito S, Okada H, et al (2014) Japanese guidelines of the management of hematuria 2013. *Clin Exp Nephrol* 18:679–689. <https://doi.org/10.1007/s10157-014-1001-2>
7. van der Molen AJ, Hovius MC (2012) Hematuria: a problem-based imaging algorithm illustrating the recent Dutch guidelines on hematuria. *Am J Roentgenol* 198:1256–

8. Rheume-Lanoie J, Lepanto L, Fradet V, et al (2014) Diagnostic performance of ultrasound for macroscopic hematuria in the era of multidetector computed tomography urography. *Can Assoc Radiol J* 65:253–259.
<https://doi.org/10.1016/j.carj.2013.08.001>
9. Halpern JA, Chughtai B, Ghomrawi H (2017) Cost-effectiveness of common diagnostic approaches for evaluation of asymptomatic microscopic hematuria. *JAMA Intern Med* 177:800–807
10. Sun M, Wang C, Jiang F, et al (2019) Diagnostic value and clinical significance of ultrasound combined with CT in cystic renal cell carcinoma. *Oncol Lett* 18:1395–1401.
<https://doi.org/10.3892/ol.2019.10422>
11. O'Connor OJ, Fitzgerald E, Maher MM (2010) Imaging of hematuria. *Am J Roentgenol* 195:W263–W267
12. England NHS (2017) Diagnostic imaging dataset annual statistical release 2016/17.
<https://www.england.nhs.uk/statistics/wp-content/uploads/sites/2/2019/12/Annual-Statistical-Release-2018-19-PDF-1.9MB.pdf>. Accessed 15 June 2020
13. Smith-Bindman R, Kwan ML, Marlow EC, et al (2019) Trends in Use of Medical Imaging in US Health Care Systems and in Ontario, Canada, 2000-2016. *JAMA* 322:843–856. <https://doi.org/10.1001/jama.2019.11456>
14. Cauberg ECC, Nio CY, de la Rosette JMCH, et al (2011) Computed tomography-urography for upper urinary tract imaging: is it required for all patients who present with hematuria? *J Endourol* 25:1733–1740
15. Chlapoutakis K, Theocharopoulos N, Yarmenitis S, Damilakis J (2010) Performance of computed tomographic urography in diagnosis of upper urinary tract urothelial carcinoma, in patients presenting with hematuria: Systematic review and meta-analysis. *Eur J Radiol* 73:334–338. <https://doi.org/10.1016/j.ejrad.2008.10.026>

16. Mannas M, Khadhour S, Gallagher KM, et al (2020) Diagnostic test performance of Ultrasound and cytology in upper tract cancer- Results from the IDENTIFY study. Abstract MP24-04 of the American Urologic Association Annual Meeting. J Urol. <https://doi.org/10.1097/ju.0000000000000857.04>
17. Yecies T, Bandari J, Fam M, et al (2018) Risk of Radiation from Computerized Tomography Urography in the Evaluation of Asymptomatic Microscopic Hematuria. J Urol 200:967–972. <https://doi.org/10.1016/j.juro.2018.05.118>
18. Tan WP, Kelly JD, Tan WS (2019) The investigation of haematuria and bladder cancer. Trends Urol Men’s Heal 10:25–27
19. Jefferies ER, Brewster SF, Oncology BS on (2016) Urological recommendations from the National Institute for Health and Care Excellence (NICE) Guideline, June 2015: Suspected cancer: recognition and referral. BJU Int 117:857–860
20. Grossfeld GD, Litwin MS, Wolf Jr. JS, et al (2001) Evaluation of asymptomatic microscopic hematuria in adults: the American Urological Association best practice policy--part II: patient evaluation, cytology, voided markers, imaging, cystoscopy, nephrology evaluation, and follow-up. Urology 57:604–610. [https://doi.org/10.1016/s0090-4295\(01\)00920-7](https://doi.org/10.1016/s0090-4295(01)00920-7)
21. Cohen JF, Korevaar DA, Altman DG, et al (2016) STARD 2015 guidelines for reporting diagnostic accuracy studies: explanation and elaboration. BMJ Open 6:e012799. <https://doi.org/10.1136/bmjopen-2016-012799>
22. Salako AA, Badmus TA, Badmos KB, et al (2017) Renal cell carcinoma in a semi-urban population of south-western Nigeria. East Afr Med J 94:37–43
23. Fankhauser CD, Waisbrod S, Fierz C, et al (2020) Diagnostic accuracy of ultrasonography, computed tomography, cystoscopy and cytology to detect urinary tract malignancies in patients with asymptomatic hematuria. World J Urol. <https://doi.org/10.1007/s00345-020-03171-6>
24. Datta SN, Allen GM, Evans R, et al (2002) Urinary tract ultrasonography in the

- evaluation of haematuria--a report of over 1,000 cases. *Ann R Coll Surg Engl* 84:203–205
25. KandaSwamy G, David R, Rai B, et al (2019) Fate of normal hematuria investigation patients in the immediate to long term - outcomes and clinical implications. *J Endourol* 33:A228
 26. Nielsen M, Qaseem A (2016) Hematuria as a marker of occult urinary tract cancer: advice for high-value care from the American College of Physicians. *Ann Intern Med* 164:488–497
 27. BAUS Sect. Oncol. (2016) Summ. Ref. NICE Guidel. haematuria. [https://www.baus.org.uk/_userfiles/pages/files/Publications/BAUS Cancer Guidelines Summary.pdf](https://www.baus.org.uk/_userfiles/pages/files/Publications/BAUS%20Cancer%20Guidelines%20Summary.pdf). Accessed 14 Jun 2020
 28. Kassouf W, Aprikian A, Black P, et al (2016) Recommendations for the improvement of bladder cancer quality of care in Canada: A consensus document reviewed and endorsed by Bladder Cancer Canada (BCC), Canadian Urologic Oncology Group (CUOG), and Canadian Urological Association (CUA). *Can Urol Assoc J* 10:E46-80. <https://doi.org/10.5489/cuaj.3583>
 29. Babjuk M, Burger M, Comperat EM, et al (2019) European Association of Urology Guidelines on Non-muscle-invasive Bladder Cancer (TaT1 and Carcinoma In Situ) - 2019 Update. *Eur Urol* 76:639–657. <https://doi.org/10.1016/j.eururo.2019.08.016>
 30. Van Der Molen AJ, Cowan NC, Mueller-Lisse UG, et al (2008) CT urography: definition, indications and techniques. A guideline for clinical practice. *Eur Radiol* 18:4–17. <https://doi.org/10.1007/s00330-007-0792-x>
-

Table 1. Summary of guideline recommendations for first line upper urinary tract imaging for haematuria evaluation

Organisation	First line UUT imaging
AUA[4]	CTU for all patients aged > 35yrs regardless of haematuria type
ACP [26]	No specific guidance
BAUS [27]	No specific guidance
Canadian working group [28]	Asymptomatic microscopic haematuria: physician preference Symptomatic microscopic haematuria and Gross haematuria: CTU
Dutch guidelines [7]	Low risk (NVH <50yrs): USS Medium risk (NVH > 50yrs & VH < 50yrs): USS High risk (VH > 50yrs or risk score >6): CTU
EAU [29]	Use renal and bladder USS and/or computed tomography-intravenous urography (CT-IVU) during the initial work-up in patients with haematuria
ESUR [30]	NVH – USS Macroscopic haematuria with low & medium probability for urothelial cancer: USS Macroscopic haematuria, at high-risk for urothelial cancer: CTU
Japanese guidelines [6]	Low and medium risk: USS High risk: CTU
NICE guidelines[19]	No specific guidance

UUT - upper urinary tract; AUA – American Urologic Association; CTU – Computed Tomography Urogram, ACP – American College of Physicians; BAUS – British Association of Urologic Surgeons; USS – ultrasound; NVH – non-visible haematuria; VH – visible haematuria; EAU – European Association of Urology; ESUR – European Society of Urogenital Radiology; NICE – National Institute for Health and Care Excellence

Table 2: Demographic characteristics and risk-factors for upper urinary tract malignancies

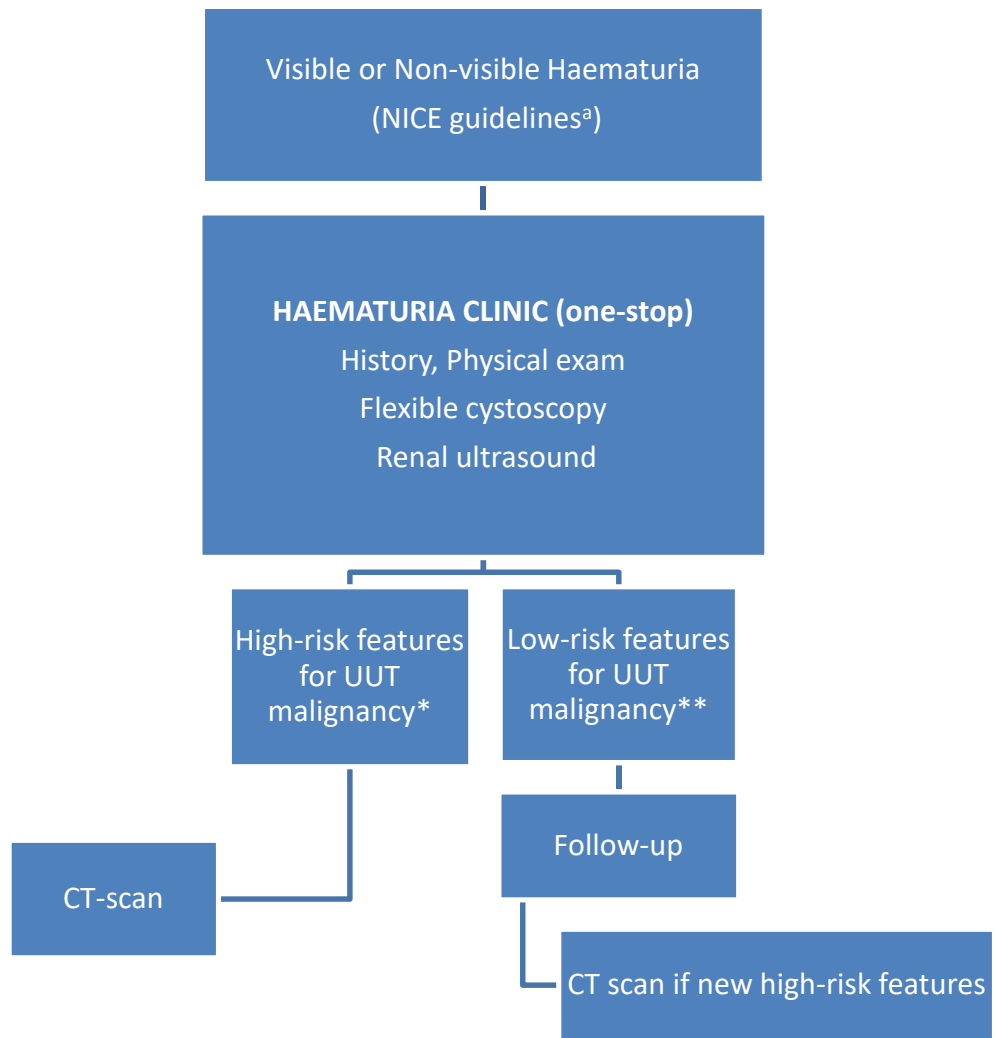
		All Patients N = 575	Confirmed UUT Cancer N=12	No UUT Cancer N=563	Univariate analysis		Multivariate analysis	
					Value	p-value	Beta	p-value
Age (Mean ± SD)		64.3 ± 12.2	63.8 ± 12.4	64.4 ± 12.1	-0.147	0.883*	-0.303	0.057
Age range	18-30	8 (1.4%)	0	8 (1.4%)	8.338	0.214 ^{\$}	-	0.475
	31-40	7 (1.2%)	1 (0.2%)	6 (1.0%)			-17.332	0.999
	41-50	74 (12.9%)	0	74 (12.9%)			-35.769	0.995
	51-60	107 (18.6%)	2 (0.3%)	105 (18.3%)			-12.552	0.998
	61-70	183 (31.8%)	6 (1.0%)	177 (30.8%)			-26.341	0.996
	71-80	161 (28.0%)	3 (0.5%)	158 (27.5%)			-23.142	0.996
	>80	35 (6.1%)	0	35 (6.1%)			-20.880	0.997
Gender	Male	337 (58.6%)	11 (1.9%)	326 (56.7%)	6.749	0.009 ^{\$}	-3.085	0.009
	Female	238 (41.4%)	1 (0.2%)	237 (41.2%)				
Haematuria type	Visible	467 (81.2%)	12 (2.1%)	455 (79.1%)	5.052	0.025 ^{\$}	-16.541	0.996
	Non-visible	108 (18.8%)	0	108 (18.8%)				
Smoking (>20 pack year)	Yes	176 (30.6%)	10 (1.7%)	166 (28.9%)	14.663	<0.001 ^{\$}	-3.656	<0.001
	No	399 (69.4%)	2 (0.3%)	397 (69.0%)				

Occupational risk factor	Yes	122 (21.2%)	2 (0.3%)	120 (20.9%)	0.161	0.689 ^{\$}	4.549	0.012
	No	453 (78.8%)	10 (1.7%)	443 (77.0%)				
Urologic history ^{**}	Yes	104 (18.1%)	5 (0.9%)	99 (17.2%)	4.599	0.032 ^{**}	-5.094	0.001
	No	471 (81.9%)	7 (1.2%)	464 (80.7%)				

*Independent sample t-test; ^{\$}Likelihood ratio; ^{**}Chi-square

^{**}Urologic history: loin pain, urinary tract infections, history of stones, concomitant or prior history of urologic malignancy

Figure 1.



NICE: National Institute for Health and Care Excellence
 UUT: Upper urinary tract

^aNICE Guidelines for evaluation

- Aged ≥ 45 yrs with unexplained visible haematuria without urinary tract infection or visible haematuria that persists or recurs after successful treatment of urinary tract infection
- Aged ≥ 60 yrs with unexplained non-visible haematuria and any of dysuria, raised serum white cell count or recurrent/persistent unexplained urinary tract infection

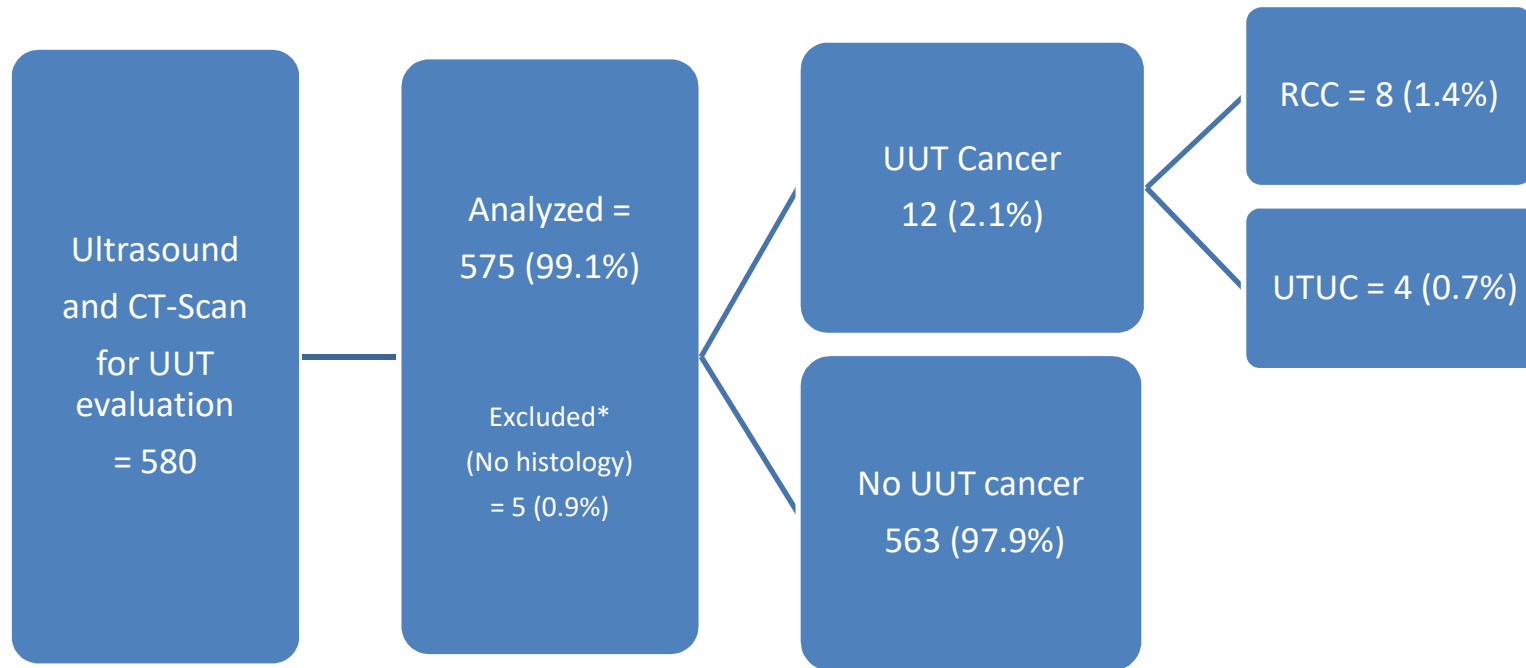
***High risk features for UUT malignancy**

- Significant smoking history (pack year ≥ 20)
- Occupational exposure to chemicals or dyes
- Urologic history: loin pain, urinary tract infections, history of stones, concomitant or prior history of urologic malignancy
- Recurrent visible haematuria
- Single episode of visible haematuria or non-visible haematuria and positive urologic history
- Upper urinary tract abnormality on Ultrasound - dilatation, mass, complex cyst etc

**** Low risk features for UUT malignancy**

- Absence of any of the above high-risk features

Figure 2.



UUT: upper urinary tract; RCC: Renal cell carcinoma; UTUC: upper tract urothelial cancer

*Excluded:

1. 90-year old male with left hydroureteronephrosis on USS and CT-scan. Ureteroscopy revealed a solid tumour in distal left ureter. Multidisciplinary team (MDT) recommended expectant management as not able to withstand major surgery
 2. 88-year old male with left hydronephrosis and probable mass around pelvi-ureteric junction on both USS and CT-scan. Unfit for intervention due to comorbidities
 3. 81-year male with right hydronephrosis and suspicious abnormality in renal pelvis on USS and CT-scan. Unfit, due to comorbidities
 4. 80-year old male with 3cm ill-defined solid, enhancing left renal mass detected on USS and confirmed with CT-scan. MDT recommended surveillance
 5. 70-year old male with 4.3cm solid enhancing left renal mass present on USS and CT-scan. Unable to have major surgery due to significant co-morbidities so MDT recommended surveillance
-