



THE UNIVERSITY *of* EDINBURGH

Edinburgh Research Explorer

A study of the thickness of cheek teeth subocclusal secondary dentine in horses of different ages

Citation for published version:

White, C & Dixon, PM 2010, 'A study of the thickness of cheek teeth subocclusal secondary dentine in horses of different ages', *Equine Veterinary Journal*, vol. 42, no. 2, pp. 119-123.
<https://doi.org/10.2746/042516409x475409>

Digital Object Identifier (DOI):

<http://dx.doi.org/10.2746/042516409x475409>

Link:

[Link to publication record in Edinburgh Research Explorer](#)

Document Version:

Early version, also known as pre-print

Published In:

Equine Veterinary Journal

General rights

Copyright for the publications made accessible via the Edinburgh Research Explorer is retained by the author(s) and / or other copyright owners and it is a condition of accessing these publications that users recognise and abide by the legal requirements associated with these rights.

Take down policy

The University of Edinburgh has made every reasonable effort to ensure that Edinburgh Research Explorer content complies with UK legislation. If you believe that the public display of this file breaches copyright please contact openaccess@ed.ac.uk providing details, and we will remove access to the work immediately and investigate your claim.



A study of the thickness of cheek teeth subocclusal secondary dentine in horses of different ages

C. WHITE and P. M. DIXON*

Division of Veterinary Clinical Studies, The Royal (Dick) School of Veterinary Studies, The University of Edinburgh, Easter Bush Veterinary Centre, Midlothian EH25 9RG, UK.

Keywords: horse; dentistry; cheek teeth; secondary dentine; subocclusal dentinal thickness

Summary

Reasons for performing study: There is limited knowledge on the thickness of subocclusal secondary dentine in equine cheek teeth (CT).

Hypotheses: Subocclusal secondary dentine is of consistent thickness above different pulp horns in individual horses and its thickness increases with age.

Methods: 408 permanent CT were extracted *post mortem* from 17 horses aged 4–30 years, with no history of dental disease. The CT were sectioned longitudinally in the medio-lateral (bucco-palatal/lingual) plane through each pulp horn, and the thickness of the secondary dentine overlying each pulp horn was measured directly.

Results: The subocclusal thickness of secondary dentine above the pulp horns of CT varied from a mean thickness (above all pulp horns) of 12.8 mm (range 5–33 mm) in a 4-year-old to 7.5 mm (range 2–24 mm) in a 16-year-old horse. There was wide variation in the depth of subocclusal secondary dentine above different pulp horns, even within the same CT. In contrast to expectations, occlusal secondary dentine thickness did not increase with age. There were no significant differences in occlusal secondary dentine thickness between rostral and caudal, or medial and lateral aspects of the CT, or between contralateral CT. Mandibular CT had significantly thicker subocclusal secondary dentine than maxillary CT. Pink coloured secondary dentine was sometimes found 1–3 mm occlusal to the pulp horn in sectioned CT and this was likely caused by artefactual blood staining from the underlying pulp during sectioning.

Conclusions: The thickness of subocclusal secondary dentine varies greatly between individual pulp horns, teeth and individual horses and can be as low as 2 mm over individual pulp horns.

Potential relevance: Due to the great variation in the thickness of subocclusal secondary dentine between horses, and even between pulp horns in individual CT, there is a risk of exposure or thermal damage to pulp and thus of apical infection, even with modest therapeutic reductions of CT occlusal overgrowths. In the light of these findings, great care should be taken when reducing equine CT overgrowths and larger dental overgrowths should be reduced in stages.

Introduction

Many qualitative and quantitative studies, including those of Kirkland (1996), Kilic *et al.* (1997), Gasse *et al.* (2004), Shaw *et al.* (2008) and Dacre *et al.* (2008), have described the structure and composition of equine teeth, but few studies have measured the thickness of subocclusal secondary dentine (occlusal to the pulp horns) in equine cheek teeth (CT). Additionally, none of the standard equine anatomical or dental texts gives a value for this parameter. Becker (1962) stated that 10 mm of secondary dentine is normally present subocclusally above the pulp horns, but did not give any factual data on such measurements. Dacre *et al.* (2008) found subocclusal secondary dentine to be as little as 2–6 mm in depth over 22% of CT pulp horns, with this variation due to the normal irregularities (transverse ridges) of the CT occlusal surface.

Having an accurate knowledge of the endodontic status and subocclusal dentinal thickness of CT in horses of different ages would be of great benefit in equine dentistry, as it would allow accurate assessment on how much CT overgrowth could be therapeutically removed from the occlusal surface before encountering vital pulp. Such knowledge could therefore help avoid iatrogenic exposure and thermal damage to pulps, and help reduce the risk of pulpar and subsequent apical infection of the treated tooth. Such knowledge would be particularly important when treating neglected rostral 06 or caudal 11 overgrowths, or step mouth, where large (e.g. 10–20 mm high) occlusal overgrowths can occur.

The aim of this study was to investigate the thickness of subocclusal secondary dentine above all pulp horns in the CT in different aged horses and to compare this parameter between maxillary and mandibular CT. Because CT overgrowths are clinically defined as being in a rostral or caudal, or a buccal or lingual/palatal location on a tooth, comparisons were also made between subocclusal secondary dentinal thickness at these aspects of CT. Using the CT pulp labelling system of du Toit *et al.* (2008a) (Fig 1), the rostrally situated pulps (i.e. 1st, 3rd, 6th maxillary; 1st, 3rd, 6th mandibular pulps) were compared with the caudally situated pulps (i.e. 2nd, 4th, 7th, 8th maxillary; 2nd, 5th, 7th mandibular pulps) and the buccally located pulps (i.e. 1st, 2nd, 7th, maxillary; 1st, 2nd, 6th, 7th mandibular pulps) were compared with the lingually/palately situated pulps (i.e. 3rd, 4th, 5th maxillary; 3rd, 4th, 5th mandibular pulps). Some horses favour one side of their mouth during mastication, as is the case with many human

*Author to whom correspondence should be addressed.

[Paper received for publication 07.05.09; Accepted 15.06.09]

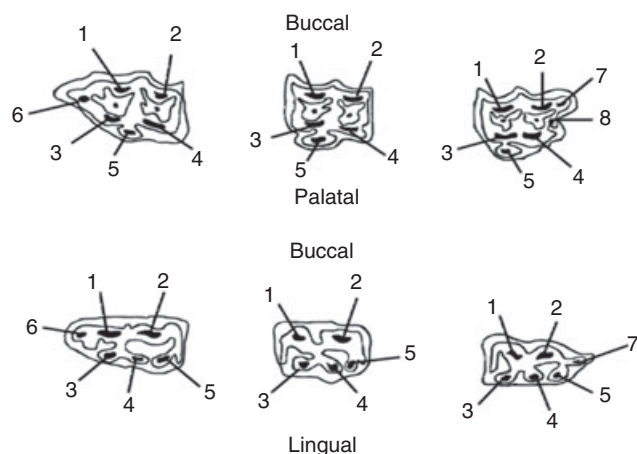


Fig 1: Diagram of the occlusal surfaces of equine cheek teeth, with the upper row containing maxillary Triadan 6s, 9s and 11s and the lower row mandibular Triadan 6s, 9s and 11s. Numbers indicate individual pulp horns using the pulp labelling system of Du Toit *et al.* (2008a).

subjects (Nissan *et al.* 2004) and a comparison was also made between subocclusal dentinal thicknesses from CT on contralateral sides of the skulls, to investigate for possible differences in this regard. Hypotheses for this study included that subocclusal secondary dentine thickness increases with age; there are no differences in secondary dentinal depth between maxillary and mandibular CT, between pulp horns on the buccal and lingual, or rostral and caudal aspects of CT, or between CT on contralateral sides of the skull.

Materials and methods

This study utilised 408 permanent CT that were extracted intact using an osteotome and hammer, *post mortem* from 17 equine skulls, mainly Thoroughbred crosses, large cob-types and Thoroughbreds, aged 4–30 years, that had all their CT and that had died or had been subjected to euthanasia on humane grounds for disorders unrelated to dentition at this hospital. Pilot studies with 4 CT using computed axial tomography (Du Toit *et al.* 2008b) where subocclusal secondary dentine was measured in both rostro-caudal (Fig 2) and lateral planes showed similar values in both planes, and also showed similar values to direct measurements of secondary dentine as described below.

Having identified the darker area of occlusal secondary dentine above each pulp horn, the individual CT were then sectioned longitudinally in a medial (bucco-lingual/palatal) plane, usually sectioning 2 pulp horns per section (e.g. maxillary 1st and 3rd, or 2nd and 4th pulps; or mandibular 1st and 3rd, or 2nd and 5th pulps) using the pulp labelling system of Du Toit *et al.* (2008a) (Fig 1). Dental sectioning was performed using a 99-TS230M water-cooled tile saw¹ with 20.3 cm diameter, 0.81 mm thick continuousrim, diamond-tipped blade².

If the occlusal aspect of each pulp horn was not exposed by the above sectioning, the area was re-sectioned or ground (using the coated side of the saw blade) until the occlusal aspect of the pulp horn was fully exposed. Additionally, a 23 gauge needle was sometimes used to probe the most occlusal aspect of the pulp horn to identify the most occlusal site of transition from pulp horn to secondary dentine. Dentinal thickness was measured to the nearest mm using a calibrated ruler.

Statistical analysis

Statistical calculations were made using SPSS 15.0 (2006)³ computer statistical package with significance level set as $P < 0.05$. Pearson's Correlation test was used to test the association between dentinal thickness and age, and ANOVA was used for paired comparison of dentinal thickness between the various other sites. Repeatability studies of 16 pulps in 3 CT that were measured blindly 10 times showed a variation of <1%.

Results

No major CT overgrowths were present in any skulls, but multiple mandibular CT displacements with diastemata were present in an 8-year-old skull, features that did not preclude the required measurements being obtained. Five of the 408 CT had occlusal pulpar exposure (that were all fully sealed off from the periapical tissues by extensive tertiary dentine or cemental deposition), of a total of 14 pulp horns, including of all ($n = 5$) pulp horns in the 209 of a 9-year-old horse and all ($n = 6$) in the 306 of the 16-year-old horse. Three other horses had the 2nd pulp horn of a maxillary CT occlusally exposed. Obviously, no measurements were obtainable in these 14 pulp horns.

Some recently erupted Triadan 08 and 11s in the 4-year-old horses contained a large, common pulp chamber without formation of all of the individual pulp horns. For example, the 7th and 8th pulp horns of one Triadan 11 and the 8th pulp horn of another had not yet developed. Some other maxillary Triadan 11s (in horses of all ages) also did not have clearly identifiable 7th and 8th pulp horns, including in Triadan 11s that had marked caudal angulation, where it was technically difficult to follow the contour of the curved pulps with the rigid-blade saw. Overall, the 7th pulp of maxillary 11s was identifiable in 9/17 (53%) skulls while the 8th pulp was identifiable in 10/17 (59%) skulls. The 7th pulp of mandibular 11s was identifiable in 12/17 (82%) skulls. The 6th pulp was identifiable in all maxillary 06s, and in mandibular 06s in 16/17 (94%) of skulls.

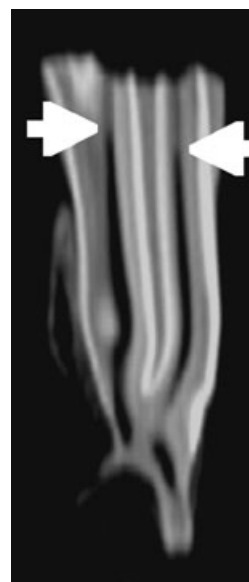

Fig 2: A computed axial tomography scan showing the 1st and 3rd pulps of the 309 of a 6-year-old horse, with arrows indicating transition from pulp to subocclusal secondary dentine.

In some older teeth, secondary dentine deposition around the periphery of pulp horns narrowed their diameter to approximately the width of the saw blade (1 mm), making subsequent identification of the occlusal aspect of the pulp (and thus obtaining measurements) difficult or impossible following teeth sectioning. The CT of the horses aged 16, 18 and 23 years had 82% their pulp horns identifiable, but only 30% of pulp horns were identifiable in the 30-year-old horse. Some older CT retained wide (>2 mm diameter) pulp horns (Fig 3) and all younger teeth had wide pulp horns, e.g. 3 mm wide at the apical aspect of pulp horns due to low peripheral secondary dentine deposition, although they usually contained a thick layer of secondary dentine subocclusally, above the pulp horns (Table 1). A total of 1988 measurements of subocclusal secondary dentine thickness were taken from 408 teeth from the 17 horses (up to 7 sites per tooth).

Both the Triadan 07 and 09 teeth had occlusal secondary dentine of similar thickness in the 5 oldest horses (mean 8.9 mm in 07s and 8.8 in 09s). The 6th pulp horn (the most rostral pulp horn) of the Triadan 06s (that is very prone to iatrogenic damage) had a mean depth of 10.3 mm but had a wide range (3–31 mm) of subocclusal dentine. The Triadan 11s also showed a wide range of dentinal thickness (mean 12 mm, range 3.5–23.5 mm). A wide range of dentinal thickness was a feature even within individual teeth, e.g. one CT of a 9-year-old horse had secondary dentine thickness >11 mm above all pulp horns except one, that had only 3 mm of dentine overlying it.

Age variation in secondary dentine thickness

The thickest mean subocclusal secondary dentine of combined pulp horns of all CT in individual horses was found in the two 4-year-old horses (mean values of 12.6 mm and 13.0 mm), and the thinnest mean value (7.5 mm) was recorded in a 16-year-old horse. Care must be taken when interpreting the low dentinal thicknesses found in some CT of aged horses (Table 1), which was often due to the whole tooth, and thus the subocclusal secondary dentine, being very worn, with no recognisable pulp left in some pulp horns. However, not all thin dentine can be attributed to age-related dental wear, as thin (3 mm) secondary dentine was also found above one pulp horn in the CT of a 9 year old-horse. The thickest (37 mm) secondary dentine above an individual pulp horn was found in a 4-year-old horse.

TABLE 1: Mean \pm s.d. of subocclusal secondary dentine thickness in horses of different ages

| Age years | No. of horses | No. of pulp horns measured | Mean \pm s.d. depth of dentine (mm) | Range of depth of dentine (mm) |
|-----------|---------------|----------------------------|---------------------------------------|--------------------------------|
| 4 | 2 | 248 | 12.8 \pm 3.9 | 5–37 |
| 6 | 1 | 124 | 8.9 \pm 3.6 | 4–28 |
| 7 | 1 | 129 | 9.3 \pm 2.7 | 5–25 |
| 8 | 1 | 129 | 11.1 \pm 2.8 | 6–25 |
| 9 | 2 | 241 | 9.9 \pm 3.4 | 3–29 |
| 10 | 1 | 126 | 10.0 \pm 3.0 | 6–27 |
| 11 | 1 | 129 | 11.4 \pm 3.4 | 5–29 |
| 12 | 2 | 256 | 10.0 \pm 3.8 | 4–33 |
| 13 | 1 | 122 | 11.8 \pm 5.8 | 6–35 |
| 14 | 1 | 125 | 8.0 \pm 3.9 | 3–24 |
| 16 | 1 | 107 | 7.5 \pm 4.3 | 2–24 |
| 18 | 1 | 106 | 11.9 \pm 4.4 | 5–35 |
| 23 | 1 | 107 | 9.3 \pm 3.0 | 2–18 |
| 30 | 1 | 86 | 8.0 \pm 4.0 | 1–9 |

In contrast to expectations, there was no increase in secondary dentine thickness with age, in fact a slight trend (Pearson's correlation $P = 0.055$; $r^2 = 0.2$) for an age-related decrease in thickness of subocclusal secondary dentine was found in all CT, and more so ($P = 0.042$; $r^2 = 0.31$) in mandibular CT, but this trend was probably influenced by the presence of age-related, worn CT and thus thin subocclusal secondary dentine in older horses.

The mean secondary dentine thickness for mandibular cheek teeth was 10.97 mm, and for the maxillary cheek teeth 9.44 mm,

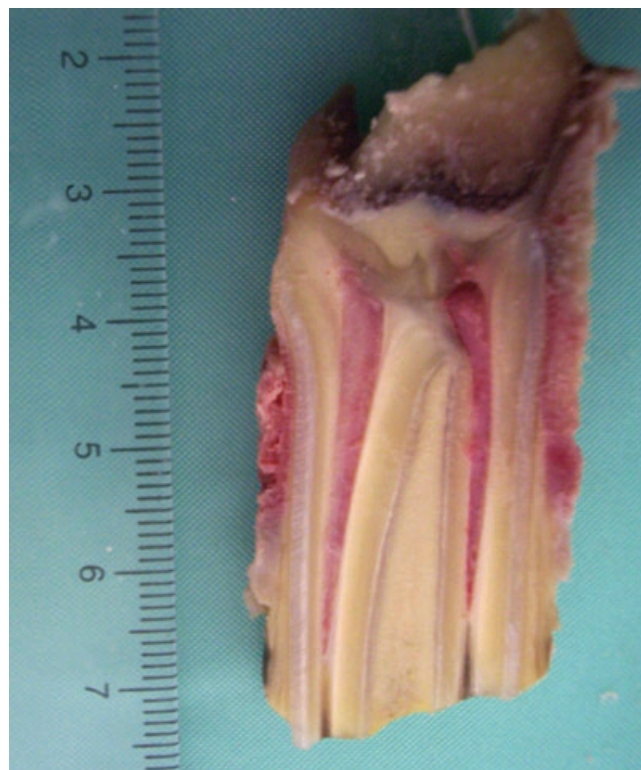

Fig 3: The 2 exposed pulp horns (with 5 and 6 mm of overlying secondary dentine) in this Triadan 107 of a 16-year-old horse are still >2 mm wide apically.

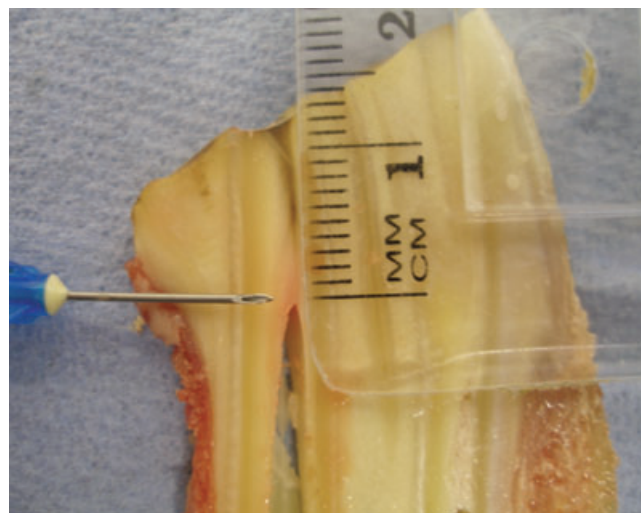


Fig 4: This mandibular CT has 13 mm thick subocclusal secondary dentine. About 3 mm of secondary dentine occlusal and lateral to the pulp was stained pink in this tooth.

with this difference (1.53 mm) being significant ($P < 0.01$). There was no significant difference in mean subocclusal secondary dentine depth between contralateral sides of the mouth (9.81 mm on left side and 9.76 mm on right side); the buccal (9.44 mm) and lingual (9.18 mm) aspects of CT, nor between rostral (9.44 mm) and caudal (9.39 mm) aspects of CT. Pink discolouration of secondary dentine was often present in the sectioned teeth for a depth of 1–3 mm above and to a lesser degree on the sides of the pulp horn tip that appeared to be caused by artefactual blood staining from the pulp horn (Fig 4).

Discussion

The mean thickness of subocclusal secondary dentine (of all pulp horns) in individual horses in this study varied from 12.8 mm in a 4-year-old to 7.5 mm in a 16-year-old with an overall figure similar to Becker's mean value of 10 mm (Becker 1962). However, from a clinical viewpoint, more important is the fact that the range of dentinal thickness above individual pulp horns was very wide in all age groups, with ≤ 6 mm of secondary dentine overlying some pulp horns in all horses in this study and with ≤ 3 mm present above some pulp horns in 5 horses, including a 9-year-old horse. This finding indicates that great caution must be taken when therapeutically reducing equine CT overgrowths, because even very modest occlusal reductions could cause occlusal exposure or thermal injury of pulp that may potentially cause pulpar infection and even loss of tooth.

Contrary to expectations, no significant age-related increase in subocclusal secondary dentine thickness was found in the current study. In fact there was a very slight trend for CT secondary dentine thickness to decrease with age, more so in mandibular CT, and this trend was most noticeable in horses aged >20 years. This finding was probably influenced by the presence of older horses in this study, some of whose CT were very worn, and consequently had thin subocclusal secondary dentine. The presence of thin subocclusal secondary dentine in older horses is clinically much less important than its presence in younger horses, where iatrogenic pulpar exposure could cause apical infection with more serious consequences, as infection of the deeply situated apices of young teeth usually cause infections of the supporting bone or paranasal sinuses.

The current findings support those of Dacre *et al.* (2008) and Shaw *et al.* (2008) who showed progressively increasing thickness of secondary dentine around the periphery of the pulp horns with age, except at their occlusal aspects. For example, the 4-year-old horses in the present study had the thickest subocclusal secondary dentine, but also had very wide pulp horns indicating that little secondary dentine had been deposited around the sides of the pulp horns. It seems likely that there are different stimuli for secondary dentine deposition at different sites around the equine pulp, with a progressive, time-dependent deposition of secondary dentine on all aspects of pulp horns, but additionally, mechanical occlusal surface stimulation also regulating subocclusal dentine deposition in horses (Dixon 2002).

When mechanically reducing the height of a tooth, visualisation of pink discolouration of the surface of the tooth has been taken as an indication of close proximity to the pulp. However, there is no anatomical justification for this assumption as the predentine layer, which in any case is just some microns in thickness, is avascular as is secondary dentine (C. Staszky,

personal communication) and therefore the finding of pink discoloured dentine during dental reductions indicates that actual exposure of pulp has occurred. This study showed up to 3 mm of pink dentine to overlie the pulp horn in some CT, but this staining appears to have been caused by blood from the underlying pulp horn that was also being sectioned. Detection of pink-stained dentine during dental procedures should indicate that pulpar exposure and significant thermal damage may have already occurred to the pulp by this stage, if a motorised instrument is being used.

Although older equine CT are stated to have extensive loss of individual pulp horns due to continued secondary dentine deposition (Gasse *et al.* 2004), in the present study the CT of the horses aged 16, 18 and 23 years had 82% their pulp horns identifiable. Gasse *et al.* (2004) also found that pulp horns disappear at an earlier age in the Triadan 09 than the Triadan 07 cheek teeth, but no such difference was found in this study.

The mean secondary dentine thickness for mandibular CT (11.0 mm) was significantly thicker than for the maxillary CT (9.4 mm). This feature could possibly be due to the mandibular CT being narrower than their maxillary counterparts and thus having more force applied to its smaller surface area, with its thicker secondary dentine compensating for this disparity in occlusal surface area.

There was no significant difference between subocclusal secondary dentine depths on the buccal and lingual aspects of CT. Equine CT have normal occlusal angulations (sloping upwards in a bucco-lingual to palatal direction) of 12.5–30° at different sites, with highest angles present on caudal mandibular CT (Brown *et al.* 2008). In the present study, dentinal thickness was always measured from the sloped occlusal surface. It was found that if the occlusal angulation of the caudal mandibular CT were ground away to make the occlusal surface horizontal, the pulp horns on the lingual aspect of some caudal mandibular CT would be exposed. Consequently, this study also confirms the importance of maintaining normal occlusal angulation, especially on the highly angulated caudal mandibular CT.

As noted, many CT overgrowths develop on the rostral aspects of the upper 06 or the caudal aspects of the lower 11s, and these areas are commonly therapeutically reduced. This study found no significant difference between occlusal secondary dentine depths in the pulps on the rostral aspect of the cheek teeth and the caudal aspect of the cheek teeth. Whilst in general, the 6th pulp horn has subocclusal secondary dentine of equal thickness to other pulp horns (mean 10.3 mm) they also have a wide range, with just 3 mm thick dentine above one 6th pulp. This finding has clinical significance considering the current practice of reducing the rostral aspect of the Triadan 06s ('bit-seating') to ostensibly make the bit sit more comfortably in the horse's mouth, during which even a 3 mm reduction of the rostral aspect of a Triadan 06 could directly expose or cause thermal damage to the 6th pulp horn.

The mandibular 11s had a mean depth of subocclusal secondary dentine of 12 mm (range 3.5–23.5 mm). The caudal aspect of this CT can be sloped dorsally, due to normal curvature of the caudal mandible known as the 'curve of Spee,' a feature which can be very pronounced in some pony breeds and Arabian horses. If mandibular 11s in mouths with this feature are mistakenly believed to have caudal overgrowths and are reduced by even 3.5 mm in some horses, their pulp horns may be exposed thus risking infection of the pulp (Dixon *et al.* 2000, 2009).

Some horses preferentially masticate with one side of their mouth, as do 77% of children (McDonnell *et al.* 2004) and 78% of human adults (Nissan *et al.* 2004). This study found no significant difference in the depth of secondary dentine between the left and right sides of the mouth. However, this finding does not preclude that horses preferentially masticate with one side of their mouth. As noted, it is likely that subocclusal deposition of secondary dentine in horses is regulated by the occlusal forces placed on these teeth (Dixon 2002) and thus increased deposition of secondary dentine may compensate for increased dental wear on the CT on the side of mouth preferentially used for mastication. Likewise, unopposed CT that have no occlusal stimulation may have decreased secondary dentine deposition as compared to normal CT, in addition to faster eruption. Therefore, such overgrown teeth are at very high risk of pulpar exposure if they are reduced to same height as the adjacent teeth.

Further studies, possibly by computed tomography of larger numbers of CT would reveal additional information on pulp horn dimensions, especially of narrow (<1 mm) pulp horns, without having to physically section the CT. Additionally it would also be of value to know the full dental history of horses used in further studies, such as the frequency and nature of their dental treatments, which could affect the depth of secondary dentine. More accurate interbreed and size comparisons of dentinal thickness would also be worthwhile. It would also be of interest to investigate the depth of occlusal secondary dentine in teeth with large overgrowths to assess the rate of deposition of subocclusal dentine in CT without occlusal stimulation that additionally, are erupting faster than usual.

In conclusion, this study found much variability in subocclusal secondary dentinal thickness in horses of all ages, with as little as 3 mm of secondary dentine overlying some pulp horns, including the 6th pulp horn (of Triadan 06s) in some young horses. In contrast to expectations, no age-related increase in secondary dentine thickness was found. These findings show that horses of all ages should have their CT reduced with great caution and also that 'bit seating' of the Triadan 06 CT should be minimal to avoid thermal damage or physical exposure of pulp horns. If during dental procedures, pink discolouration of secondary dentine is detected, the procedure should be halted immediately because of the presence of exposed vital pulp.

Acknowledgements

Our thanks to Nicole Du Toit and Andrea Ellis for their help with this project and to Carsten Staszky for reviewing the paper.

Manufacturers' addresses

¹Buehler, Coventry, UK.

²Malvern Lapidary, Malvern, Worcestershire, UK.

³SPSS, Chicago, Illinois, USA.

References

- Becker, E. (1962) Zahne. In: *Handbuch der speziellen pathologischen Anatomie der Haustiere*, 3rd edn., Eds: J. Dobberstein, J. Pallasse, H. Stunzi, and V. Band, Verlag Paul Parey, Berlin. pp 120-270.
- Brown, S.L., Arkins, S., Shaw, D.J. and Dixon, P.M. (2008) The occlusal angles of cheek teeth in normal horses and in horses with dental disease. *Vet. Rec.* **162**, 807-810.
- Dacre, I.T., Kempson, S. and Dixon, P.M. (2008) Pathological studies of cheek teeth apical infections in the horse: Part 1: Normal endodontic anatomy and dental structure of cheek teeth. *Vet. J.* **172**, 311-320.
- Dixon, P.M. (2002) The gross, histological and ultrastructural anatomy of equine teeth and their relationship to disease. *Proc. Am. Ass. equine Practnrs.* **48**, 421-437.
- Dixon, P.M., du Toit, N. and Dacre, I.T. (2009) Equine dental pathology. In: *Equine Dentistry*, 3rd edn., Eds: K.J. Easley, P.M. Dixon, and J.S. Schumacher, Elsevier Saunders, Philadelphia. In Press.
- Dixon, P.M., Tremaine, W.H., Pickles, K., Kuhns, L., Hawe, C., McCann, J., McGorum, B.C., Railton, D.I. and Brammer, S. (2000) Equine dental disease Part 3: A long-term study of 400 cases: Disorders of wear, traumatic damage and idiopathic fractures, tumours and miscellaneous disorders of the cheek teeth. *Equine vet. J.* **32**, 9-18.
- Du Toit, N., Kempson, S.A. and Dixon, P.M. (2008a) Donkey dental anatomy: Part 1: Gross and computed axial tomography examinations. *Vet. J.* **176**, 338-344.
- Du Toit, N., Burden, F.A. and Dixon, P.M. (2008b) Pathological investigation of caries and occlusal pulpar exposure in donkey cheek teeth using computerised axial tomography, histological and ultrastructural examinations. *Vet. J.* **178**, 387-395.
- Gasse, H., Westenberger, E. and Staszky, C. (2004) The endodontic system of equine cheek teeth: A re-examination of pulp horns and root canals in view of age-related physiological differences. *Pferdeheilkunde* **20**, 13-18.
- Kilic, S., Dixon, P.M. and Kempson, S.A. (1997) A light microscopic and ultrastructural examination of calcified dental tissues of horses: 3. Dentine. *Equine vet. J.* **29**, 206-212.
- Kirkland, K.D., Baker, G.J., Marretta, S.M., Eurell, J.A. and Losonsky, J.M. (1996) Effects of aging on the endodontic system, reserve crown, and root of equine mandibular cheek teeth. *Am. J. vet. Res.* **57**, 31-38.
- McDonnell, S.T., Hector, M.P. and Hannigan, A. (2004) Chewing side preferences in children. *J. oral Rehab.* **31**, 855-860.
- Nissan, J., Gross, M.D., Shifman, A., Tzadok, L. and Assif, D. (2004) Chewing side preference as a type of hemispheric laterality. *J. oral Rehab.* **31**, 412-416.
- Shaw, S., Dacre, I.T. and Dixon, P.M. (2008) Pathological studies of cheek teeth apical infections in the horse: Part 2: Quantitative measurements in normal equine dentine. *Vet. J.* **172**, 321-332.

Author contributions Both authors contributed to the initiation, conception, planning and execution for this study. P.M.D. was responsible for statistics and the paper was written by C.W.