



THE UNIVERSITY *of* EDINBURGH

Edinburgh Research Explorer

Resolution of hypoglycemia and cardiovascular dysfunction after rituximab treatment of insulin autoimmune syndrome

Citation for published version:

Church, D, Hunter, RW, Lyall, M, Clarke, C, Vliegenthart, ADB, Dear, JW, Semple, R, Dhaun, N & Dover, AR 2017, 'Resolution of hypoglycemia and cardiovascular dysfunction after rituximab treatment of insulin autoimmune syndrome', *Diabetes Care*. <https://doi.org/10.2337/dc17-0264>

Digital Object Identifier (DOI):

[10.2337/dc17-0264](https://doi.org/10.2337/dc17-0264)

Link:

[Link to publication record in Edinburgh Research Explorer](#)

Document Version:

Other version

Published In:

Diabetes Care

General rights

Copyright for the publications made accessible via the Edinburgh Research Explorer is retained by the author(s) and / or other copyright owners and it is a condition of accessing these publications that users recognise and abide by the legal requirements associated with these rights.

Take down policy

The University of Edinburgh has made every reasonable effort to ensure that Edinburgh Research Explorer content complies with UK legislation. If you believe that the public display of this file breaches copyright please contact openaccess@ed.ac.uk providing details, and we will remove access to the work immediately and investigate your claim.





**Resolution of hypoglycemia and cardiovascular dysfunction
after rituximab treatment of insulin autoimmune syndrome**

Journal:	<i>Diabetes Care</i>
Manuscript ID	DC17-0264.R2
Manuscript Type:	eLetter: Observation
Date Submitted by the Author:	n/a
Complete List of Authors:	<p>Church, David; University of Cambridge School of Clinical Medicine, Wellcome Trust-MRC Institute of Metabolic Science; NIHR Cambridge Biomedical Research Centre; Addenbrooke's Hospital, Clinical Immunology & Biochemistry</p> <p>Hunter, Robert; University of Edinburgh Queen's Medical Research Institute, Centre for Cardiovascular Science; Royal Infirmary of Edinburgh, Renal Medicine</p> <p>Lyall, Marcus; University of Edinburgh Queen's Medical Research Institute, Centre for Cardiovascular Science; Royal Infirmary of Edinburgh, Edinburgh Centre for Endocrinology & Diabetes</p> <p>Clarke, Catriona; Western General Hospital, Clinical Biochemistry</p> <p>Vliegenthart, Bastiaan; University of Edinburgh Queen's Medical Research Institute, Centre for Cardiovascular Science</p> <p>Dear, James; University of Edinburgh Queen's Medical Research Institute, Centre for Cardiovascular Science</p> <p>Semple, Robert; Cambridge University, Metabolic Research Laboratories</p> <p>Dhaun, Neeraj; University of Edinburgh Queen's Medical Research Institute, Centre for Cardiovascular Science; Royal Infirmary of Edinburgh, Renal Medicine</p> <p>Dover, Anna; University of Edinburgh Queen's Medical Research Institute, Centre for Cardiovascular Science; Royal Infirmary of Edinburgh, Edinburgh Centre for Endocrinology & Diabetes</p>

SCHOLARONE™
Manuscripts

Resolution of hypoglycemia and cardiovascular dysfunction after rituximab treatment of insulin autoimmune syndrome

David Church,^{1,2,3*} Robert W Hunter,^{4*} Marcus Lyall,^{4,5*} Catriona Clarke,⁶ A D Bastiaan Vliegthart,⁴ James W Dear,⁴ Robert Semple,^{1,2} Neeraj Dhaun⁴ & Anna R Dover^{4,5}

* *These authors contributed equally*

¹ University of Cambridge Metabolic Research Laboratories, Wellcome Trust-MRC Institute of Metabolic Science, Cambridge, UK

² National Institute for Health Research Cambridge Biomedical Research Centre, Cambridge, UK

³ The Pathology Partnership, Department of Clinical Biochemistry and Immunology, Addenbrooke's Hospital, Cambridge, UK

⁴ University/BHF Centre for Cardiovascular Science, University of Edinburgh, The Queen's Medical Research Institute, 47 Little France Crescent, Edinburgh, UK.

⁵ Edinburgh Centre for Endocrinology & Diabetes, Royal Infirmary of Edinburgh, UK.

⁶ Department of Clinical Biochemistry, Western General Hospital, Edinburgh, UK.

Correspondence to: Dr Robert W. Hunter
The Queen's Medical Research Institute
47 Little France Crescent
Edinburgh. EH16 4TJ
Telephone: (+44)-131-242-6786
E-mail: robert.hunter@ed.ac.uk

Running title: Vascular dysfunction in insulin autoimmune syndrome

Words: ~~631~~537
Figures: 1
References: ~~96~~
Pages: ~~67~~

Abstract

~~Insulin autoimmune syndrome (IAS) is a rare cause of spontaneous hypoglycemia in which insulin-antibody complexes circulate in abundance. The pathophysiology and optimal treatment remain unclear. Here we describe a case with novel adverse cardiovascular features where B-cell depletion with rituximab led to resolution of dysglycemia and this vascular phenotype.~~

History & Examination

A 37 year-old female presented to the emergency department having collapsed; venous glucose measured 50mg/dL. She reported recurrent dizziness since the birth of her fifth child 10 months previously ~~and had~~. ~~During several of these she~~ recorded low capillary blood glucose (36-52mg/dL) ~~when symptomatic~~. Her past history included gestational diabetes ~~during the most recent pregnancy~~, treated with insulin aspart (~~NovoRapid[®]~~), insulin glargine (~~Lantus[®]~~) and metformin. ~~These therapies had been discontinued 1 month post-partum.~~

Investigation

Blood count and renal, liver, thyroid and adrenal function were all normal. HbA_{1c} was 41mmol/mol (5.9%). ~~A~~ ~~e~~Continuous glucose monitoring ~~system~~ (CGMS) demonstrated early-morning (asymptomatic) hypoglycemia and post-prandial hyperglycemia. During hypoglycemia she had high circulating insulin (39,181pmol/L; C-peptide 1,046pmol/L). ~~Insulin assay was performed as previously described.(1) Only 4% of total immunoreactive insulin was recovered from plasma supernatant following polyethylene glycol precipitation, consistent with the presence of high molecular weight insulin immunoreactivity.~~ Insulin eluted from a gel filtration column ~~predominantly~~ in high molecular-weight fractions (**Figure**); ~~exogenous insulin exchange was employed to refute heterophilic antibody assay interference and confirm the presence of insulin-antibody complexes ('macroinsulin').(1)~~ Serum anti-insulin IgG concentration was 171mg/L (0-5).

We diagnosed insulin autoimmune syndrome (IAS), a term commonly used in patients without previous exposure to exogenous insulin. ~~Here, we cannot exclude that the insulin antibodies~~

~~generated were in response to exogenous insulin, but severe hypoglycemia did not develop until many months after cessation of insulin therapy. Moreover, a~~Antibodies developing ~~following after~~ exposure to exogenous insulin rarely bind insulin with sufficient capacity or affinity to perturb glycemia.(2) ~~Here, we cannot exclude that the insulin antibodies generated were in response to exogenous insulin, but severe hypoglycemia did not develop until many months after insulin therapy stopped and the post partum presentation is typical for recrudescence, or first appearance, of autoimmune disease.~~

The patient was fitted with ~~a~~CGMS with hypoglycemia alarm and prescribed a diet ~~comprising of~~ frequent low glycemic-index carbohydrate meals. ~~As s~~Significant hypoglycemia continued. ~~Thus,~~ prednisone was commenced ~~at~~ (1mg/kg/day) and titrated according to CBG readings ~~and symptoms~~ to 10mg/day over three months. To reduce anti-insulin antibodies, ~~we gave~~ the anti-CD20 monoclonal antibody rituximab ~~was administered.~~

~~A r~~Repeat CGM after six weeks revealed intermittent hypoglycemia and sustained daytime hyperglycemia. Over months, there were reductions in total insulin, anti-insulin antibody concentration and antibody-bound insulin (**Figure**). These were associated with reduced hypoglycemia and ~~improved~~improvement in hypoglycemic awareness. By 6 months, hypoglycemia was rare and post-prandial hyperglycemia had improved (~~CGM~~ peak glucose ~~on CGMS~~ 162.0mg/dL). There were no adverse events and prednisone was discontinued after 10 months, ~~following after~~ which no further hypoglycemia was recorded.

Recurrent hypoglycemia (~~in type I diabetes mellitus~~) is associated with endothelial dysfunction, inflammation and increased cardiovascular risk.(3) ~~In other contexts, rituximab has been shown to improve measures of endothelial function.(4)~~ Thus, we explored the cardiovascular phenotype associated with IAS, before and after treatment. Carotid-femoral pulse wave velocity (PWV) was 7.6m/s at presentation and 5.2m/s at 6 months (5.2-8.0m/s); there was no change in blood pressure over this period. This suggests elevated arterial stiffness at presentation, ~~and is~~ associated with

cardiovascular risk.⁽⁴⁾ ~~Other surrogate markers of endothelial dysfunction Plasma ADMA (an endogenous inhibitor of nitric oxide biosynthesis), endothelin 1 (a potent vasoconstrictor) and urate (associated with arterial stiffness and cardiovascular risk)~~ were all higher at disease presentation than at 6 months (**Figure**). Circulating ~~levels of~~ miR-126 rose following treatment (**Figure**). This microRNA is endothelial-enriched and is ~~considered~~ thought to maintain endothelial homeostasis and promote vasculogenesis.⁽⁴⁾ There was minimal change in control miR-122-5p.

Conclusions

Treatment of IAS is poorly defined. Historically, glucocorticoids and plasmapheresis were used for refractory cases. We show that B-cell depletion with rituximab induces a sustained reduction in anti-insulin antibodies, circulating insulin and the frequency of hypoglycemia. Rituximab has been used successfully in two other cases of IAS.^(5,6) However in one, concomitant use of plasmapheresis, methotrexate and intravenous immunoglobulin make it difficult to ascribe the beneficial therapeutic effect ~~solely~~ to rituximab.

~~Our report is novel in providing. We also present data to suggesting~~ an adverse vascular phenotype in IAS that is reversible when dysglycemia resolves. We speculate that recurrent ~~hypoglycemia/dysglycemia, hyperglycemia and circulating immune complexes~~ may contribute to vascular dysfunction in IAS, but further study is required to determine the underlying mechanism, ~~and how treatment improves vascular health.~~

Acknowledgements*Funding*

DC is funded by a Diabetes Research & Wellness Foundation Sutherland-Earl Clinical Fellowship (RG68554). RWH is supported by the *Wellcome Trust-University of Edinburgh* Institutional Strategic Support Fund. ND is supported by a *British Heart Foundation* Intermediate Clinical Research Fellowship (FS/13/30/29994). RS is funded by the Wellcome Trust (Grant WT098498).

Duality of interest

No potential conflicts of interest relevant to this article were reported.

Author contributions

DC, RWH and ML performed the study, analyzed the data and drafted the manuscript. CC, ADBV, JWD, RS, ND and AD analyzed the results. All authors revised the manuscript and approved the final version.

Guarantor's statement

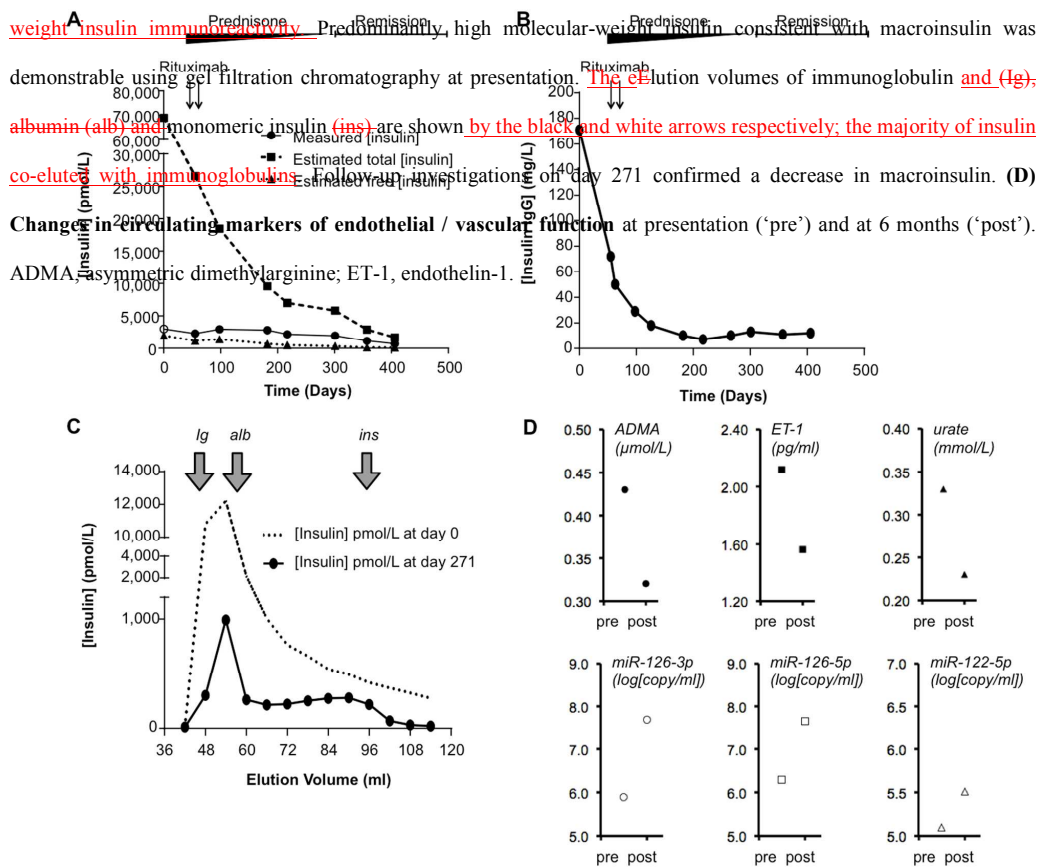
AD is the guarantor of this work and, as such, had full access to all the data in the study and takes responsibility for the integrity of the data and the accuracy of the data analysis.

References


1. Church D, Cardoso L, Bradbury S, Clarke C, Stears A, Dover A, et al. Diagnosis of insulin autoimmune syndrome using polyethylene glycol precipitation and gel filtration chromatography with ex vivo insulin exchange. *Clin Endocrinol (Oxf)*. 2016 Sep 2;
2. Trabucchi A, Iacono RF, Guerra LL, Faccinetti NI, Krochik AG, Arriazu MC, et al. Characterization of insulin antibodies by Surface Plasmon Resonance in two clinical cases: brittle diabetes and insulin autoimmune syndrome. *PLoS One*. 2013;8(12):e84099.
3. Joy NG, Tate DB, Younk LM, Davis SN. Effects of Acute and Antecedent Hypoglycemia on Endothelial Function and Markers of Atherothrombotic Balance in Healthy Humans. *Diabetes*. 2015 Jul;64(7):2571–80.
4. Wang S, Aurora AB, Johnson BA, Qi X, McAnally J, Hill JA, et al. The endothelial-specific microRNA miR-126 governs vascular integrity and angiogenesis. *Dev Cell*. 2008 Aug;15(2):261–71.
5. Jassam N, Amin N, Holland P, Semple RK, Halsall DJ, Wark G, et al. Analytical and clinical challenges in a patient with concurrent type 1 diabetes, subcutaneous insulin resistance and insulin autoimmune syndrome. *Endocrinol Diabetes Metab Case Rep*. 2014;2014:130086.
6. Saxon DR, McDermott MT, Michels AW. Novel Management of Insulin Autoimmune Syndrome with Rituximab and Continuous Glucose Monitoring. *J Clin Endocrinol Metab*. 2016 Mar 16;jc20161097.

Formatted: Font: Times New Roman, 10 pt, Bold

Figure: (A) Reportable insulin concentration, total insulin estimation & free insulin estimation against time. Day 0 is the day of first presentation; prednisone was commenced on day 44; rituximab was administered on days 44 and 58. Insulin concentrations shown here were measured using the DiaSorin LIAISON® assay; an alternative assay (Abbot Architect®) gave consistent results. Follow-up insulin determination was undertaken on neat plasma ('measured insulin') and after 1:49 dilution in 0.9% saline to promote insulin-antibody dissociation and reduce negative assay interference by antibodies ('total insulin') as well as in supernatant following polyethylene glycol precipitation ('free' insulin). ○ represents measured insulin concentration >3000pmol/L in neat plasma. **(B) Serum anti-insulin IgG concentration** (in-house ImmunoCAP® assay; reference range 0-5). **(C) Changes in plasma macroinsulin in response to immunosuppressive therapy.** At presentation, only 4% of total immunoreactive insulin was recovered from plasma supernatant following polyethylene glycol precipitation, consistent with the presence of high molecular-weight insulin immunoreactivity. Predominantly, high molecular-weight insulin consistent with macroinsulin was demonstrable using gel filtration chromatography at presentation. The elution volumes of immunoglobulin and (Ig), albumin (alb) and monomeric insulin (ins) are shown by the black and white arrows respectively; the majority of insulin co-elutes with immunoglobulins. Follow-up investigations on day 271 confirmed a decrease in macroinsulin. **(D) Change in circulating markers of endothelial / vascular function** at presentation ('pre') and at 6 months ('post'). ADMA, asymmetric dimethylarginine; ET-1, endothelin-1.



|



Resolution of hypoglycemia and cardiovascular dysfunction after rituximab treatment of insulin autoimmune syndrome

David Church,^{1,2,3*} Robert W Hunter,^{4*} Marcus Lyall,^{4,5*} Catriona Clarke,⁶ A D Bastiaan Vliegthart,⁴ James W Dear,⁴ Robert Semple,^{1,2} Neeraj Dhaun⁴ & Anna R Dover^{4,5}

** These authors contributed equally*

¹ University of Cambridge Metabolic Research Laboratories, Wellcome Trust-MRC Institute of Metabolic Science, Cambridge, UK

² National Institute for Health Research Cambridge Biomedical Research Centre, Cambridge, UK

³ The Pathology Partnership, Department of Clinical Biochemistry and Immunology, Addenbrooke's Hospital, Cambridge, UK

⁴ University/BHF Centre for Cardiovascular Science, University of Edinburgh, The Queen's Medical Research Institute, 47 Little France Crescent, Edinburgh, UK.

⁵ Edinburgh Centre for Endocrinology & Diabetes, Royal Infirmary of Edinburgh, UK.

⁶ Department of Clinical Biochemistry, Western General Hospital, Edinburgh, UK.

Correspondence to: Dr Robert W. Hunter
The Queen's Medical Research Institute
47 Little France Crescent
Edinburgh. EH16 4TJ
Telephone: (+44)-131-242-6786
E-mail: robert.hunter@ed.ac.uk

Running title: Vascular dysfunction in insulin autoimmune syndrome

Words: 537

Figures: 1

References: 6

Pages: 6

History & Examination

A 37 year-old female presented to the emergency department having collapsed; venous glucose measured 50mg/dL. She reported recurrent dizziness since the birth of her fifth child 10 months previously and had recorded low capillary blood glucose (36-52mg/dL) when symptomatic. Her past history included gestational diabetes during the most recent pregnancy, treated with insulin aspart, insulin glargine and metformin. These therapies had been discontinued 1 month post-partum.

Investigation

Blood count and renal, liver, thyroid and adrenal function were all normal. HbA_{1c} was 41mmol/mol (5.9%). Continuous glucose monitoring (CGM) demonstrated early-morning (asymptomatic) hypoglycemia and post-prandial hyperglycemia. During hypoglycemia she had high circulating insulin (39,181pmol/L; C-peptide 1,046pmol/L). Insulin assay was performed as previously described.(1) Insulin eluted from a gel filtration column in high molecular-weight fractions (**Figure**). Serum anti-insulin IgG concentration was 171mg/L (0-5).

We diagnosed insulin autoimmune syndrome (IAS), a term commonly used in patients without previous exposure to exogenous insulin. Here, we cannot exclude that the insulin antibodies generated were in response to exogenous insulin, but severe hypoglycemia did not develop until many months after cessation of insulin therapy. Moreover, antibodies developing after exposure to exogenous insulin rarely bind insulin with sufficient capacity or affinity to perturb glycemia.(2)

The patient was fitted with CGM with hypoglycemia alarm and prescribed a diet of frequent low glycemic-index carbohydrate meals. As significant hypoglycemia continued, prednisone was commenced (1mg/kg/day) and titrated according to CBG readings to 10mg/day over three months. To reduce anti-insulin antibodies, we gave the anti-CD20 monoclonal antibody rituximab.

Repeat CGM after six weeks revealed intermittent hypoglycemia and sustained daytime hyperglycemia. Over months, there were reductions in total insulin, anti-insulin antibody concentration and antibody-bound insulin (**Figure**). These were associated with reduced

hypoglycemia and improved hypoglycemic awareness. By 6 months, hypoglycemia was rare and post-prandial hyperglycemia had improved (CGM peak glucose 162.0mg/dL). There were no adverse events and prednisone was discontinued after 10 months, after which no further hypoglycemia was recorded.

Recurrent hypoglycemia is associated with endothelial dysfunction, inflammation and increased cardiovascular risk.(3) Thus, we explored the cardiovascular phenotype associated with IAS, before and after treatment. Carotid-femoral pulse wave velocity (PWV) was 7.6m/s at presentation and 5.2m/s at 6 months (5.2-8.0m/s); there was no change in blood pressure over this period. This suggests elevated arterial stiffness at presentation, associated with cardiovascular risk. Other surrogate markers of endothelial dysfunction were all higher at disease presentation than at 6 months (**Figure**). Circulating miR-126 rose following treatment (**Figure**). This microRNA is endothelial-enriched and is thought to maintain endothelial homeostasis and promote vasculogenesis.(4) There was minimal change in control miR-122-5p.

Conclusions

Treatment of IAS is poorly defined. Historically, glucocorticoids and plasmapheresis were used for refractory cases. We show that B-cell depletion with rituximab induces a sustained reduction in anti-insulin antibodies, circulating insulin and the frequency of hypoglycemia. Rituximab has been used successfully in two other cases of IAS.(5,6) However in one, concomitant use of plasmapheresis, methotrexate and intravenous immunoglobulin make it difficult to ascribe the beneficial therapeutic effect to rituximab.

Our report is novel in providing data to suggest an adverse vascular phenotype in IAS that is reversible when dysglycemia resolves. We speculate that recurrent dysglycemia may contribute to vascular dysfunction in IAS, but further study is required to determine the underlying mechanism.

Acknowledgements

Funding

DC is funded by a Diabetes Research & Wellness Foundation Sutherland-Earl Clinical Fellowship (RG68554). RWH is supported by the *Wellcome Trust-University of Edinburgh* Institutional Strategic Support Fund. ND is supported by a *British Heart Foundation* Intermediate Clinical Research Fellowship (FS/13/30/29994). RS is funded by the Wellcome Trust (Grant WT098498).

Duality of interest

No potential conflicts of interest relevant to this article were reported.

Author contributions

DC, RWH and ML performed the study, analyzed the data and drafted the manuscript. CC, ADBV, JWD, RS, ND and AD analyzed the results. All authors revised the manuscript and approved the final version.

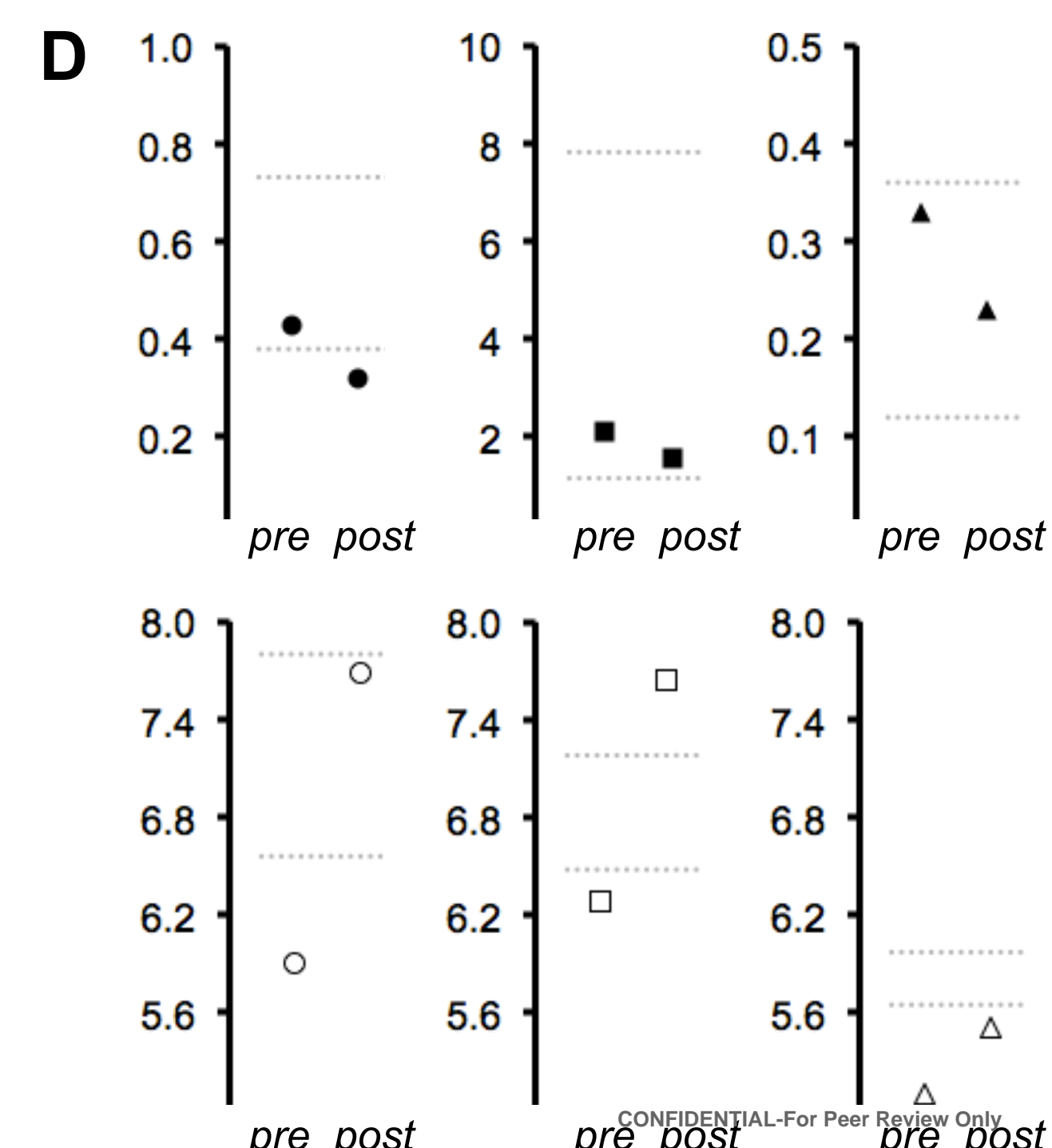
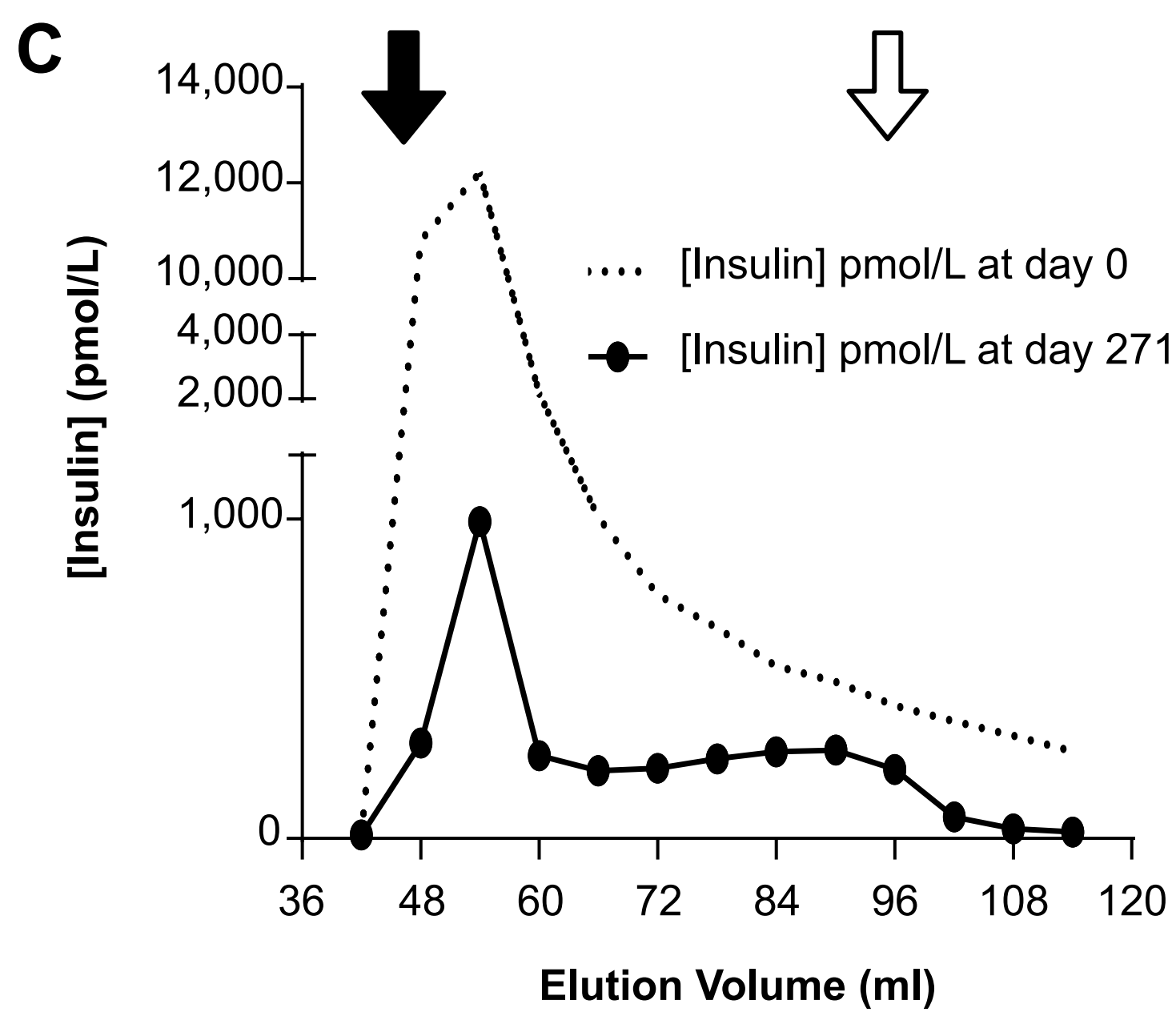
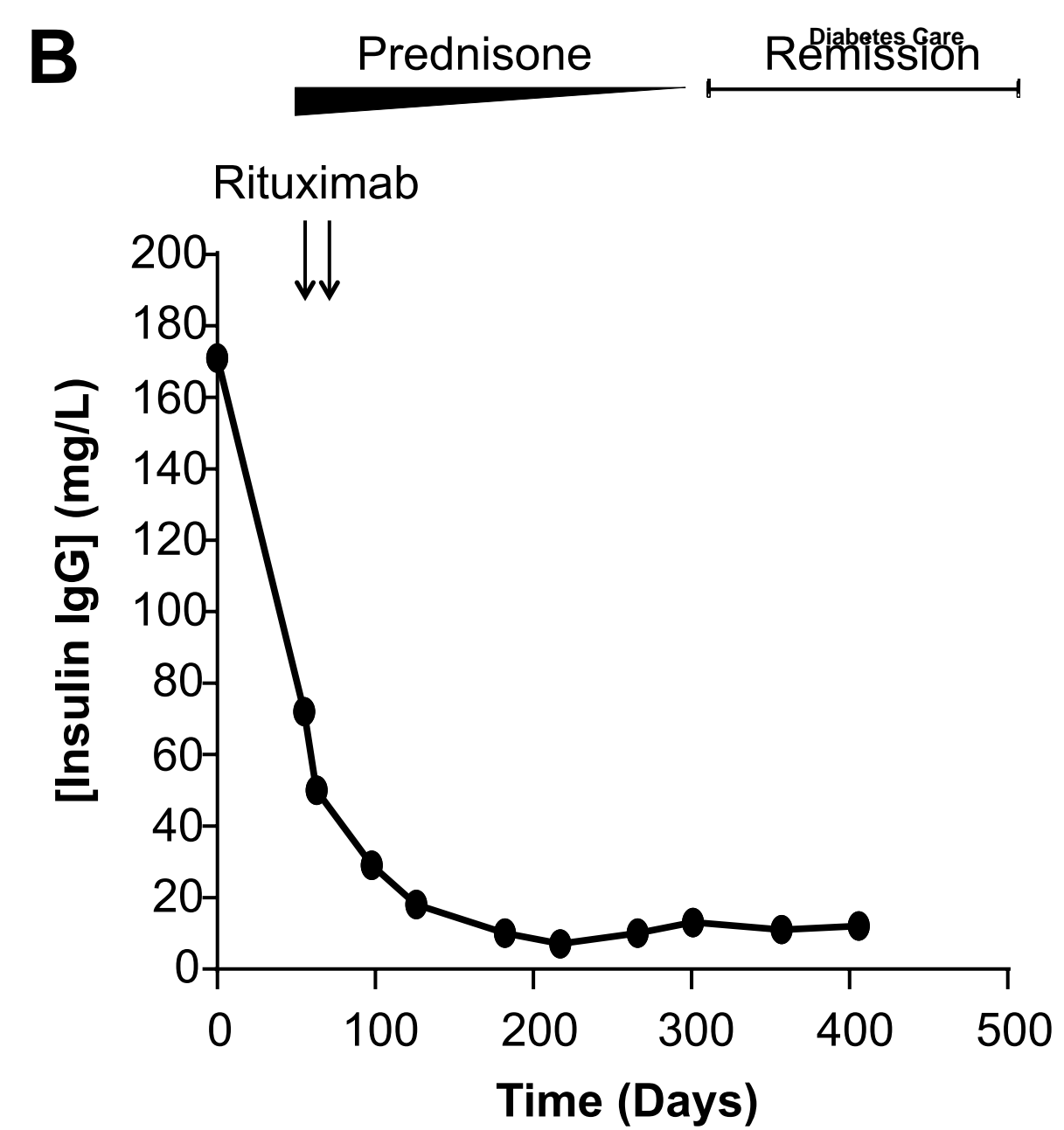
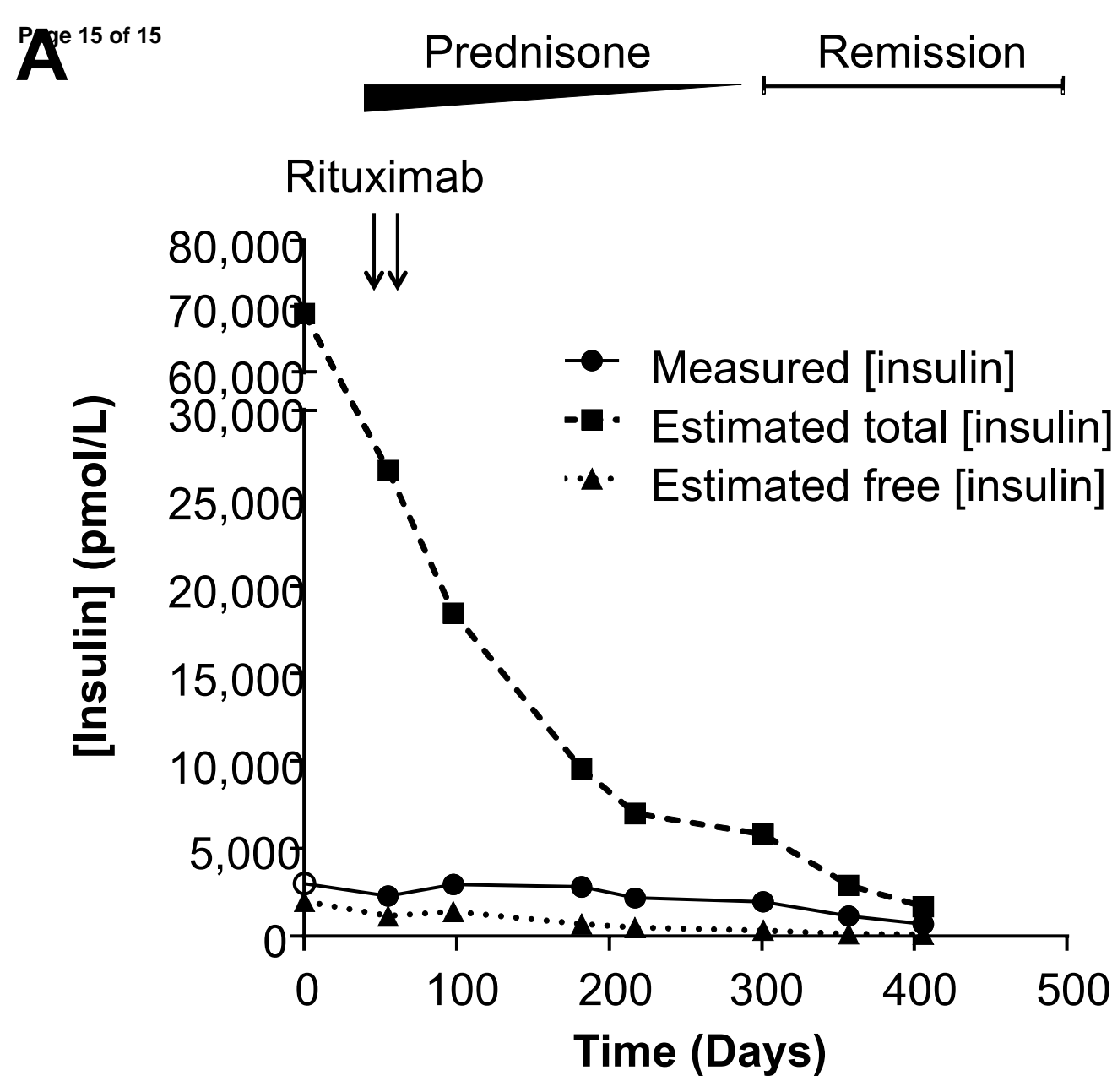
Guarantor's statement

AD is the guarantor of this work and, as such, had full access to all the data in the study and takes responsibility for the integrity of the data and the accuracy of the data analysis.

References

1. Church D, Cardoso L, Bradbury S, Clarke C, Stears A, Dover A, et al. Diagnosis of insulin autoimmune syndrome using polyethylene glycol precipitation and gel filtration chromatography with ex vivo insulin exchange. *Clin Endocrinol (Oxf)*. 2016 Sep 2;
2. Trabucchi A, Iacono RF, Guerra LL, Faccinetti NI, Krochik AG, Arriazu MC, et al. Characterization of insulin antibodies by Surface Plasmon Resonance in two clinical cases: brittle diabetes and insulin autoimmune syndrome. *PLoS One*. 2013;8(12):e84099.
3. Joy NG, Tate DB, Younk LM, Davis SN. Effects of Acute and Antecedent Hypoglycemia on Endothelial Function and Markers of Atherothrombotic Balance in Healthy Humans. *Diabetes*. 2015 Jul;64(7):2571–80.
4. Wang S, Aurora AB, Johnson BA, Qi X, McAnally J, Hill JA, et al. The endothelial-specific microRNA miR-126 governs vascular integrity and angiogenesis. *Dev Cell*. 2008 Aug;15(2):261–71.
5. Jassam N, Amin N, Holland P, Semple RK, Halsall DJ, Wark G, et al. Analytical and clinical challenges in a patient with concurrent type 1 diabetes, subcutaneous insulin resistance and insulin autoimmune syndrome. *Endocrinol Diabetes Metab Case Rep*. 2014;2014:130086.
6. Saxon DR, McDermott MT, Michels AW. Novel Management of Insulin Autoimmune Syndrome with Rituximab and Continuous Glucose Monitoring. *J Clin Endocrinol Metab*. 2016 Mar 16;jc20161097.

Figure: (A) Reportable insulin concentration, total insulin estimation & free insulin estimation against time. Day 0 is the day of first presentation; prednisone was commenced on day 44; rituximab was administered on days 44 and 58. Insulin concentrations shown here were measured using the DiaSorin LIAISON® assay; an alternative assay (Abbot Architect®) gave consistent results. Follow-up insulin determination was undertaken on neat plasma ('measured insulin') and after 1:49 dilution in 0.9% saline to promote insulin-antibody dissociation and reduce negative assay interference by antibodies ('total insulin') as well as in supernatant following polyethylene glycol precipitation ('free' insulin). ○ represents measured insulin concentration >3000pmol/L in neat plasma. **(B) Serum anti-insulin IgG concentration** (in-house ImmunoCAP® assay; reference range 0-5). **(C) Changes in plasma macroinsulin in response to immunosuppressive therapy.** At presentation, only 4% of total immunoreactive insulin was recovered from plasma supernatant following polyethylene glycol precipitation, consistent with the presence of high molecular-weight insulin immunoreactivity. Predominantly high molecular-weight insulin consistent with macroinsulin was demonstrable using gel filtration chromatography at presentation. The elution volumes of immunoglobulin and monomeric insulin are shown by the black and white arrows respectively; the majority of insulin co-eluted with immunoglobulins. Follow-up investigations on day 271 confirmed a decrease in macroinsulin. **(D) Changes in circulating markers of endothelial / vascular function** at presentation ('pre') and at 6 months ('post'). ADMA, asymmetric dimethylarginine; ET-1, endothelin-1.



- asymmetric dimethylarginine (ADMA) ($\mu\text{mol/L}$)
- endothelin-1 (pg/ml)
- ▲ urate (mmol/L)
- miR-126-3p (log[copy/ml])
- miR-126-5p (log[copy/ml])
- △ miR-122-5p (log[copy/ml])