THE UNIVERSITY of EDINBURGH

Edinburgh Research Explorer

2016 Comprehensive Update of the Banff Working Group on Liver Allograft Pathology: Introduction of Antibody-Mediated Rejection

Citation for published version:
Demetris, AJ, Bellamy, C, Hübscher, SG, O'leary, J, Randhawa, PS, Feng, S, Neil, D, Colvin, RB, Mccaughan, G, Fung, JJ, Del Bello, A, Reinholt, FP, Haga, H, Adeyi, O, Czaja, AJ, Schiano, T, Fiel, MI, Smith, ML, Sebagh, M, Tanigawa, RY, Yilmaz, F, Alexander, G, Baiocchi, L, Balasubramanian, M, Batal, I, Bhan, AK, Bucuvalas, J, Cerski, CTS, Charlotte, F, De Vera, ME, Elmonayeri, M, Fontes, P, Furth, EE, Gouw, ASH, Hafezi-bakhtiari, S, Hart, J, Honsova, E, Ismail, W, Itoh, T, Jhala, NC, Khettry, U, Klintmalm, GB, Knechtle, S, Koshiba, T, Kozlowski, T, Lassman, CR, Lerut, J, Levitsky, J, Licini, L, Liotta, R, Mazariegos, G, Minervini, MI, Misdraji, J, Mohanakumar, T, Mölne, J, Nasser, I, Neuberger, J, O'neil, M, Pappo, O, Petrovic, L, Ruiz, P, Sağol, Ö, Sanchez Fueyo, A, Sasatomi, E, Shaked, A, Shiller, M, Shimizu, T, Sis, B, Sonzogni, A, Stevenson, HL, Thung, SN, Tisone, G, Tsamandas, AC, Wernerson, A, Wu, T, Zeevi, A & Zen, Y 2016, '2016 Comprehensive Update of the Banff Working Group on Liver Allograft Pathology: Introduction of Antibody-Mediated Rejection', *American Journal of Transplantation*, vol. 16, no. 10, pp. 2816-2835. https://doi.org/10.1111/ajt.13909

Digital Object Identifier (DOI):
10.1111/ajt.13909

Link:
Link to publication record in Edinburgh Research Explorer

Document Version:
Peer reviewed version

Published In:
American Journal of Transplantation

General rights
Copyright for the publications made accessible via the Edinburgh Research Explorer is retained by the author(s) and / or other copyright owners and it is a condition of accessing these publications that users recognise and abide by the legal requirements associated with these rights.

Take down policy
The University of Edinburgh has made every reasonable effort to ensure that Edinburgh Research Explorer content complies with UK legislation. If you believe that the public display of this file breaches copyright please contact openaccess@ed.ac.uk providing details, and we will remove access to the work immediately and investigate your claim.

OPEN ACCESS

Download date: 12. Oct. 2024

2016 Comprehensive Update of the Banff Working Group on Liver Allograft Pathology: Introduction of Antibody-mediated Rejection by The Banff Working Group

Abbreviations: ADCC: antibody-dependent cellular cytotoxicity; AIH: autoimmune hepatitis; AMR: antibody-mediated rejection; C4d: complement component 4d; CDC: complement-dependent cytotoxicyt; DSA: donor-specific antibodies; FFPE: formalin- fixed paraffin-embedded; HCV: hepatitis C virus; HLA: human leukocyte antigen; MFI: mean fluorescent intensity; OLTx: orthotopic liver transplantation; TCMR: T cell- mediated rejection;

INTRODUCTION

The Banff Foundation and other professional societies endorse international consensus documents containing recommendations and criteria for solid organ allograft rejection, including kidney(1, 2), heart(3, 4), liver(5-7), lung(4), and pancreas(8). Kidney, heart, and pancreas consensus systems currently recognize two distinct, but sometimes overlapping forms of allograft rejection that are based primarily on immunological mechanisms of graft injury: 1) "T cell-mediated (TCMR)"; and 2) "antibody-mediated rejection (AMR)". TCMR terminology is preferred over older terms, such as "cellular" rejection; AMR terminology is preferred over older terms such as "humoral" rejection. TCMR and AMR can occur in relative isolation or often in combination, especially in liver allografts.

TCMR manifests consistently across all organs as allograft infiltration by admixture of inflammatory cells, consisting primarily of CD4+/CD3+ and CD8+/CD3+ T cells accompanied by variable numbers of CD20+ B cells, monocytes/macrophages, NK cells, eosinophils, plasma cells, neutrophils and mast cells (9). TCMR rejection severity grading is based on: a) the intensity and distribution of inflammation and tissue damage; and b) on direct or indirect signs of vascular injury, such as lymphocytic arteritis, which can also be seen in AMR, confluent necrosis, and/or microvascular disruption and non-procedural interstitial hemorrhage. Further qualifying descriptors of TCMR include terms such as "acute" or "active" and "chronic" or "late", based on the timing of the episode after transplantation, which likely reflect mechanism of antigen presentation.

Early (<6 month) or acute TCMR is likely attributable to direct, while late or chronic likely depends more on indirect allo-antigen presentation. For example, in liver allografts, there are well-described and recognized differences in the appearance(-s) of TCMR early (<6 month) and late (>6 months) after transplantation, emphasized in previous Banff liver allograft documents(5, 10). "Early (< 6 months)" TCMR shows a greater tendency for prevalent inflammatory bile duct damage, a pleomorphic inflammation composition (lymphocytes, macrophages, eosinophils, neutrophils, and plasma cells), and paucity of necro-inflammatory-type interface activity compared to "late" TCMR(5, 10).

Late TCMR (>6 months), in contrast, usually shows less prevalent inflammatory bile duct damage, more homogeneous inflammatory infiltrate composition (lymphocytes, macrophages, and plasma cells), and a greater tendency for low-grade interface and perivenular necro-inflammatory-type activity(5, 10). As originally predicted(11), many cases of idiopathic post-transplant hepatitis would probably now be categorized as late onset T cell and/or chronic AMR (see below) in DSA+ patients. Therefore, "idiopathic post-transplant hepatitis", as a specific diagnostic entity, should decrease over time as more causes of the inflammation are discovered. However, occasional cases likely will still occur in DSA-negative patients. Early and late TCMR, however, are not strictly time-delineated and considerable overlap exists so strict separation between the two can be problematic (5, 10).

Acute AMR also manifests fairly consistently across kidney, heart, and pancreas allografts as serological evidence of allograft injury and/or dysfunction specific to each organ and microvascular endothelial cell hypertrophy, capillary dilatation and rarefaction(12, 13), and so-called "capillaritis" or "microvasculitis". Capillaritis is recognized as intra-luminal pooling and/or margination of various leukocyte subsets (monocytes, macrophages, lymphocytes, neutrophils, and eosinophils) in dilated and irregularly-shaped capillaries(14-19). Liver allografts, however, exhibit a widely-recognized, well-documented, and accepted resistance to AMR (reviewed in (20-22)), discussed below. Consequently, a comparatively low incidence of acute liver allograft AMR has resulted in suboptimal recognition. Opportunities exist, however, to understand how the liver differs from other organs and to incorporate diagnostic approaches that have proved successful in other organs(1-4, 19).

The primary goals of this manuscript, therefore, are to: a) update terminology for liver allograft rejection; b) provide recommendations for tissue C4d staining and interpretation; c) introduce concepts and standardized criteria for recognition of AMR; d) provide other updates and suggestions for future investigations.

TERMINOLOGY UPDATES

Replacement of older with newer terminology for various categories of rejection is encouraged:

Older (discouraged) Terminology	**Newer (preferred) Terminology**
Humoral rejection	Antibody-mediated rejection (AMR)
(Acute) cellular rejection	T cell-mediated rejection (TCMR)
De novo auto-immune hepatitis	Plasma cell rich-rejection
Plasma cell hepatitis	

Typical T cell-Mediated Rejection (TCMR), Chronic Rejection, and Fibrosis Staging Favorable studies of accuracy, reproducibility, and prognostic significance of Banff classification have resulted in widespread adoption and, therefore, enabled an international comparison of rejection incidence and severity (23-27). But as emphasized in previous Banff Liver Consensus documents (5, 6, 10, 24), TCMR alone, usually responds favorably to increased immunosuppression and rarely leads to liver allograft failure (23-27). Little impetus exists, therefore, to alter the approach or criteria for typical TCMR (Tables 1 and 2). The overall incidence of TCMR after liver transplantation varies from 20-60%(28-30). Typical or classical ductopenic chronic rejection is currently uncommon and pressing needs to update criteria are similarly not needed at this time.

It has become apparent, however, that patterns of fibrosis not typically seen in association with chronic viral and autoimmune hepatitis commonly occur in pediatric and adult liver allografts. These can occur with or without preceding TCMR episodes and some patterns might represent a manifestation of chronic antibody-mediated injury or mixed TCMR and chronic AMR(31-34). We recommend, therefore, to stage fibrosis in three distinct compartments, as suggested by Venturi et al(35) for pediatric liver allografts(35): 1) portal/periportal; 2) sinusoidal; and 3) peri-central or perivenular (Table 2). The findings are scored semi-quantitatively on a scale of 0 (none) to 3 (diffuse/bridging).

Atypical Presentations: Plasma Cell-Rich Rejection: "Plasma cell hepatitis" also known as "*de novo* autoimmune hepatitis", is a poorly understood and uncommon (~3-5% of recipients) cause of usually late (often >1 year) graft dysfunction that resembles native liver AIH and often arises in HCV+ recipients treated with interferon (36-41). A number of observations suggest that this entity likely represents a variant of TCMR or mixed TCMR/AMR overlapping with autoimmunity (36, 37, 40-44). Therefore, we are recommending the term "plasma cell-rich rejection" be applied to those cases in patients ***without*** AIH as an original disease. Evidence supporting a contribution of alloimmunity includes: 1) more prevalent and severe bile duct damage than seen in typical autoimmune hepatitis (AIH)(37); 2) an over-representation of IgG4+ plasma cells not present in otherwise typical AIH(37) (>50% in allografts in one study(37), but ~3% in native liver AIH(45)); 3) more aggressive plasma cell-rich central perivenulitis than seen in typical AIH(36, 37, 46-48); 4) DSA (esp. anti-DQ) production in ~60%(44); 5) portal microvascular C4d deposition in nearly all affected patients in two studies (49, 50); 6) mismatching for atypical liver/kidney microsomal autoantibodies directed against the cytosolic enzyme glutathione-S-transferase T1 (GSST1) in null GSTT1 genotype recipients of GSTT1+ donor livers(47, 50, 51); 7) precipitation by γ-interferon treatment; 8) risk factors of TCMR and steroid-dependence(39, 52); and 9) possible antibody-dependent effector mechanism (53-55); and 10) features of TCMR or chronic rejection have been reported to occur in 18-24% cases(39, 48).

Evidence supporting a contribution of autoimmunity includes histopathological similarities to native liver AIH and detection of a variety of classical(38, 39) and other autoantibodies, such as cytokeratin 8/18 auto-antibodies(56) and atypical liver-kidney microsomal (LKM) antibodies directed at isoforms of carbonic anhydrase III, subunit β1 of proteasome, and members of different glutathione S-transferase (GST) families(57), and angiotensin II Type-1 receptor antibodies combined with HLA DSA (58).

Criteria for the histopathological diagnosis of plasma cell-rich rejection are shown in Table 3. C4d stains are recommended on all biopsies diagnosed as plasma cell-rich rejection; IgG and IgG4 stains might also be considered to

better understand the underlying pathophysiology in some recipients (37). More work is needed to distinguish recurrent AIH from plasma cell-rich rejection.

The approach and response to treatment has been recently reviewed(59): corticosteroids alone or in combination with Azathioprine, similar to native liver AIH treatment, constitute the essential therapy(59), but high doses of steroids are often required and when tapered the biopsy findings might recur.

INCORPORATION OF ANTIBODY-MEDIATED REJECTION (AMR) INTO THE BANFF SCHEMA

General Considerations

Factors influencing relative susceptibility and resistance mechanisms: Susceptibility to AMR for any vascularized allograft is dependent on antibody class, titer, specificity and timing, as well as density and distribution of target antigen expression(20). AMR has been recognized in clinical liver transplantation practice for nearly 3 decades: first with ABO-incompatible allografts (60-64) and later with lymphocytotoxic antibodies or DSA (65-69). Inclusion of ABO-incompatible AMR in the Banff Schema is overdue, but inclusion of ABO-compatible AMR has been delayed because of widespread recognition that human liver allografts: a) were less sensitive than kidney allografts to acute adverse consequences of pre-formed DSA(70); and b) could protect subsequent kidney and heart allografts from the same donor from AMR in most, but not all, sensitized experimental animals(71, 72) and humans(73, 74).
Indeed, Olausson et al(75) reported successful subsequent kidney transplants in 5/7 broadly sensitized (as determined by cell-based assays) recipients when simultaneously underwent partial auxiliary liver allografts from the same donors for the purpose of protecting the liver. Two of seven, however, appeared to have experienced renal allograft AMR, perhaps related to class II DSA. Acute kidney allograft AMR was not seen in all sensitized recipients of combined liver-kidney allografts, but lower patient and kidney graft survival (~40%) did not seem to influence the practice of simultaneous liver- kidney in sensitized recipients.

A variety of liver allograft AMR-resistance mechanisms all likely contribute (reviewed in (20, 21, 76)):

1) Kupffer cells clearance of DSA, activated complement, platelet aggregates(77), and immune complexes formed between soluble donor class I HLA antigens and anti-class I DSA(71, 72, 78-80). Supporting evidence includes:

a) *increased* AMR susceptibility and *decreased* protection of sequentially- placed extra-hepatic allografts in recipients of Kupffer cell-depleted liver allografts(71, 72, 78-80); and

b) amelioration of acute heart allograft AMR in sensitized recipients by transfection of donor class I genes that produce soluble HLA antigens, mimicking the effect of simultaneous liver allografts(81).

2) Variable hepatic (reviewed in (82)) versus strong and constitutive kidney(83) and heart(84) microvascular class II expression provide less class II DSA targets, which might explain the preferential clearance of class I versus class II DSA after transplantation(85, 86).

3) Large liver size dilutes antibody- binding across a larger endothelial cell surface; potentially explaining increased AMR susceptibility in reduced-size allografts(80).

4) Liver sinusoidal endothelial cells and Kupffer cells express Fc receptors(87, 88), lack a typical basement membrane, and normally lined by Kupffer cells that can play protective roles (described above); all of these factors potentially influence antibody-endothelial interactions.

5) The liver's regenerative capacity and ability to heal either without fibrosis or reverse fibrosis(89).

Target antigen expression: ABH blood group antigens are ubiquitously expressed on all hepatic endothelial cells (reviewed in (82)). HLA class I and II antigen expression has been studied in formalin-fixed, paraffin-embedded and frozen "normal" human livers (e.g. organ donors, biopsies obtained from patients with non-hepatic diseases, un-involved liver resected for tumors) using immunostaining (90-102): all studies reported diffuse and strong class I HLA expression on all cell types, except hepatocytes where class I HLA expression is weaker. HLA class II expression is strongest on portal, perivenular, and subcapsular dendritic cells, and Kupffer cells with DQ demonstrating the weakest expression. Portal vein branch endothelia class II expression was consistently negative, but portal capillary, sinusoidal and central vein endothelia varies from negative to focally positive(90-102). Few studies, however,

specifically addressed class II expression in portal capillary/peribiliary plexus, lymphatic capillaries, inlet venules, and the peribiliary plexus of large extra-hepatic bile ducts. Therefore, more work is needed on this topic. Co-existent disorders, such as recurrent HCV and TCMR, can upregulate allograft microvascular and other cell HLA II and thereby increase DSA target antigen density and accentuate the underlying pathology, discussed below(21, 22, 103).

ACUTE ANTIBODY-MEDIATED INJURY

Antibody Characteristics:

By definition, IgM and IgG isoagglutinins are naturally encountered when blood group barriers are crossed and antibody titer and complement- fixing ability influence pathogenic potential(60, 104-106). Liver allograft injury is more often encountered when recipients develop isoagglutinin dilutions > 1:64 after transplantation, which almost invariably manifest graft dysfunction and significant histopathology damage(105, 106). Reduction to titers < 1:16 by plasmapheresis/exchange has been targeted to largely avoid ABO-I AMR(104). Cell-based donor-specific antibody (DSA) detection assays show 8 – 15% recipients are DSA positive (>30 - 50% lysis)(65, 107, 108); current solid phase assays validated and extended these findings(22). Pre-transplant CDC+-causing antibodies are encountered in ~10 - 15% of recipients with a female and autoimmune predilection(109-113). Assays linking the two eras show the ~96% of cell-based CDC-negative recipients also lacked DSA; however, >50% of isolated class I or II DSA+ patients were CDC- negative(86).

Pre-transplant DSA-positivity with clinical significance in potential liver allograft recipients has been tentatively defined as MFI ≥ 5000. However, the cut-off for positivity varies by laboratory and more study and standardization are needed. MFI, however, is not equivalent to traditional metrics of antibody prevalence or avidity. Empirically, high MFI for individual or aggregated anti-HLA DSA are a useful indicator of clinically significant DSA, but without additional testing (e.g. titration studies, C1q assay), an isolated MFI value can be misleading(114): low MFI might represent a high titer complement-binding DSA (prozone effect).

Regardless, the vast majority of lower MFI class I DSA (<10,000 MFI) resolves shortly after transplantation, but C4d deposits can be detected in some highly sensitized recipients early after orthotopic liver transplantation (OLTx) without apparent short-term, but of unknown long term consequences (109, 113). Clearly, however, preformed DSA does not adversely influence short-term survival in the vast majority of low to moderately (< 8,000 MFI) sensitized recipients (109-113, 115). High-MFI class II DSA (≥10,000), however, persist in ~1/3 of recipients (109) associated with an increased risk of early TCMR, and perhaps, mixed TCMR and acute AMR(109). A tiny fraction (<5%) of highly sensitized (DSA+) recipients have sufficient DSA (usually multiple class I and II usually in high MFI/titers) to cause clinically significant acute AMR(112, 115, 116).

The most dramatic and clinically significant acute AMR usually occurs within the first several weeks after transplantation in highly sensitized recipients(67, 107), who usually harbor polyspecific high titer/high MFI antibodies; many also fix complement, but non-completing fixing antibodies cannot be always considered to be benign. Rapid allograft failure caused by frank acute AMR: microvascular injury, thrombosis, and hemorrhagic necrosis(117) can rarely occur, but a less fulminant acute AMR presentation is more commonly seen, characterized by graft dysfunction/hyperbilirubinemia(107, 108,
115, 118), thrombocytopenia(107, 108, 115, 118), low serum complement levels(107,108), DSA persistence after transplant (more common with class II), appearance of circulating immune complexes(20, 107, 108), and histopathological changes discussed below. The degree of post-transplant transaminasemia is generally out of proportion to the donor liver quality and often the downward trend of transaminasemia is blunted.

Lower-level sensitization usually results in rapid DSA disappearance and either no injury or transient antibody-mediated damage often misrepresented as “preservation injury” (20, 107, 108).

The rapid DSA clearance accounts for protection of sequentially-placed allografts from the same donor(73, 119). Recent studies, however, show this “protection” is occasionally only partial and the kidney can experience AMR: this occurs more commonly with class II than class I DSA, which rarely causes problems (85, 109, 120). Perhaps less efficient class II DSA clearing is attributable to lower density class II expression in the liver. Acute AMR can also occur later (>6 months) after transplantation(121) associated with the appearance of de novo DSA, discussed in greater detail, below.

Acute AMR Histopathology

Acute AMR is recognized in all solid organ allograft primarily by capillary and other micro-vessel pathology. Linear and occasionally granular microvascular (portal vein and capillary, inlet venule, and focal sinusoidal and central vein) endothelial cell C4d deposition is usually present and required under current criteria. Routine histopathological changes in non-hepatic allografts include endothelial cell hypertrophy/enlargement, leukocyte sludging and/or margination [macrophages, eosinophils, neutrophils, and lymphocytes (e.g. NK cells)] within dilated capillaries/microvasculature, and edema followed, in severe cases, by microvascular disruption and interstitial hemorrhage (1, 3, 12-17, 19, 122, 123). Persistent and/or recurrent AMR in kidney allografts eventually leads to lamination of capillary basement membranes, and capillary rarefaction and loss and replacement fibrosis in both kidney and heart allografts(12, 13, 15-17, 122, 124).

ABO-incompatible liver allografts: Post-reperfusion biopsies of ABO-incompatible grafts in recipients with high pre- titer (>1:32) isoagglutinins, usually show sinusoidal and portal vein platelet-fibrin thrombi, clustering of neutrophils, and red blood cell sludging in the sinusoids. These changes are often accompanied by focal hemorrhage into the space of Disse and portal connective tissue, focal hepatocellular cytoaggregation, or single cell acidophilic necrosis(60). Follow-up biopsies within the first week in those at risk of developing acute AMR (50% of recipients that develop high titer (>1:64) isoagglutinins(105)) after transplantation show portal microvascular endothelial cell enlargement/hypertrophy, focal fibrin deposition, portal edema, small, often periportal, hepatocyte clusters with coagulative necrosis, and increased red cell congestion and hemorrhage(60, 105). Other portal tract changes include variable fibrinoid degeneration of small portal artery branches, mild usually neutrophilic inflammation, focal cholangitis/cholangiolitis, and an interface ductular reaction(60, 105). Portal microvascular (portal veins and capillary) endothelia C4d deposition occurs(125), often accompanied by portal stromal C4d, which is reportedly characteristic of acute ABO-I AMR, during the first several weeks(106).

In untreated recipients with high titers, progressive patchy geographic hemorrhagic infarction of the organ ensues and those who survive the initial episode can later develop biliary strictures caused by ischemic cholangiopathy (20, 126, 127). In recipients harboring low-titer isoagglutinins, endothelial cell C4d positivity in ABO-incompatible grafts does not necessarily correlate with other features of acute AMR (128).

ABO-compatible allografts: Post-reperfusion biopsies from highly sensitized (high titer/high MFI, often multiple, anti-HLA antibodies) ABO-compatible allografts often show platelet aggregates in portal and/or central veins (107, 129), which can be accompanied by diffuse portal microvasculature C4d staining (113, 115). Portal microvascular endothelial hypertrophy and cytoplasmic eosinophilia, occasionally resulting in "hobnailing", often appear within days to weeks after OLTx in those who develop acute AMR early after transplantation(107, 115, 116). Other features include microvascular dilatation and sludging and/or margination consisting of macrophages, eosinophils, lymphocytes, and neutrophils and involving portal vein branches, inlet venules, portal capillaries, peribiliary plexus capillaries, occasionally extending into the sinusoids and central veins (Figures 2 and 3).

The microvascular pathology, described above, is usually accompanied by a variable ductular reaction, portal/periportal edema, spotty acidophilic necrosis of hepatocytes, centrilobular hepatocellular swelling and hepatocanalicular cholestasis(107, 115, 116, 130); focal bile duct necrosis; and arterial changes strongly suggestive of arterial vasospasm(107). Superimposed TCMR is also very common (107, 115, 116, 131-133). When mixed AMR and TCMR exist standard criteria should be used to grade each component and a diagnosis of mixed AMR and TCMR should be rendered. Significant AMR can eventually lead to biliary stricture development(107, 134, 135), as in ABO-I grafts. Portal and central sclerotic venous lesions, similar to veno-occlusive disease, can develop and persist chronically, as discussed below in chronic AMR. Component lesion scoring for acute liver AMR are shown in Table 4 and criteria for the diagnosis of acute liver allograft AMR are shown in Table 5. Inflammatory (lymphocytic intimal inflammation)/necrotizing arteritis is rare, but should be considered diagnostic of acute AMR when seen in conjunction with diffuse C4d deposits and DSA, as in kidney allografts(2).

Some histopathological changes resemble preservation/reperfusion injury and obstructive cholangiopathy, but microvascular dilatation, microvascular endothelial cell enlargement/hypertrophy, and cytoplasmic eosinophilia and "microvasculitis", especially when involving central veins, distinguish acute AMR from these other complications (21, 76, 115, 116, 136-138). Regardless, we recommend stringent diagnostic criteria to establish an AMR diagnosis with certainty(112, 115, 116, 136, 137, 139, 140) (Table 5). The histopathological manifestations of acute AMR are

the same for preformed and de novo DSA formation. However, the latter tends to be less severe or obvious and therefore, can be more difficult to recognize >6 months after liver transplantation, in contrast to kidney and heart allografts. Possible explanations for these inter-organ differences include hepatic resistance mechanisms, discussed above.

CHRONIC ANTIBODY-MEDIATED INJURY

Chronic AMR General Considerations

Antibody characteristics: Late onset acute AMR, and mixed AMR and TCMR have been reported in suboptimally immunosuppressed with persistent, often *de novo,* DSA+ individuals (121). Putative chronic liver AMR occurs primarily in a currently unknown percentage of the ~8 - 15% of liver allograft recipients that keep or develop *de novo* DSA (121, 141) directed at HLA class II, especially DQ antigens (121, 141). Risk factors for de novo DSA include cyclosporine versus tacrolimus use, low levels of immunosuppression, young age, low Model for End-Stage Liver Disease (MELD) score (141), and previous transplants (121). Multivariate analyses show that *de novo* DSA is associated with decreased patient and allograft survival (141) and increased fibrosis development(121). IgG3 subclass and C1q testing may help facilitate identification of preformed and de novo DSAs associated with the highest risk of allograft damage (44,
142-144). However, pathophysiologically linking the antibodies to the tissue pathology has been more difficult for chronic than acute liver allograft AMR(21, 22). In addition, it should be noted that not all patients who develop de novo DSA, such as operationally tolerant human liver allograft recipients, experience associated tissue pathology over a period of up to 7 years (144, 145).

Similar difficulties have been encountered in studying and diagnosing chronic AMR in renal allografts(146). Regardless, more advanced fibrosis and architectural distortion and decreased graft survival data in DSA+ liver allograft recipients strongly suggest that antibodies negatively impact the allograft in a subset (22, 34, 109, 142, 143, 147, 148), but not all(144), persistently DSA+ liver recipients. Smith and Colvin(146) summarized similar problems encountered in kidney transplantation (21, 22): "Alloantibodies clearly cause acute antibody mediated rejection, and all available evidence supports their pathogenic etiology in the development of chronic alloantibody mediated rejection (CAMR). But the slow evolution of this disease, the on-going immunosuppression, the variations in titer of alloantibodies, and variation in antigenic targets all complicate identifying which dynamic factors are most important clinically and pathologically."

An expert *renal* allograft pathology panel(149) offered the following evidence supporting a pathogenic role for antibodies in chronic kidney injury: 1) experimental models of non-human primate renal allografts without immunosuppression progress to chronic graft injury and loss through four stages: alloantibody production, peritubular capillaries and glomeruli C4d deposition, chronic histopathological changes, and graft loss. 2) large prospective studies show circulating anti-HLA antibodies are associated with late graft failure. 3) Histological changes associated with late graft loss are found in close association with C4d deposition in peritubular capillaries and presence of anti-HLA antibodies. Criteria proposed in 2007 to diagnose chronic kidney allograft AMR included:1) histological evidence of chronic injury; 2) immunopathological evidence of antibody- mediated graft injury (C4d deposition); and 3) serum DSA(150).

Experts also agree that there is no clear-cut definition of what is meant by "chronic" (149). *"For some it simply means burned out scar formation. Others use the word in a broader sense, thinking that there are chronic changes with some kind of activity so that chronicity still has an ongoing active component (and thus, a potential need for treatment)(149)". C4d can potentially reflect recent immunological activity within weeks. Factors such as antibody class, subclass, titer, antibody avidity, variable target antigen expression, and the extent of resistance (or accommodation) likely contribute to whether acute, chronic, or some other manifestation of antibody binding occurs in a particular situation(21, 149).*" More research is clearly needed: the lack of insight into the natural history of chronic renal allograft AMR, let alone liver chronic AMR, makes the optimal therapy unknown (21, 149).

In comparison, liver allografts,: 1) lack large non-human primate data, although recent small animal models are emerging(151, 152); 2) prospective analysis of paired serum and biopsies are just now appearing in the literature(153); 3) candidate histopathological lesions found in close proximity with C4d deposits, discussed below,

have already been described(34, 44, 128, 139, 147, 154-159); and 4) "activity" might be differently defined in kidney versus liver allografts.

A major problem with the diagnosis of chronic AMR in liver allografts, however, is the lack of specific/typical clinical or biochemical features. Instead, many of the histopathological features that have been postulated to occur as a consequence of chronic AMR have been observed in protocol biopsies from liver allograft recipients (mostly pediatric) who appear to be clinically well with good graft function assessed by liver injury tests.

Chronic AMR Histopathology

Candidate histopathological lesions of chronic liver allograft AMR that have been associated, albeit not necessarily causally, are emerging primarily from: 1) long-term follow-up of pediatric liver allograft recipients(34, 44, 58, 147, 157, 158, 160); 2) suboptimally immunosuppressed recipients(22, 44, 147, 160); 3) immunosuppression weaning studies(147, 161, 162); and 4) from centers that conduct protocol simultaneous serum and biopsy samplings(22, 115, 116, 163). Pediatric populations are potentially the most informative since most original diseases do not recur following transplantation and recognizing changes potentially associated with chronic AMR should be less challenging than in adults where original disease recurrence is more common. This is especially true when candidate chronic AMR lesions differ substantially from those encountered with otherwise typical TCMR, viral hepatitis, vascular or technical biliary complications.

DSA appearance has been associated with tolerance loss in kidney allografts (164). De novo DSA often develops in pediatric OLTx recipients weaned from immunosuppression(144, 147) and in patients with chronic suboptimal immunosuppression(21, 58, 147, 164). Reports of protocol follow-up biopsies in patients after sustained lowering or withdrawal of immunosuppression (IS) are limited (5, 10, 165, 166). As mentioned above, it is clear that not all patients that develop DSA after weaning experience significant liver inflammation, TCMR, fibrosis, architectural deterioration, or changes in sinusoidal endothelial (CD34- to CD34+) or stellate cell phenotype (SMA– to SMA+) within five years(144). Nevertheless, some study endpoints consider de novo DSA development a failure, regardless of the liver function or histopathology.

A spectrum of liver allograft injury (low-grade portal, periportal, and perivenular inflammation, non-inflammatory fibrosis, biliary strictures, nodular regenerative hyperplasia, etc.), and obliterative arteriopathy is suspected in chronic AMR(21, 22, 103). Some of these lesions, such as biliary strictures(107, 134, 135) or sclerotic venous lesions might be the result of, or superimposed upon, residual damage from acute AMR and/or TCMR, discussed above. Histopathological lesions currently more strongly associated with persistent post-transplant DSA include portal and perivenular mononuclear inflammation with low-grade interface necro-inflammatory activity and portal/periportal, sinusoidal and perivenular fibrosis (Table 6).

The above putative chronic AMR lesions have also been associated with microvascular endothelial C4d deposition in most, but not all studies, whereas prominent microvascular inflammation appear to be less common than in acute liver allograft AMR(21, 34, 50, 76, 103, 128, 147, 148, 167, 168). This might be related to lower antibody production related to gradual apoptosis-mediated deletion of activated B cells via a PD-L1-mediated mechanism(169) or to other liver-related adaptive mechanisms.

Except for obliterative arteriopathy, most of these candidate lesions can also be caused by technical complications (5, 10, 55). Theoretically, DSA might accentuate or worsen the histopathological lesions of co-existent disorders, such as recurrent HCV and TCMR, via upregulate allograft microvascular and other cell HLA II (21, 22, 103). In addition to low-grade microvascular inflammation and destruction, potential pathogenic mechanisms linking DSA to tissue inflammation and fibrosis include non-microvascular antibody-dependent cellular cytotoxicity (ADCC) mechanisms, direct phenotypic modulation/activation of liver endothelial cells, stellate cells and portal myofibroblasts, and an association with TCMR. Routine histopathological, serological, immunohistochemical, and clinical criteria needed to establish a diagnosis of "possible" and "probable" chronic AMR are shown in Table 7. Similar to acute AMR, stringent criteria are proposed to establish a chronic AMR diagnosis to avoid over-diagnosis until the spectrum of potential morphological manifestations are more thoroughly appreciated. When mixed AMR and TCMR exist standard criteria should be used to grade each component and a diagnosis of mixed AMR and TCMR should be

rendered.

Specimen Adequacy, C4d Staining Methods and Interpretation

Guidelines for liver biopsy adequacy, as defined by American Association for the Study of Liver Disease AASLD(170)/Banff Working Group(5) includes 2 passes with a 16 gauge needle for adequate assessment of fibrosis. Short needle biopsies (< 20 mm) are subject to sampling errors and systematic underestimation of fibrosis(171). Biopsies containing < 11 portal tracts might not be representative (reviewed in (170)).

Linear to granular microvascular endothelial cell staining for complement 4d (C4d), which persists for several weeks, is accepted as evidence of complement activation within the tissue at the deposition site(15, 149, 172). C4d staining has improved the diagnostic accuracy of liver allograft AMR (140, 173), but C4d deposition does not necessarily trigger downstream effector mechanisms and tissue damage(14, 146, 149). As with other organ allografts, immunofluorescence staining of frozen tissue for C4d is generally considered to be more sensitive than immunoperoxidase staining of formalin-fixed, paraffin-embedded (FFPE) tissue after antigen retrieval (174-179). Most centers rely on mouse and rabbit monoclonal anti-C4d primary antibodies for frozen tissue. Therefore, if acute or chronic AMR is suspected frozen tissue should be saved for immunofluorescence (IF) C4d staining. Various combinations of IgG, IgM, C3, and C4 can be diffusely detected in frozen sections along the sinusoids and in peri-hilar arteries, portal veins, and the peribiliary plexus in frozen tissue from livers with acute AMR (60, 107, 136), but are neither stable nor reliably present (60, 107, 136).

Unfortunately, most centers rely on FFPE as a reasonable, albeit less sensitive, alternative to IF on frozen tissue. C4d staining techniques on FFPE affect sensitivity: pressure cooker antigen retrieval yields more sensitive results, but background can emerge leading to interpretational problems (106, 138, 173, 180-185). FFPE sections are more often stained with rabbit polyclonal and/or rabbit monoclonal anti-C4d antibodies; a cocktail of monoclonal and polyclonal antibodies appears to improve sensitivity.

An unpublished FFPE tissue microarray C4d staining study (D. Neil, personal communication) showed: a) several “best” methods use different primary antibodies, with antigen retrieval performed at both high and low pH suggesting that there is no single best antibody or pH of antigen retrieval; and b) “best C4d staining methods” in liver showed variable staining in kidney and heart AMR. Therefore, a liver tissue positive control is ideal, but might not be available, so kidney or heart tissue is an acceptable substitution. Regardless, each laboratory should validate its anti-C4d antibody reactions against positive and negative controls to monitor the effect of fixation times, processing techniques, automation and selection of antibodies.

Normal liver allograft biopsies are usually negative for endothelial cell C4d staining, but background/nonspecific C4d labelling can be seen in: arterial elastic lamina; portal and perivenular elastic fibers; necrotic and steatotic hepatocytes, and areas of sinusoidal fibrosis. “True” linear to granular endothelial cell staining of portal veins, portal capillaries, sinusoids, central veins, and arterial endothelium, lymphoid nodules, and periductal and portal stromal C4d staining has been described in *native pediatric livers* with hepatitis B (HBV) and C (HCV), and AIH(186) and in allografts when other insults are thought to be the primary cause of allograft dysfunction (e.g. biliary obstruction(173), recurrent HBV(180) or HCV(181), and plasma cell hepatitis (*de novo* AIH))(50). However, these deposits are reportedly less widespread and intense than those associated with severe TCMR or acute AMR(76, 113, 138, 140, 187, 188). Moreover, recipients with non- rejection causes of allograft dysfunction (e.g. recurrent HCV or non-alcoholic fatty liver disease (NAFLD)) are not protected from developing DSA and C4d tissue deposition. In fact, DSA and C4d deposits might be more common in these circumstances because of induced upregulation of HLA target antigens(21, 153, 163).

C4d staining also might vary and reflect target antigen distribution. For example, portal venous and capillary, arterial, and sinusoidal endothelial C4d staining has been significantly associated with complement-dependent cytotoxicity (CDC)+ and DSA+ recipients more often than their negative controls(183); in those with isolated AMR(136,
185); and associated with macrophage and plasma cell infiltrates(138), micro- vasculitis(107, 116), and TCMR (106, 112, 138, 139, 173, 180-185). In some studies, C4d deposits were directly proportional to Banff TCMR grade, suggesting that “severe” episodes actually represent combined TCMR and AMR(106, 138, 173, 180-185). Portal

microvascular (portal veins and capillaries) and sinusoidal endothelial cell C4d staining appears to be most specific for *acute AMR(115, 116, 128, 136)*, whereas portal C4d "stromal" staining seems to be more strongly associated with ABO-incompatible acute AMR(106), TCMR(183) and CR(139, 167). C4d deposits are often less intense in putative chronic AMR in FFPE sections(153), and can occasionally be minimal to absent similar to renal allografts(146, 189, 190), although the prevalence of this unknown.

Since HLA class II target antigen expression can potentially affect antibody binding and C4d fixation, the pattern of C4d staining can be contextual. For example, TCMR manifest primarily as central perivenulitis can locally upregulate HLA class II leading to preferential C4d deposition in central vein and perivenular sinusoidal endothelium. Recommendations for C4d scoring are shown in Table 4. HLA class II staining might also be helpful to delineate DSA target antigen distribution.

In liver allografts, IF can be more difficult to interpret than FFPE staining because of difficulties with recognizing the underlying architecture and background/non-specific staining in elastic fibers and collagen bundles. True linear sinusoidal C4d endothelial cell staining is more common in frozen samples, but sinusoidal fibrosis can result in non- specific uptake that is mistakenly interpreted as "diffuse" sinusoidal labelling. In addition, saving small frozen tissue fragments for IF staining is not a component of inflammatory native liver pathology and special arrangements have to be made that often add personnel costs. However, an effort to save even a small portion of frozen tissue is encouraged.

ACUTE AND CHRONIC AMR TREATMENT

ABO-incompatible AMR is best prevented. Isoagglutinin titers are tested pre- transplant and therapy with total plasma exchange and usually rituximab with or without other modalities (e.g. intra-venous immunoglobulin (IVIg), cyclophosphamide, local infusion therapy and splenectomy) is employed to achieve a pre-transplant titer ≤1:8 (1). Following transplantation, isoagglutinin titers should be monitored prospectively and therapy instituted if they increase to >1:8 (191).

ABO-compatible AMR therapy has been limited to acute AMR in single center retrospective case reports [1-9 patients per report; reviewed(192)]. Further limiting features include the prior lack of severity differentiation, the variation in timing of diagnosis relative to onset of disease, variable treatment algorithms, short-term biochemical follow-up usually devoid of liver pathology, absence of long-term follow-up, and inevitable publication bias.

TCMR early after transplant in the presence of preformed DSA and the absence of diagnostic features of acute AMR requires the standard approach to TCMR. This occurs more commonly in the presence of preformed class II DSA, likely because of Fc biding receptors present on some but not all alloantibodies (86, 193, 194). However, if clear features of acute AMR are present before any therapy, or if steroid resistant rejection is diagnosed, one must test for DSA in serum, stain for C4d in tissue, and rule out other causes of similar injury to determine the patient fulfills the diagnostic criteria for acute AMR (Table 5). The literature is devoid of cases of mild acute AMR, as these likely have responded to our standard approach to TCMR with a steroid recycle with or without steroid-resistant rejection therapy (195). However, those with moderate to severe AMR necessitate early intervention usually with plasmapheresis and IVIg with or without B-cell directed therapy depending on the severity and timing post-transplant of AMR and stability of the patient(130, 131, 133, 196-201).

Given the infrequency of acute AMR, the most important therapeutic target will inevitably be chronic AMR, although no published studies exist to date in this area. Drawing from chronic rejection, it is clear that compliance with a tacrolimus (as opposed to cyclosporine) based immunosuppression regimen is critical to prevention (in the first year after transplant) and possibly treatment (202). However, treatment of both acute and chronic AMR must commence in prospective multicenter studies, utilizing strict diagnostic criteria and unified protocols (192)that include severity grading, although prevention is always preferable(202).

BIOPSY FINDINGS IN IMMUNOSUPPRESSION MANAGEMENT

Some pre-weaning biopsy findings associated with unsuccessful immunosuppression weaning, such as microvascular C4d deposits(145), portal lymphocytic inflammation (145, 203) and more lobular CD3+ and CD8+

lymphocytes(203) overlap with histopathological changes linked to chronic AMR. Indeed, several recent protocol biopsy studies from large cohorts of stable long-surviving pediatric(204) and adult(153) liver allograft recipients show strong associations between portal and perivenular inflammation with necro-inflammatory activity and fibrosis in patients with class II DSA. Conversely, an absence of co-existent pathology before weaning might contribute to allograft stability after weaning even when DSA is present possibly because of less HLA II expression (144, 145, 153).

European multicenter adult trials(166, 205) failed to show a DSA-related predisposition to rejection after weaning or an association between DSA and any particular pattern of injury before or after weaning. However, these studies were limited by: 1) suboptimal DSA evaluation, based on ELISA screening, that might have missed class II DSAs; and 2) allowance of HCV fibrosis progression pre- and post-weaning.

Japanese immunosuppression weaning trials, conducted primarily in pediatric recipients, showed increased periportal and perivenular fibrosis after weaning, with or without co-existent lymphocytic inflammation(147, 161, 168), which were directly or indirectly attributed to IS minimization(147, 161, 168) and development of HLA class II DSA. Endothelial and stromal C4d staining, and CD20+ perivenular infiltrates(147), similar to the iWITH screening biopsies cited above(204), were described. Peribiliary plexus capillary and sinusoidal endothelial cell HLA-DR upregulation was spatially linked with nearby inflammation, which was most prominent in patients with co-existent TCMR with or without perivenular fibrosis(34). Re-institution or increasing immunosuppression decreased C4d deposits and stabilized or reversed perivenular fibrosis(168). It is tempting to speculate, therefore, that the lymphocytic portal and perivenular inflammation tissue C4d deposits in DSA+ recipients might be related to each other and represent subclinical combined chronic AMR/TCMR that manifests biochemically after IS lowering(5, 82).

Because of the above observations, we recommend that restrictive criteria should met before immunosuppression minimization, especially with respect to immunological "activity" within the biopsy manifest as inflammation with tissue damage (see Tables 8 and 9). However, a recent study showed increased portal regulatory T cell infiltrates in recipients one and three years after immunosuppression withdrawal; these infiltrates decreased after longer follow-up and were not associated with progressive fibrosis(206). Relaxed fibrosis criteria are likely appropriate for patients after achieving sustained virological response to HCV therapy, as the major cause of fibrosis has been eliminated.

FUTURE DIRECTIONS

Acute AMR can and must be reliably recognized early in its course. Routine typing of donor and recipient will help facilitate diagnosis of this early rare event and provide baseline data needed for DSA determinations. Retrospective typing in cases that develop suspicious injury patterns in post-transplant biopsies can be carried out if donor and recipients cells and/or nucleic acids are stored. Protocolized monitoring for DSA may be helpful in standard immunosuppression management. Indeed, work is needed to better define: 1) the timing and types of tissue injury or alterations (e.g. portal venopathy, portal capillary destruction, patterns of fibrosis, and sinusoidal endothelial cell as well as Kupffer cell and stellate cell phenotypic changes) associated with HLA and other non-HLA antibodies (36, 58, 207); 2) antibody characteristics (C1q, MFI, titer, IgG subclass, etc.) associated with tissue injury; 3) relative contribution of AMR to "mixed" TCMR and AMR episodes and whether different and/or more aggressive immunosuppression therapy is needed; 4) cost-effective DSA and tissue screening protocols (including routine C4d staining and possibly other immunohistochemistry); 5) incorporation of "molecular signatures"(208) into biopsy analysis, including mRNA, miRNA, and other "-omics" that might help uncover molecular mechanisms linking antibody binding to tissue changes that can be further pursued, in vitro, and, in vivo; and 6) ultimately how mechanistically different therapeutic interactions affect the different histopathological findings in acute and chronic AMR.

Table 1. Typical T CELL-MEDIATED REJECTION

Grading Criteria (Global Assessment):

- **Indeterminate**: Portal and/or perivenular inflammatory infiltrate that is related to an allo-reaction, but shows insufficient tissue damage to meet criteria for a diagnosis of mild acute rejection (see reference below).
- **Mild**: Rejection-type infiltrate in a minority of the triads or perivenular areas, that is generally mild, and mostly confined within the portal spaces for portal-based rejection and an absence of confluent necrosis/hepatocyte dropout for those presenting with isolated perivenular infiltrates.
- **Moderate**: Rejection-type infiltrate, expanding most or all of portal tracts and/or perivenular areas with confluent necrosis/hepatocyte dropout limited to a minority of perivenular areas.
- **Severe**: As above for moderate, with spillover into periportal areas and/or moderate to severe perivenular inflammation that extends into the hepatic parenchyma and is associated with perivenular hepatocyte necrosis involving a majority of perivenular areas.

Quantitative Scoring (Rejection Activity Index (RAI)):
Portal Inflammation:

1) Mostly lymphocytic inflammation involving, but not noticeably expanding, a minority of the triads.
2) Expansion of most or all of the triads, by a mixed infiltrate containing lymphocytes with occasional blasts, neutrophils and eosinophils. If eosinophils are conspicuous and accompanied by edema and microvascular endothelial cell hypertrophy is prominent, acute AMR should be considered.
3) Marked expansion of most or all of the triads by a mixed infiltrate containing blasts and eosinophils with inflammatory spill over into the periportal parenchyma

Bile Duct Inflammation Damage:

1) A minority of the ducts are cuffed and infiltrated by inflammatory cells and show only mild reactive changes such as increased nuclear:cytoplasmic ratio of the epithelial cells.
2) Most or all of the ducts infiltrated by inflammatory cells. More than an occasional duct shows degenerative changes such as nuclear pleomorphism, disordered polarity and cytoplasmic vacuolization of the epithelium.
3) As above for 2, with most or all of the ducts showing degenerative changes or focal luminal disruption

Venous Endothelial Inflammation:

1) Subendothelial lymphocytic infiltration involving some, but not a majority of the portal and/or hepatic venules
2) Subendothelial infiltration involving most or all of the portal and/or hepatic venules with/out confluent hepatocyte necrosis/dropout involving a minority of perivenular regions.
3) As above for 2, with moderate or severe perivenular inflammation that extends into the perivenular parenchyma and is associated with perivenular hepatocyte necrosis involving a majority of perivenular regions.

Table 2A. Typical Chronic Rejection Evaluation

Structure	Early Chronic Rejection (at least two findings should be present)	Late Chronic Rejection (at least two findings should be
Small Bile Ducts (<60 µm)	Senescence-related changes involving a majority of ducts (see text); bile duct loss <50% of portal tracts	Loss in >=50% of portal tracts; degenerative changes in remaining bile ducts
Portal tract hepatic arterioles	Occasional loss involving <25% of portal tracts	Loss involving >25% of portal tracts
Terminal hepatic venules and zone 3 hepatocytes	Perivenular mononuclear inflammation; lytic zone 3 necrosis and inflammation; and mild perivenular fibrosis (see below)	Variable inflammation; focal obliteration; moderate to severe (bridging) fibrosis (see below).*
Large peri-hilar hepatic artery branches	Intimal inflammation, focal foam cell deposition without luminal	Luminal narrowing by intimal foam cells; fibrointimal hyperplasia
Large perihilar bile ducts	Inflammation damage and focal foam cell deposition	Mural fibrosis
Other	So-called "transition" hepatitis with spotty necrosis of hepatocytes	Sinusoidal foam cell accumulation; cholestasis

*Chronic AMR might be contributing to the development of perivenular fibrosis; C4d stains and DSA determinations should be considered.

Suggested Fibrosis Scoring(35):

Table 2B Adapted from Venturi et al(35).

Portal/Periportal: 0 (none) – 3 (portal-to-portal or portal-to-central bridging)
Subsinusoidal: 0 (none) – 3 (thick; marked and diffuse)
Perivenular: 0 (none) – 3 (central-to-central or central-to-portal bridging)

Table 3. Criteria for the diagnosis of plasma cell-rich TCMR*/**

Must fulfil criteria 1 and 3; criteria 2 is desirable, but not absolutely required:

1) Portal and/or perivenular plasma cell-rich (estimated >30%) infiltrates with easily recognizable periportal/interface and/or perivenular necro-inflammatory activity usually involving a majority of portal tracts and/or central veins. Most of these cases are graded at least "moderate" with a total RAI score ≥ 5 because "V score" is usually "3" because of aggressive perivenular activity, whereas "Portal Inflammation" score is usually ≥ 2.
2) Lymphocytic cholangitis is usually present and a desirable feature, but not absolutely required (inflammatory bile duct damage might be a relatively minor component, but Banff component score for bile duct injury is usually ≥ 1).
3) Original disease other than autoimmune hepatitis.

*C4d stains are recommended on all biopsies diagnosed as plasma cell-rich rejection; IgG and IgG4 stains might also be considered to better understand the underlying pathophysiology in some recipients.

** Other contributory, but non-essential features include antibodies to GSTT1 in null recipients of GSTT1-positive donor livers and the de novo appearance of donor-specific HLA antibodies (DSA).

Table 4. Component lesion scoring for acute AMR:

Component lesion scoring for acute AMR:

C4d-(immune)-score (formalin-fixed, paraffin-embedded*/**):

0) No C4d deposition in portal microvasculature
1) Minimal (<10% portal tracts) C4d deposition in > 50% of the circumference of portal microvascular endothelia (portal veins and capillaries)
2) Focal (10-50% portal tracts) C4d deposition in > 50% of the circumference of portal microvascular endothelia (portal veins and capillaries) – usually without extension into periportal sinusoids
3) Diffuse (>50% portal tracts) C4d deposition in in > 50% of the circumference of portal microvascular endothelia (portal veins and capillaries) - often with extension into inlet venules or periportal sinusoids

* Formalin-fixed, paraffin-embedded tissues are known to show weaker staining than fresh-frozen tissues, but interpretation of frozen tissues can be more difficult because of background/non-specific staining and poor preservation of morphology. Sinusoidal staining should be localized to sinusoidal endothelial cells; false positive staining of connective tissue fibers can occur in livers with subsinusoidal fibrosis.
** Ideally the C4d positive control should be a liver allograft, but peritubular capillary staining of a kidney allograft is an acceptable alternative h-(histopathology)-score*/**/#

1) portal microvascular endothelial cell enlargement (portal veins, capillaries, inlet venules) involving a majority of portal tracts with sparse microvasculitis defined as 3 – 4 marginated and/or intra-luminal monocytes, neutrophils, or eosinophils in the maximally involved capillary with generally mild dilation (Figure 1).
2) monocytic, eosinophilic or neutrophilic micro-vasculitis/capillaritis, defined at least 5 – 10 leukocytes marginated and/or intra-luminal in the maximally involved capillary prominent portal and/or sinusoidal microvascular endothelial cell enlargement involving a majority of portal tracts or sinusoids, with variable, but noticeable portal capillary and inlet venule dilatation and variable portal edema (Figure 2).
3) As above, with marked capillary dilatation, marked microvascular inflammation (10 or more marginated and/or intra-luminal leukocytes in the most severely affected vessels) at least focal microvascular disruption with fibrin deposition, and extravasation of red blood cells into the portal stroma and/or space of Disse (subsinusoidal space) (Figure 3).

* Special stains that help identify capillaries, such as CD31, CD34, and/or PAS are often needed to help identify involved portal-based capillaries.
**Other features commonly seen, but not necessarily associated with severity include ductular reaction and cholestasis.
Fibrin deposition and RBC sludging occurs earlier and is more common and prominent in ABO-incompatible allografts.

Table 5. Criteria for establishing the diagnosis of acute AMR in liver allografts.

Definite for acute/active* AMR (all four criteria required):

1. Histopathological pattern of injury consistent with acute AMR, usually including:

a. portal microvascular endothelial cell hypertrophy, portal capillary and inlet venule dilatation, monocytic, eosinophilic, and neutrophilic portal microvasculitis, portal edema, ductular reaction; cholestasis is usually present, but variable; edema and periportal hepatocyte necrosis are more common/prominent in ABO-incompatible allografts(60, 105, 106) variable active lymphocytic and/or necrotizing arteritis

2. Positive serum DSA

3. Diffuse (C4d score = 3) microvascular C4d deposition* on frozen or formalin- fixed, paraffin-embedded tissue in ABO-compatible tissues or portal stromal C4d deposition in ABO-incompatible allografts.

4. Reasonable exclusion of other insults that might cause a similar pattern of injury (see text). Most cases will score (C4d-score: 3 + h-score = 5 or 6; see below).

* optimized C4d staining including positive control is critical for proper evaluation

Suspicious for AMR (both criteria required):

1) DSA is positive (see definitions).

Non zero h score with: C4d-score + h-score of 3 or 4.

Indeterminate for AMR (requires 1 + 2 and 3 or 4):

1) C4d-score + h-score is greater than or equal to 2.

2) DSA not available, equivocal, or negative

3) C4d staining not available, equivocal, or negative

4) Co-existing insult might be contributing to the injury.

* Thrombocytopenia, low serum complement levels, persistence of DSA early after transplantation, and elevated liver injury tests are usually present, but might not be prominent in mild cases.

Table 6. Histopathological Changes with post-transplant DSA and AT1R antibodies.

Study	No. Pt	Age Surv(mo.)	Association between DSA	Histopathological Findings Associated with DSA
Yamada et al(34)	28	Pediatric > 12 mo.	Protocol and indication	↑ Portal and perivenular C4d associated with perivenular fibrosis ↑ Perivenular CD3+, CD20+ cells, and ↑ DR expression associated with perivenular fibrosis; ***DSA not assayed in this study***.
Miyagawa-Hayashino (147)	79	Pediatric Median 11 yrs	Protocol	↑ bridging fibrosis or cirrhosis; fibrosis likely to be perivenular; higher frequencies of diffuse/focal endothelial C4d staining; mild/ indeterminate T cell-mediated rejection; 4 DSA- vs 0 DSA+ patients off immunosuppression.
Ohe et al (58)	81	Pediatric Median 16.3 years	Protocol LBxs	↑ fibrosis with anti-class II DSA. All patients with both high-level DSA-DRB1 and high-level anti- Angiotensin II receptor type I (AT1R) Ab showed advanced fibrosis. ***C4d staining not conducted***
Del Bello et al (121)	267	Adults 6 – 220 mo.	Indication LBx	↑Fibrosis, NOS 24% of patients with de novo DSA developed acute AMR: lymphocytic portal inflammation, lymphocytic cholangitis, PV C4d+, endotheliitis
Salah (128)	143	Pediatric and adult Generally >	Indication LBxs	C4d associated with anti-DR DSA, but not all DSA C4d associated with bridging fibrosis
Iacob et al (148)	174	Adults 67 mo.	Protocol: 1 + 3 yrs and indication	↑Fibrosis, NOS DSA strongly correlated with portal capillary C4d (IPEX) Portal capillary C4d (IPEX) positivity significantly associated with more frequent and earlier graft failure
Grabhorn et al(157)	43	Pediatric > 5 yrs in well patients	Protocol LBxs from well patients vs indication LBxs from recipients with	DSA present more commonly in recipients with severe chronic rejection, but no specific pathological findings attributed to chronic AMR. ***C4d staining not conducted***
Wozniak et al(44)	50	Pediatric ~12 yrs.	Indication LBXs Compared 3 groups: 1) Non-tolerant 2) de novo AIH 3) stable	DSA associated with late immune activity (T cell-mediated rejection, de novo AIH, and chronic rejection) ***C4d staining not conducted***
Markiewicz-Kijewska(158)	33	Pediatric 99 d – 11 yrs.	Indication LBxs	***Possible*** association between DSA and liver fibrosis. Recognized AMR by diffuse C4d and CD20+ or CD138+ predominant infiltrates
Feng et al(204)	157	Pediatric > 4 years	Protocol	Deceased donor and Class II DSA predicted assignment to patients with interface activity with/out fibrosis whereas only recipient age predicted assignment patients with fibrosis,
O'Leary et al (153)	90	Adult > 5 yrs	Protocol	↑ portal inflammation and interface activity ↑ lobular/perivenular inflammation and typical TCMR ↑ portal venopathy, portal "collagenization" and portal/periportal and sinusoidal fibrosis DSA strongly correlated with portal capillary and portal stromal C4d (IPEX)

Table 7. Criteria for chronic active liver allograft AMR.

Probable chronic active AMR (all four criteria are required):

1) Histopathological pattern of injury consistent with chronic AMR: both required:

a. Otherwise unexplained and at least mild mononuclear portal and/or perivenular inflammation with interface and/or perivenular necro- inflammatory activity (Figures 4 and 5)*.

b. At least moderate portal/periportal, sinusoidal and/or perivenular fibrosis**.

2) Recent (for example, measured within 3 months of biopsy)circulating HLA DSA in serum samples;

3) At least focal C4d-positive (>10% portal tracts) **(Figure 5)**.

4) Reasonable exclusion of other insults that might cause a similar pattern of injury (see text).

Possible chronic active AMR:

1) As above, but C4d staining is minimal or absent

* it is difficult, at this time, to determine whether the mononuclear infiltrates are related to AMR (e.g. ADCC with capillaritis) or TCMR (mostly T effectors cells) or mixed AMR and TCMR. More research is needed on this topic.
** CD34 and SMA **stains might be considered to study sinusoidal capillarization and stellate cell activation.**

Table 8. Baseline or Pre-weaning biopsy findings conducive to MINIMIZATON OF IS*

Compartment	Findings
Portal inflammation and interface activity	Preferably absent, but minimal to focal mild portal mononuclear inflammation may be present. Interface necro-inflammatory activity is absent or equivocal/minimal and, if present, involves a minority of portal tracts.
Centrizonal/Perivenular inflammation**	Current Recommended Criteria: Negative for perivenular inflammation *Banff 2012 Criteria: Preferably absent, but minimal/mild perivenular mononuclear inflammation around a minority of central veins without hepatocyte necrosis without endothelitis*.
Bile duct changes	Absence of lymphocytic bile duct damage, ductopenia and biliary epithelial senescence changes, unless there is an alternative, non-immunologic explanation (e.g. biliary strictures).
Fibrosis*	Fibrosis, if present, should be mild overall and not more than rare portal-to-portal bridging. Perivenular fibrosis should not be more than mild according to Banff Criteria. Patients who achieved sustained virologic response to HCV treatment might have more substantial fibrosis and architectural distortion.
Arteries	Negative for *isolated "v" lesions (lymphocytic arteritis)**** obliterative or foam cell arteriopathy.

*Excludes patients with underlying AIH, HCV, PBC or PSC (see text). More substantial fibrosis and architectural distortion can be tolerated in patients who achieved sustained virologic response to HCV treatment. ** Modified from Banff 2012 recommendations(5) because of widespread recognition that the lesion represents a rejection reaction and has the potential to progress and cause perivenular fibrosis after weaning. *** "isolated "v" lesions (lymphocytic arteritis) was added to the Banff 2012 because of evidence of similar lesions in renal allografts leading to a suboptimal outcome even in patients maintained on immunosuppression(209).

Table 9.Follow-up biopsy findings suggesting that the patient is unlikely to benefit from minimal or absent immunosuppression; proceed only with extreme caution (see Figure 2).

Compartment	Finding(-s)
Portal inflammation and interface activity	Increased portal inflammation compared to pre-weaning biopsy especially when associated with histopathologic evidence of focally worsening or more prevalent lymphocytic bile duct damage, interface hepatitis, or appearance of venous endothelitis.
Centrizonal/Perivenular inflammation	New onset perivenular inflammation compared to pre-weaning biopsy associated with necro-inflammatory activity.
Bile duct changes	New onset biliary epithelial cell senescence changes or ductopenia where sampling problems and/or an alternative, non-immunologic explanation (e.g. biliary stricture) are reasonably excluded.
Fibrosis	Current Recommended Criteria:: Greater than 1 grade increase in fibrosis in any one compartment: (a) portal/periportal; (b) peri-sinusoidal; or (c) perivenular fibrosis; or new onset bridging fibrosis without an alternative explanation (e.g. biliary strictures) that involves more than one area and not readily explained by a sampling error. *Banff 2012 Criteria:* Increase of fibrosis over consecutive biopsies (see text) without an alternative explanation (e.g. biliary strictures). New onset or increase of perivenular fibrosis.
Arteries	**Any evidence of foam cell or obliterative arteriopathy.**

*Excludes patients with underlying AIH, HCV, PBC or PSC (see text). ** modified from Banff 2012 recommendations(5) to recognize the need to score liver allograft fibrosis according to compartments.

Figure Legends

1. Composite of early acute AMR with mild portal microvascular endothelial cell enlargement (portal veins, capillaries, inlet venules) with sparse microvasculitis (h1 score; see Table 4). A) Low magnification H&E overview. The lower right inset is shown at high magnification in "D". B) C4d stain showing diffuse portal microvascular staining in the portal perbiliary plexus and inlet venules. This would score as C4d: "3". C) High magnification of the peribiliary capillary plexus showing mild endothelial cell hypertrophy and dilatation and monocyte margination (arrows). D) High magnification of inlet venules (IV) showing mild endothelial cell hypertrophy and dilatation and monocyte margination (*). The h- score for this area would be 1-2. SV: septal venules
2. Composite of moderate acute AMR (h2 score; see Table 4) with: A) mild to moderate portal microvascular endothelial cell enlargement (portal veins, capillaries, inlet venules) with: B) diffuse C4d positivity and easily recognizable microvascular inflammation (inset). Portal lymphocytic inflammation is also seen, which likely represents a component of overlapping TCMR.
3. Composite of severe acute AMR (h3 score ; see Table 4) with: A) comparison of severe acute AMR in liver (left side) versus kidney (right side) (C4d: red; CD68: black). Note the capillary dilatation in both organs. B) High magnification of a portal tract showing dilated portal capillaries, focal interstitial hemorrhage (arrow), and marginated monocytes/macrophages (*). Higher magnification of the liver area outlined by the square in "A" is shown in "C"; h-score: "3". Higher magnification of the kidney near the arrow in "A" is shown in "D". Note the margination of black-stained monocytes/macrophages in both organs with acute AMR. E: Diffuse portal microvascular endothelial cell positivity. C4d score: "3".
4. Changes commonly associated with chronic AMR include portal and perivenular inflammation. The portal tract (PT) and central vein (CV) shown in the right panel are illustrated at higher magnification in the left panels.
5. A) C4d stain of a long-surviving OLTx recipient with a positive DSA showing portal capillary positivity. B) Trichrome stain highlights the mild to moderate portal/periportal, sinusoidal, and perivenular fibrosis**.**

REFERENCES

1. Mengel M, Sis B, Haas M, Colvin RB, Halloran PF, Racusen LC et al. Banff 2011 Meeting report: new concepts in antibody-mediated rejection. Am J Transplant 2012;12(3):563-570.
2. Haas M, Sis B, Racusen LC, Solez K, Glotz D, Colvin RB et al. Banff 2013 meeting report: inclusion of c4d-negative antibody-mediated rejection and antibody-associated arterial lesions. Am J Transplant 2014;14(2):272-283.
3. Berry GJ, Burke MM, Andersen C, Bruneval P, Fedrigo M, Fishbein MC et al. The 2013 International Society for Heart and Lung Transplantation Working Formulation for the standardization of nomenclature in the pathologic diagnosis of antibody-mediated rejection in heart transplantation. J Heart Lung Transplant 2013;32(12):1147-1162.
4. Stewart S, Fishbein MC, Snell GI, Berry GJ, Boehler A, Burke MM et al. Revision of the 1996 working formulation for the standardization of nomenclature in the diagnosis of lung rejection. J Heart Lung Transplant 2007;26(12):1229-1242.
5. Pathology BWGoLA. Importance of liver biopsy findings in immunosuppression management: biopsy monitoring and working criteria for patients with operational tolerance. Liver Transpl 2012;18(10):1154-1170.
6. anonymous. Banff schema for grading liver allograft rejection: an international consensus document. Hepatology 1997;25(3):658-663.
7. Demetris A, Adams D, Bellamy C, Blakolmer K, Clouston A, Dhillon AP et al. Update of the International Banff Schema for Liver Allograft Rejection: working recommendations for the histopathologic staging and reporting of chronic rejection. An International Panel. Hepatology 2000;31(3):792-799.
8. Drachenberg CB, Odorico J, Demetris AJ, Arend L, Bajema IM, Bruijn JA et al. Banff schema for grading pancreas allograft rejection: working proposal by a multi-disciplinary international consensus panel. American journal of transplantation : official journal of the American Society of Transplantation and the American Society of Transplant Surgeons 2008;8(6):1237-1249.
9. Sánchez-Fueyo A, Strom TB. Immunologic basis of graft rejection and tolerance following transplantation of liver or other solid organs. Gastroenterology 2011;140(1):51-64.
10. Demetris AJ, Adeyi O, Bellamy CO, Clouston A, Charlotte F, Czaja A et al. Liver biopsy interpretation for causes of late liver allograft dysfunction. Hepatology 2006;44(2):489-501.
11. Evans HM, Kelly DA, McKiernan PJ, Hubscher S. Progressive histological damage in liver allografts following pediatric liver transplantation. Hepatology 2006;43(5):1109-1117.
12. Li X, Sun Q, Zhang M, Xie K, Chen J, Liu Z. Capillary dilation and rarefaction are correlated with intracapillary inflammation in antibody-mediated rejection. J Immunol Res 2014;2014:582902.
13. Escaned J, Flores A, Garcia-Pavia P, Segovia J, Jimenez J, Aragoncillo P et al. Assessment of microcirculatory remodeling with intracoronary flow velocity and pressure measurements: validation with endomyocardial sampling in cardiac allografts. Circulation 2009;120(16):1561-1568.
14. Drachenberg CB, Papadimitriou JC. Endothelial injury in renal antibody-mediated allograft rejection: a schematic view based on pathogenesis. Transplantation 2013;95(9):1073-1083.
15. Valenzuela NM, McNamara JT, Reed EF. Antibody-mediated graft injury: complement-dependent and complement-independent mechanisms. Curr Opin Organ Transplant 2014;19(1):33-40.
16. Valenzuela NM, Reed EF. Antibodies in transplantation: the effects of HLA and non-HLA antibody binding and mechanisms of injury. Methods Mol Biol 2013;1034:41-70.
17. Djamali A, Kaufman DB, Ellis TM, Zhong W, Matas A, Samaniego M. Diagnosis and management of antibody-mediated rejection: current status and novel approaches. Am J Transplant 2014;14(2):255-271.
18. Farkash EA, Colvin RB. Diagnostic challenges in chronic antibody-mediated rejection. Nature reviews Nephrology 2012;8(5):255-257.
19. de Kort H, Roufosse C, Bajema IM, Drachenberg CB. Pancreas transplantation, antibodies and rejection: where do we stand? Curr Opin Organ Transplant 2013;18(3):337-344.
20. Demetris AJ, Murase N, Nakamura K, Iwaki Y, Yagihashi A, Valdivia L et al. Immunopathology of antibodies as effectors of orthotopic liver allograft rejection. [Review]. Seminars in Liver Disease 1992;12(1):51-59.
21. Demetris AJ, Zeevi A, O'Leary JG. ABO-compatible liver allograft antibody-mediated rejection: an update. Curr Opin Organ Transplant 2015;20(3):314-324.
22. O'Leary JG, Demetris AJ, Friedman LS, Gebel HM, Halloran PF, Kirk AD et al. The role of donor- specific HLA alloantibodies in liver transplantation. Am J Transplant 2014;14(4):779-787.
23. Netto GJ, Watkins DL, Williams JW, Colby TV, dePetris G, Sharkey FE et al. Interobserver agreement in hepatitis C grading and staging and in the Banff grading schema for acute cellular rejection: the "hepatitis C 3" multi-institutional trial experience. Arch Pathol Lab Med 2006;130(8):1157-1162.
24. Demetris AJ, Ruppert K, Dvorchik I, Jain A, Minervini M, Nalesnik MA et al. Real-time monitoring of acute liver-allograft rejection using the Banff schema. Transplantation 2002;74(9):1290-1296.
25. Sebagh M, Blakolmer K, Falissard B, Roche B, Emile JF, Bismuth H et al. Accuracy of bile duct changes for the diagnosis of chronic liver allograft rejection: Reliability of the 1999 Banff schema. Hepatology 2002;35(1):117-125.
26. Horoldt BS, Burattin M, Gunson BK, Bramhall SR, Nightingale P, Hubscher SG et al. Does the Banff rejection activity index predict outcome in patients with early acute cellular rejection following liver transplantation? Liver Transpl 2006;12(7):1144-1151.
27. Ormonde DG, de Boer WB, Kierath A, Bell R, Shilkin KB, House AK et al. Banff schema for grading liver allograft rejection: utility in clinical practice. Liver Transpl Surg 1999;5(4):261-268.
28. Shaked A, Ghobrial RM, Merion RM, Shearon TH, Emond JC, Fair JH et al. Incidence and severity of acute cellular rejection in recipients undergoing adult living donor or deceased donor liver transplantation. Am J

Transplant 2009;9(2):301-308.
29. Lerut J, Mathys J, Verbaandert C, Talpe S, Ciccarelli O, Lemaire J et al. Tacrolimus monotherapy in liver transplantation: one-year results of a prospective, randomized, double-blind, placebo-controlled study. Ann Surg 2008;248(6):956-967.
30. Boillot O, Seket B, Dumortier J, Pittau G, Boucaud C, Bouffard Y et al. Thymoglobulin induction in liver transplant recipients with a tacrolimus, mycophenolate mofetil, and steroid immunosuppressive regimen: a five-year randomized prospective study. Liver Transpl 2009;15(11):1426-1434.
31. Abraham SC, Freese DK, Ishitani MB, Krasinskas AM, Wu TT. Significance of central perivenulitis in pediatric liver transplantation. Am J Surg Pathol 2008;32(10):1479-1488.
32. Khettry U, Backer A, Ayata G, Lewis WD, Jenkins RL, Gordon FD. Centrilobular histopathologic changes in liver transplant biopsies. Hum Pathol 2002;33(3):270-276.
33. Sanei MH, Schiano TD, Sempoux C, Fan C, Fiel MI. Acute cellular rejection resulting in sinusoidal obstruction syndrome and ascites postliver transplantation. Transplantation 2011;92(10):1152-1158.
34. Yamada H, Kondou H, Kimura T, Ikeda K, Tachibana M, Hasegawa Y et al. Humoral immunity is involved in the development of pericentral fibrosis after pediatric live donor liver transplantation. Pediatr Transplant 2012;16(8):858-865.
35. Venturi C, Sempoux C, Bueno J, Ferreres Pinas JC, Bourdeaux C, Abarca-Quinones J et al. Novel histologic scoring system for long-term allograft fibrosis after liver transplantation in children. Am J Transplant 2012;12(11):2986-2996.
36. Sebagh M, Castillo-Rama M, Azoulay D, Coilly A, Delvart V, Allard MA et al. Histologic findings predictive of a diagnosis of de novo autoimmune hepatitis after liver transplantation in adults. Transplantation 2013;96(7):670-678.
37. Castillo-Rama M, Sebagh M, Sasatomi E, Randhawa P, Isse K, Salgarkar AD et al. "Plasma Cell Hepatitis" in Liver Allografts: Identification and Characterization of an IgG4-Rich Cohort. Am J Transplant 2013;13(11):2966-2977.
38. Fiel MI, Schiano TD. Plasma cell hepatitis (de-novo autoimmune hepatitis) developing post liver transplantation. Curr Opin Organ Transplant 2012;17(3):287-292.
39. Levitsky J, Fiel MI, Norvell JP, Wang E, Watt KD, Curry MP et al. Risk for immune-mediated graft dysfunction in liver transplant recipients with recurrent HCV infection treated with pegylated interferon. Gastroenterology 2012;142(5):1132-1139.e1131.
40. Demetris AJ, Sebagh M. Plasma cell hepatitis in liver allografts: Variant of rejection or autoimmune hepatitis? Liver Transpl 2008;14(6):750-755.
41. Fiel MI, Agarwal K, Stanca C, Elhajj N, Kontorinis N, Thung SN et al. Posttransplant plasma cell hepatitis (de novo autoimmune hepatitis) is a variant of rejection and may lead to a negative outcome in patients with hepatitis C virus. Liver Transpl 2008;14(6):861-871.
42. Kerkar N, Hadzic N, Davies ET, Portmann B, Donaldson PT, Rela M et al. De-novo autoimmune hepatitis after liver transplantation. Lancet 1998;351(9100):409-413.
43. Ward SC, Schiano TD, Thung SN, Fiel MI. Plasma cell hepatitis in hepatitis C virus patients post- liver transplantation: case-control study showing poor outcome and predictive features in the liver explant. Liver Transpl 2009;15(12):1826-1833.
44. Wozniak LJ, Hickey MJ, Venick RS, Vargas JH, Farmer DG, Busuttil RW et al. Donor-Specific HLA Antibodies Are Associated With Late Allograft Dysfunction After Pediatric Liver Transplantation. Transplantation 2015.
45. Umemura T, Zen Y, Hamano H, Joshita S, Ichijo T, Yoshizawa K et al. Clinical significance of immunoglobulin G4-associated autoimmune hepatitis. J Gastroenterol 2011;46 Suppl 1:48-55.
46. Salcedo M, Vaquero J, Banares R, Rodriguez-Mahou M, Alvarez E, Vicario JL et al. Response to steroids in de novo autoimmune hepatitis after liver transplantation. Hepatology 2002;35(2):349-356.
47. Aguilera I, Sousa JM, Gavilan F, Bernardos A, Wichmann I, Nunez-Roldan A. Glutathione S- transferase T1 mismatch constitutes a risk factor for de novo immune hepatitis after liver transplantation. Liver Transpl 2004;10(9):1166-1172.
48. Pongpaibul A, Venick RS, McDiarmid SV, Lassman CR. Histopathology of de novo autoimmune hepatitis. Liver Transpl 2012;18(7):811-818.
49. Trivedi A, Schiano TD, Ward SC, Thung SN, Fiel MI, Levitsky J. C4d is Present in Portal Venules in Plasma Cell Hepatitis

and May Also be Used as a Predictor for its Development. In: American Association for the Study of Liver Disease; 2014; Boston: Hepatology; 2014. p. 457A.
50. Aguilera I, Sousa JM, Gavilan F, Gomez L, Alvarez-Marquez A, Nunez-Roldan A. Complement component 4d immunostaining in liver allografts of patients with de novo immune hepatitis. Liver transplantation : official publication of the American Association for the Study of Liver Diseases and the International Liver Transplantation Society 2011;17(7):779-788.
51. Aguilera I, Wichmann I, Sousa JM, Bernardos A, Franco E, Garcia-Lozano JR et al. Antibodies against glutathione S-transferase T1 (GSTT1) in patients with de novo immune hepatitis following liver transplantation. Clin Exp Immunol 2001;126(3):535-539.
52. Venick RS, McDiarmid SV, Farmer DG, Gornbein J, Martin MG, Vargas JH et al. Rejection and steroid dependence: unique risk factors in the development of pediatric posttransplant de novo autoimmune hepatitis. Am J Transplant 2007;7(4):955-963.
53. Mendes F, Couto CA, Levy C. Recurrent and de novo autoimmune liver diseases. Clinics in liver disease 2011;15(4):859-878.
54. Czaja AJ, Manns MP. Advances in the diagnosis, pathogenesis, and management of autoimmune hepatitis. Gastroenterology 2010;139(1):58-72 e54.
55. Hubscher SG. What is the long-term outcome of the liver allograft? Journal of Hepatology 2011;55(3):702-717.
56. Inui A, Sogo T, Komatsu H, Miyakawa H, Fujisawa T. Antibodies against cytokeratin 8/18 in a patient with de novo autoimmune hepatitis after living-donor liver transplantation. Liver transplantation : official publication of the American Association for the Study of Liver Diseases and the International Liver Transplantation Society 2005;11(5):504-507.
57. Huguet S, Vinh J, Johanet C, Samuel D, Gigou M, Zamfir O et al. Identification by proteomic tool of atypical anti-liver/kidney microsome autoantibodies targets in de novo autoimmune hepatitis after liver transplantation. Annals of the New York Academy of

Sciences 2007;1109:345-357.
58. Ohe H, Uchida Y, Yoshizawa A, Hirao H, Taniguchi M, Maruya E et al. Association of Anti-Human Leukocyte Antigen and Anti-Angiotensin II Type 1 Receptor Antibodies With Liver Allograft Fibrosis After Immunosuppression Withdrawal. Transplantation 2014;98(10):1105-1111.
59. Kerkar N, Yanni G. 'De novo' and 'recurrent' autoimmune hepatitis after liver transplantation: A comprehensive review. J Autoimmun 2016;66:17-24.
60. Demetris AJ, Jaffe R, Tzakis A, Ramsey G, Todo S, Belle S et al. Antibody-mediated rejection of human orthotopic liver allografts. A study of liver transplantation across ABO blood group barriers. American Journal of Pathology 1988;132(3):489-502.
61. Gordon RD, Iwatsuki S, Esquivel CO, Tzakis A, Todo S, Starzl TE. Liver transplantation across ABO blood groups. Surgery 1986;100(2):342-348.
62. Rego J, Prevost F, Rumeau JL, Modesto A, Fourtanier G, Durand D et al. Hyperacute rejection after ABO-incompatible orthotopic liver transplantation. Transplant Proc 1987;19(6):4589-4590.
63. Gugenheim J, Samuel D, Fabiani B, Saliba F, Castaing D, Reynes M et al. Rejection of ABO incompatible liver allografts in man. Transplant Proc 1989;21(1 Pt 2):2223-2224.
64. Sanchez-Urdazpal L, Sterioff S, Janes C, Schwerman L, Rosen C, Krom RA. Increased bile duct complications in ABO incompatible liver transplant recipients. Transplant Proc 1991;23(1 Pt 2):1440-1441.
65. Doyle HR, Marino IR, Morelli F, Doria C, Aldrighetti L, McMichael J et al. Assessing risk in liver transplantation. Special reference to the significance of a positive cytotoxic crossmatch. Ann Surg 1996;224(2):168-177.
66. Karruppan S, Ericzon BG, Moller E. Relevance of a positive crossmatch in liver transplantation. Transplant Int 1991;4:18-25.
67. Takaya S, Bronsther O, Iwaki Y, Nakamura K, Abu-Elmagd K, Yagihashi A et al. The adverse impact on liver transplantation of using positive cytotoxic crossmatch donors. Transplantation 1992;53(2):400-406.
68. Nikaein A, Backman L, Jennings L, Levy MF, Goldstein R, Gonwa T et al. HLA compatibility and liver transplant outcome. Improved patient survival by HLA and cross-matching. Transplantation 1994;58(7):786-792.
69. Bathgate AJ, McColl M, Garden OJ, Forsythe JL, Madhavan KK, Hayes PC. The effect of a positive T-lymphocytotoxic crossmatch on hepatic allograft survival and rejection. Liver Transpl Surg 1998;4(4):280-284.
70. Andres GA, Ansell ID, Halgrimson CG, Hsu KC, Porter KA, Starzl TE et al. Immunopathological studies of orthotopic human liver allografts. Lancet 1972;1(7745):275-280.
71. Gugenheim J, Charpentier B, Gigou M, Cuomo O, Calise F, Amorosa L et al. Delayed rejection of heart allografts after extracorporeal donor-specific liver hemoperfusion. Role of Kupffer cells. Transplantation 1988;45(3):628-632.
72. Gugenheim J, Amorosa L, Gigou M, Fabiani B, Rouger P, Gane P et al. Specific absorption of lymphocytotoxic alloantibodies by the liver in inbred rats. Transplantation 1990;50(2):309-313.
73. Saidman SL, Duquesnoy RJ, Demetris AJ, McCauley J, Ramos H, Mazariegos G et al. Combined liver-kidney transplantation and the effect of preformed lymphocytotoxic antibodies. Transpl Immunol 1994;2(1):61-67.
74. Eid A, Moore SB, Wiesner RH, DeGoey SR, Nielson A, Krom RA. Evidence that the liver does not always protect the kidney from hyperacute rejection in combined liver-kidney transplantation across a positive lymphocyte crossmatch. Transplantation 1990;50(2):331-334.
75. Olausson M, Mjörnstedt L, Nordén G, Rydberg L, Mölne J, Bäckman L et al. Successful combined partial auxiliary liver and kidney transplantation in highly sensitized cross-match positive recipients. Am J Transplant 2007;7(1):130-136.
76. Hubscher SG. Antibody-mediated rejection in the liver allograft. Curr Opin Organ Transplant 2012;17(3):280-286.
77. Nakamura K, Murase N, Becich MJ, Furuya T, Todo S, Fung JJ et al. Liver allograft rejection in sensitized recipients. Observations in a clinically relevant small animal model. American Journal of Pathology 1993;142(5):1383-1391.
78. Gugenheim J, Houssin D, Tamisier D, Franco D, Martin E, Lang P et al. Spontaneous long-term survival of liver allografts in inbred rats: influence of the hepatectomy of the recipient's own liver. Transplantation 1981;32(5):445-450.
79. Gugenheim J, Le Thai B, Rouger P, Gigou M, Gane P, Vial MC et al. Relationship between the liver and lymphocytotoxic alloantibodies in inbred rats. Specific absorption by nonparenchymal liver cells. Transplantation 1988;45(2):474-478.
80. Astarcioglu I, Cursio R, Reynes M, Gugenheim J. Increased risk of antibody-mediated rejection of reduced-size liver allografts. J Surg Res 1999;87(2):258-262.
81. Geissler EK, Graeb C, Tange S, Guba M, Jauch KW, Scherer MN. Effective use of donor MHC class I gene therapy in organ transplantation: prevention of antibody-mediated hyperacute heart allograft rejection in highly sensitized rat recipients. Hum Gene Ther 2000;11(3):459-469.
82. Demetris AJ, Isse K. Tissue biopsy monitoring of operational tolerance in liver allograft recipients. Curr Opin Organ Transplant 2013;18(3):345-353.
83. Muczynski KA, Ekle DM, Coder DM, Anderson SK. Normal human kidney HLA-DR-expressing renal microvascular endothelial cells: characterization, isolation, and regulation of MHC class II expression. J Am Soc Nephrol 2003;14(5):1336-1348.
84. Page C, Rose M, Yacoub M, Pigott R. Antigenic heterogeneity of vascular endothelium. Am J Pathol 1992;141(3):673-683.
85. Dar W, Agarwal A, Watkins C, Gebel HM, Bray RA, Kokko KE et al. Donor-directed MHC class I antibody is preferentially cleared from sensitized recipients of combined liver/kidney transplants. American journal of transplantation : official journal of the American Society of Transplantation and the American Society of Transplant Surgeons 2011;11(4):841-847.
86. O'Leary JG, Kaneku H, Jennings LW, Banuelos N, Susskind BM, Terasaki PI et al. Preformed class II donor-specific antibodies are associated with an increased risk of early rejection after liver transplantation. Liver Transpl 2013;19(9):973-980.

87. DeLeve LD. Liver sinusoidal endothelial cells in hepatic fibrosis. Hepatology 2014.
88. Tuijnman WB, Van Wichen DF, Schuurman HJ. Tissue distribution of human IgG Fc receptors CD16, CD32 and CD64: an immunohistochemical study. APMIS 1993;101(4):319-329.
89. Liu X, Xu J, Brenner DA, Kisseleva T. Reversibility of Liver Fibrosis and Inactivation of Fibrogenic Myofibroblasts. Curr Pathobiol Rep 2013;1(3):209-214.
90. Daar AS, Fuggle SV, Fabre JW, Ting A, Morris PJ. The detailed distribution of HLA-A, B, C antigens in normal human organs. Transplantation 1984;38:287-292.
91. Daar AS, Fuggle SV, Fabre JW, Ting A, Morris PJ. The detailed distribution of MHC Class II antigens in normal human organs. Transplantation 1984;38(3):293-298.
92. Lautenschlager I, Taskinen E, Inkinen K, Lehto VP, Virtanen I, Hayry P. Distribution of the major histocompatibility complex antigens on different cellular components of human liver. Cellular Immunology 1984;85(1):191-200.
93. Demetris AJ, Lasky S, Thiel DHV, Starzl TE, Whiteside T. Induction of DR/IA antigens in human liver allografts: An immunocytochemical and clinicopathologic analysis of twenty failed grafts. Transplantation 1985;40:504-509.
94. Ballardini G, Bianchi FB, Mirakian R, Fallani M, Pisi E, Bottazzo GF. HLA-A,B,C, HLA-D/DR and HLA-D/DQ expression on unfixed liver biopsy sections from patients with chronic liver disease. Clinical & Experimental Immunology 1987;70(1):35-46.
95. Barbatis C, Kelly P, Greveson J, Heryet A, McGee JO. Immunocytochemical analysis of HLA class II (DR) antigens in liver disease in man. Journal of Clinical Pathology 1987;40(8):879-884.
96. Steinhoff G, Wonigeit K, Pichlmayr R. Analysis of sequential changes in major histocompatibility complex expression in human liver grafts after transplantation. Transplantation 1988;45(2):394-401.
97. Gouw AS, Huitema S, Grond J, Slooff MJ, Klompmaker IJ, Gips CH et al. Early induction of MHC antigens in human liver grafts. An immunohistologic study. Am J Pathol 1988;133(1):82-94.
98. Steinhoff G, Wonigeit K, Schafers HJ, Haverich A. Sequential analysis of monomorphic and polymorphic major histocompatibility complex antigen expression in human heart allograft biopsy specimens. The Journal of heart transplantation 1989;8(5):360-370.
99. Steinhoff G. Major histocompatibility complex antigens in human liver transplants. J Hepatol 1990;11(1):9-15.
100. Hubscher SG, Adams DH, Elias E. Changes in the expression of major histocompatibility complex class II antigens in liver allograft rejection. Journal of Pathology 1990;162(2):165-171.
101. Terada T, Nakanuma Y, Hoso M, Obata H. Expression of HLA-DR antigen on hepatic vascular endothelial cells in idiopathic portal hypertension. Clin Exp Immunol 1991;84(2):303-307.
102. Terada T, Nakanuma Y, Obata H. HLA-DR expression on the microvasculature of portal tracts in idiopathic portal hypertension. Immunohistochemical characteristics and relation to portal phlebosclerosis. Arch Pathol Lab Med 1991;115(10):993-997.
103. O'Leary JG, Cai J, Freeman R, Banuelos N, Hart B, Johnson M et al. Proposed Diagnostic Criteria for Chronic Antibody-Mediated Rejection in Liver Allografts. Am J Transplant 2015.
104. Raut V, Uemoto S. Management of ABO-incompatible living-donor liver transplantation: past and present trends. Surg Today 2011;41(3):317-322.
105. Haga H, Egawa H, Shirase T, Miyagawa A, Sakurai T, Minamiguchi S et al. Periportal edema and necrosis as diagnostic histological features of early humoral rejection in ABO-incompatible liver transplantation. Liver Transpl 2004;10(1):16-27.
106. Haga H, Egawa H, Fujimoto Y, Ueda M, Miyagawa-Hayashino A, Sakurai T et al. Acute humoral rejection and C4d immunostaining in ABO blood type-incompatible liver transplantation. Liver Transpl 2006;12(3):457-464.
107. Demetris AJ, Nakamura K, Yagihashi A, Iwaki Y, Takaya S, Hartman GG et al. A clinicopathological study of human liver allograft recipients harboring preformed IgG lymphocytotoxic antibodies. Hepatology 1992;16(3):671-681.
108. Manez R, Kelly RH, Kobayashi M, Takaya S, Bronsther O, Kramer D et al. - Immunoglobulin G lymphocytotoxic antibodies in clinical liver transplantation: studies toward further defining their significance. Hepatology 1995;21(5):1345-1352.
109. O'Leary JG, Klintmalm GB. Impact of donor-specific antibodies on results of liver transplantation. Curr Opin Organ Transplant 2013;18(3):279-284.
110. Al-Sibae MR, Koffron AJ, Raofi V. Does a positive pretransplant crossmatch affect long-term outcome in liver transplantation? Transplantation 2011;91(3):261-262.
111. Chan KM, Lee CS, Wu TJ, Lee CF, Chen TC, Lee WC. Clinical perspective of acute humoral rejection after blood type-compatible liver transplantation. Transplantation 2011;91(5):e29-30.
112. Lunz J, Ruppert KM, Cajaiba MM, Isse K, Bentlejewski CA, Minervini M et al. Re-examination of the Lymphocytotoxic Crossmatch in Liver Transplantation: Can C4d Stains Help in Monitoring? American journal of transplantation : official journal of the American Society of Transplantation and the American Society of Transplant Surgeons 2012;12(1):171-182.
113. Taner T, Gandhi MJ, Sanderson SO, Poterucha CR, De Goey SR, Stegall MD et al. Prevalence, course and impact of HLA donor-specific antibodies in liver transplantation in the first year. Am J Transplant 2012;12(6):1504-1510.
114. Tambur AR, Herrera ND, Haarberg KM, Cusick MF, Gordon RA, Leventhal JR et al. Assessing Antibody Strength: Comparison of MFI, C1q, and Titer Information. Am J Transplant 2015;15(9):2421-2430.
115. O'Leary JG, Kaneku H, Demetris AJ, Marr JD, Shiller SM, Susskind BM et al. Antibody-mediated rejection as a contributor to previously unexplained early liver allograft loss. Liver Transpl 2014;20(2):218-227.
116. O'Leary JG, Michelle Shiller S, Bellamy C, Nalesnik MA, Kaneku H, Jennings LW et al. Acute liver allograft antibody-mediated rejection: an inter-institutional study of significant histopathological features. Liver Transpl 2014;20(10):1244-1255.
117. Starzl TE, Demetris AJ, Todo S. Evidence of hyperacute rejection of human liver grafts: The case of the canary kidneys. Clin Transpl 1989;3:37-45.
118. Hori T, Egawa H, Takada Y, Oike F, Ogura Y, Ogawa K et al. Fatal impact of lymphocyte cross- matching upon humoral rejection after adult living related liver transplantation. Transpl Int 2010;23(3):338-340.
119. Fung J, Griffin M, Duquesnoy R, Shaw B, Starzl T. Successful sequential liver-kidney transplantation in a patient with

performed lymphocytotoxic antibodies. Transplantation Proceedings
1987;19(1 Pt 1):767-768.
120. O'Leary JG, Gebel HM, Ruiz R, Bray RA, Marr JD, Zhou XJ et al. Class II alloantibody and mortality in simultaneous liver-kidney transplantation. Am J Transplant 2013;13(4):954-960.
121. Del Bello A, Congy-Jolivet N, Muscari F, Lavayssière L, Esposito L, Cardeau-Desangles I et al.
Prevalence, incidence and risk factors for donor-specific anti-HLA antibodies in maintenance liver transplant patients. Am J Transplant 2014;14(4):867-875.
122. Colvin RB. Dimensions of antibody-mediated rejection. American journal of transplantation : official journal of the American Society of Transplantation and the American Society of Transplant Surgeons 2010;10(7):1509-1510.
123. Colvin RB. Antibody-mediated renal allograft rejection: diagnosis and pathogenesis. J Am Soc
Nephrol 2007;18(4):1046-1056.
124. Mauiyyedi S, Pelle PD, Saidman S, Collins AB, Pascual M, Tolkoff-Rubin NE et al. Chronic humoral rejection: identification of antibody-mediated chronic renal allograft rejection by C4d deposits in peritubular capillaries. J Am Soc Nephrol 2001;12(3):574-582.
125. Martin T, Schwartz J, Demetris A, Comstock J, Lowichik A, Book L. Plasmapheresis treatment of antibody-mediated rejection in an A2 donor to O pediatric liver transplant recipient. Pediatr Transplant
2009.
126. Egawa H, Uemoto S, Inomata Y, Shapiro AM, Asonuma K, Kiuchi T et al. Biliary complications in pediatric living related liver transplantation. Surgery 1998;124(5):901-910.
127. Sebagh M, Farges O, Kalil A, Samuel D, Bismuth H, Reynes M. Sclerosing cholangitis following
human orthotopic liver transplantation. Am J Surg Pathol 1995;19(1):81-90.
128. Salah A, Fujimoto M, Yoshizawa A, Yurugi K, Miyagawa-Hayashino A, Sumiyoshi S et al. Application of complement component 4d immunohistochemistry to ABO-compatible and ABO- incompatible liver transplantation. Liver Transpl 2014;20(2):200-209.
129. Kakizoe S, Yanaga K, Starzl TE, Demetris AJ. Evaluation of protocol before transplantation and after reperfusion biopsies from human orthotopic liver allografts: considerations of preservation and early immunological injury. Hepatology 1990;11(6):932-941.
130. Watson R, Kozlowski T, Nickeleit V, Woosley JT, Schmitz JL, Zacks SL et al. Isolated donor specific alloantibody-mediated rejection after ABO compatible liver transplantation. Am J Transplant
2006;6(12):3022-3029.
131. Rostron A, Carter V, Mutunga M, Cavanagh G, O'Suilleabhain C, Burt A et al. A case of acute humoral rejection in liver transplantation: successful treatment with plasmapheresis and mycophenolate mofetil. Transpl Int 2005;18(11):1298-1301.
132. Aoki T, Sugawara Y, Takahashi M, Kawaguchi Y, Kaneko J, Yamashiki N et al. Living donor liver transplantation using sensitized lymphocytotoxic crossmatch positive graft. J Gastroenterol
2012;47(4):486-488.
133. Kheradmand T, Anthony TL, Harland RC, Testa G, Hart J, Renz J et al. Antibody-mediated rejection in ABO compatible husband to wife living donor liver transplant and review of the literature. Hum Immunol 2014;75(6):578-583.
134. Iacob S, Cicinnati VR, Dechêne A, Lindemann M, Heinemann FM, Rebmann V et al. Genetic,
immunological and clinical risk factors for biliary strictures following liver transplantation. Liver Int
2012;32(8):1253-1261.
135. Song SH, Kim MS, Lee JJ, Ju MK, Lee JG, Lee J et al. Effect of donor-specific antibodies and panel reactive antibodies in living donor liver transplant recipients. Ann Surg Treat Res 2015;88(2):100-105.
136. Kozlowski T, Rubinas T, Nickeleit V, Woosley J, Schmitz J, Collins D et al. Liver allograft antibody- mediated rejection with demonstration of sinusoidal C4d staining and circulating donor-specific antibodies. Liver transplantation : official publication of the American Association for the Study of Liver Diseases and the International Liver Transplantation Society 2011;17(4):357-368.
137. Kozlowski T, Andreoni K, Schmitz J, Hayashi PH, Nickeleit V. Sinusoidal C4d deposits in liver allografts indicate an antibody-mediated response: diagnostic considerations in the evaluation of liver allografts. Liver Transpl 2012;18(6):641-658.
138. Dankof A, Schmeding M, Morawietz L, Gunther R, Krukemeyer MG, Rudolph B et al. Portal capillary C4d deposits and increased infiltration by macrophages indicate humorally mediated mechanisms in acute cellular liver allograft rejection. Virchows Arch 2005;447(1):87-93.
139. Musat AI, Agni RM, Wai PY, Pirsch JD, Lorentzen DF, Powell A et al. The significance of donor-
specific HLA antibodies in rejection and ductopenia development in ABO compatible liver transplantation. American journal of transplantation : official journal of the American Society of Transplantation and the American Society of Transplant Surgeons 2011;11(3):500-510.
140. Bellamy CO. Complement C4d immunohistochemistry in the assessment of liver allograft biopsy samples: Applications and pitfalls. Liver transplantation : official publication of the American Association for the Study of Liver Diseases and the International Liver Transplantation Society 2011;17(7):747-750.
141. Kaneku H, O'Leary JG, Banuelos N, Jennings LW, Susskind BM, Klintmalm GB et al. De novo donor-specific HLA antibodies decrease patient and graft survival in liver transplant recipients. Am J Transplant 2013;13(6):1541-1548.
142. Kaneku H, O'Leary JG, Taniguchi M, Susskind BM, Terasaki PI, Klintmalm GB. Donor-specific
human leukocyte antigen antibodies of the immunoglobulin G3 subclass are associated with chronic rejection and graft loss after liver transplantation. Liver Transpl 2012;18(8):984-992.
143. O'Leary J, Kaneku H, Banuelos N, Jennings L, Klintmalm G, Terasaki P. Impact of IgG3 subclass and C1q-fixing donor specific antibodies on rejection and survival in liver transplantation. American Journal of Transplantation 2015;(in press).
144. Feng S, Demetris AJ, Ekong U, Girnita A, Kanaparthi S, Soppe C et al. Serum and Tissue DSA Subclass, Stellate and Endothelial Phenotype Monitoring in ITN029ST Tolerance Pediatric LIver Transplant Recipients over 5+ Years of Follow-up. In: Joint International Conference of ILTS, ELITA & LICAGE; 2014; London; 2014.
145. Feng S, Ekong UD, Lobritto SJ, Demetris AJ, Roberts JP, Rosenthal P et al. Complete immunosuppression withdrawal and subsequent allograft function among pediatric recipients of parental living donor liver transplants. Jama
2012;307(3):283-293.
146. Smith RN, Colvin RB. Chronic alloantibody mediated rejection. Semin Immunol 2012;24(2):115-
121.
147. Miyagawa-Hayashino A, Yoshizawa A, Uchida Y, Egawa H, Yurugi K, Masuda S et al. Progressive graft fibrosis and donor-

specific human leukocyte antigen antibodies in pediatric late liver allografts. Liver Transpl 2012;18(11):1333-1342.
148. Iacob S, Cicinnati VR, Lindemann M, Heinemann FM, Radtke A, Kaiser GM et al. Donor-Specific Anti-HLA Antibodies and Endothelial C4d Deposition-Association With Chronic Liver Allograft Failure. Transplantation 2015.
149. Cohen D, Colvin RB, Daha MR, Drachenberg CB, Haas M, Nickeleit V et al. Pros and cons for C4d as a biomarker. Kidney Int 2012;81(7):628-639.
150. Solez K, Colvin RB, Racusen LC, Sis B, Halloran PF, Birk PE et al. Banff '05 Meeting Report: differential diagnosis of chronic allograft injury and elimination of chronic allograft nephropathy ('CAN'). American journal of transplantation : official journal of the American Society of Transplantation and the American Society of Transplant Surgeons 2007;7(3):518-526.
151. Shimizu A, Ishii E, Kuwahara N, Arai T, Kanzaki G, Higo S et al. Chronic antibody-mediated responses may mediate chronic rejection in rat orthotopic liver transplantation. Transplant Proc 2013;45(5):1743-1747.
152. Wan R, Ying W, Zeng L, Deng X, Chen H, Gao L. Antibody-mediated response in rat liver chronic rejection. Transplant Proc 2011;43(5):1976-1979.
153. O'Leary J, Cai J, Freeman R, Banuelos N, Hart B, Johnson M et al. Proposed Diagnostic Criteria for Chronic Antibody-mediated Rejection in Liver Allografts. American Journal of Transplantation 2015;(in press).
154. Donaldson PT, Alexander GJ, O'Grady J, Neuberger J, Portmann B, Thick M et al. Evidence for an immune response to HLA class I antigens in the vanishing-bile duct syndrome after liver transplantation. Lancet 1987;1(8539):945-951.
155. Matsumoto Y, McCaughan GW, Painter DM, Bishop GA. Evidence that portal tract microvascular destruction precedes bile duct loss in human liver allograft rejection. Transplantation 1993;56(1):69-75.
156. Donaldson PT, Thomson LJ, Heads A, Underhill JA, Vaughan RW, Rolando N et al. - IgG donor- specific crossmatches are not associated with graft rejection or poor graft survival after liver transplantation. An assessment by cytotoxicity and flow cytometry. Transplantation 1995;60(9):1016-1023.
157. Grabhorn E, Binder TM, Obrecht D, Brinkert F, Lehnhardt A, Herden U et al. Long-Term Clinical Relevance of De Novo Donor-Specific Antibodies After Pediatric Liver Transplantation. Transplantation 2015.
158. Markiewicz-Kijewska M, Kaliciński P, Kluge P, Piątosa B, Jankowska I, Rękawek A et al. Immunological factors and liver fibrosis in pediatric liver transplant recipients. Ann Transplant 2015;20:279-284.
159. Batts KP, Moore SB, Perkins JD, Wiesner RH, Grambsch PM, Krom RA. Influence of positive lymphocyte crossmatch and HLA mismatching on vanishing bile duct syndrome in human liver allografts. Transplantation 1988;45(2):376-379.
160. Kosola S, Lampela H, Jalanko H, Makisalo H, Lohi J, Arola J et al. Low-dose steroids associated with milder histological changes after pediatric liver transplantation. Liver Transpl 2013;19(2):145-154.
161. Yoshitomi M, Koshiba T, Haga H, Li Y, Zhao X, Cheng D et al. Requirement of protocol biopsy before and after complete cessation of immunosuppression after liver transplantation. Transplantation 2009;87(4):606-614.
162. Koshiba T, Li Y, Takemura M, Wu Y, Sakaguchi S, Minato N et al. Clinical, immunological, and pathological aspects of operational tolerance after pediatric living-donor liver transplantation. Transpl Immunol 2007;17(2):94-97.
163. O'Leary JG, Kaneku H, Jennings L, Susskind BM, Terasaki PI, Klintmalm GB. Donor-specific alloantibodies are associated with fibrosis progression after liver transplantation in hepatitis C virus- infected patients. Liver Transpl 2014;20(6):655-663.
164. Hoshino J, Kaneku H, Everly MJ, Greenland S, Terasaki PI. Using donor-specific antibodies to monitor the need for immunosuppression. Transplantation 2012;93(11):1173-1178.
165. Demetris AJ, Lunz JG, 3rd, Randhawa P, Wu T, Nalesnik M, Thomson AW. Monitoring of human liver and kidney allograft tolerance: a tissue/histopathology perspective. Transpl Int 2009;22(1):120-141.
166. Benitez C, Londono MC, Miquel R, Manzia TM, Abraldes JG, Lozano JJ et al. Prospective multicenter clinical trial of immunosuppressive drug withdrawal in stable adult liver transplant recipients. Hepatology 2013.
167. Martelius T, Halme L, Arola J, Hockerstedt K, Lautenschlager I. Vascular deposition of complement C4d is increased in liver allografts with chronic rejection. Transpl Immunol 2009;21(4):244-246.
168. Egawa H, Miyagawa-Hayashino A, Haga H, Teramukai S, Yoshizawa A, Ogawa K et al. Non- inflammatory centrilobular sinusoidal fibrosis in pediatric liver transplant recipients under tacrolimus withdrawal. Hepatol Res 2012;42(9):895-903.
169. Li Y, Lu L, Qian S, Fung JJ, Lin F. Hepatic Stellate Cells Directly Inhibit B Cells via Programmed Death-Ligand 1. J Immunol 2016;196(4):1617-1625.
170. Rockey DC, Caldwell SH, Goodman ZD, Nelson RC, Smith AD. Liver biopsy. Hepatology 2009;49(3):1017-1044.
171. Demetris AJ, Ruppert K. Pathologist's perspective on liver needle biopsy size? J Hepatol 2003;39(2):275-277.
172. Sapir-Pichhadze R, Curran SP, John R, Tricco AC, Uleryk E, Laupacis A et al. A systematic review of the role of C4d in the diagnosis of acute antibody-mediated rejection. Kidney Int 2015;87(1):182-194.
173. Bellamy CO, Herriot MM, Harrison DJ, Bathgate AJ. C4d immunopositivity is uncommon in ABO- compatible liver allografts, but correlates partially with lymphocytotoxic antibody status. Histopathology 2007;50(6):739-749.
174. Miller DV, Roden AC, Gamez JD, Tazelaar HD. Detection of C4d deposition in cardiac allografts: a comparative study of immunofluorescence and immunoperoxidase methods. Arch Pathol Lab Med 2010;134(11):1679-1684.
175. Ludovico-Martins H, Silva C, Teodoro WR, Martini Filho D, Noronha IL. Analysis of different staining techniques for c4d detection in renal allograft biopsies. Transplant Proc 2009;41(3):862-865.
176. Seemayer CA, Gaspert A, Nickeleit V, Mihatsch MJ. C4d staining of renal allograft biopsies: a comparative analysis of different staining techniques. Nephrol Dial Transplant 2007;22(2):568-576.
177. Troxell ML, Weintraub LA, Higgins JP, Kambham N. Comparison of C4d immunostaining methods in renal allograft biopsies. Clin J Am Soc Nephrol 2006;1(3):583-591.

178. Nadasdy GM, Bott C, Cowden D, Pelletier R, Ferguson R, Nadasdy T. Comparative study for the detection of peritubular capillary C4d deposition in human renal allografts using different methodologies. Hum Pathol 2005;36(11):1178-1185.
179. Chantranuwat C, Qiao JH, Kobashigawa J, Hong L, Shintaku P, Fishbein MC. Immunoperoxidase staining for C4d on paraffin-embedded tissue in cardiac allograft endomyocardial biopsies: comparison to frozen tissue immunofluorescence. Appl Immunohistochem Mol Morphol 2004;12(2):166-171.
180. Bu X, Zheng Z, Yu Y, Zeng L, Jiang Y. Significance of C4d deposition in the diagnosis of rejection after liver transplantation. Transplant Proc 2006;38(5):1418-1421.
181. Jain A, Mohanka R, Orloff M, Abt P, Romano J, Bryan L et al. Characterization of CD4, CD8, CD56 positive lymphocytes and C4d deposits to distinguish acute cellular rejection from recurrent hepatitis C in post-liver transplant biopsies. Clin Transplant 2006;20(5):624-633.
182. Krukemeyer MG, Moeller J, Morawietz L, Rudolph B, Neumann U, Theruvath T et al. Description of B lymphocytes and plasma cells, complement, and chemokines/receptors in acute liver allograft rejection. Transplantation 2004;78(1):65-70.
183. Sakashita H, Haga H, Ashihara E, Wen MC, Tsuji H, Miyagawa-Hayashino A et al. Significance of C4d staining in ABO-identical/compatible liver transplantation. Mod Pathol 2007;20(6):676-684.
184. Sawada T, Shimizu A, Kubota K, Fuchinoue S, Teraoka S. Lobular damage caused by cellular and humoral immunity in liver allograft rejection. Clin Transplant 2005;19(1):110-114.
185. Troxell ML, Higgins JP, Kambham N. Evaluation of C4d staining in liver and small intestine allografts. Arch Pathol Lab Med 2006;130(10):1489-1496.
186. Bouron-Dal Soglio D, Rougemont AL, Herzog D, Soucy G, Alvarez F, Fournet JC. An immunohistochemical evaluation of C4d deposition in pediatric inflammatory liver diseases. Hum Pathol 2008;39(7):1103-1110.
187. Schmeding M, Dankof A, Krenn V, Krukemeyer MG, Koch M, Spinelli A et al. C4d in acute rejection after liver transplantation--a valuable tool in differential diagnosis to hepatitis C recurrence. Am J Transplant 2006;6(3):523-530.
188. Silva MA, Mirza DF, Murphy N, Richards DA, Reynolds GM, Wigmore SJ et al. Intrahepatic complement activation, sinusoidal endothelial injury, and lactic acidosis are associated with initial poor function of the liver after transplantation. Transplantation 2008;85(5):718-725.
189. Corrêa RR, Machado JR, da Silva MV, Helmo FR, Guimarães CS, Rocha LP et al. The importance of C4d in biopsies of kidney transplant recipients. Clin Dev Immunol 2013;2013:678180.
190. Cornell LD. Renal allograft pathology in the sensitized patient. Curr Opin Organ Transplant 2013;18(3):327-336.
191. Song GW, Lee SG, Hwang S, Kim KH, Ahn CS, Moon DB et al. ABO-Incompatible Adult Living Donor Liver Transplantation Under the Desensitization Protocol With Rituximab. Am J Transplant 2016;16(1):157-170.
192. Kim P, Demetris A, O'Leary J. Prevention and Treatment of Liver Allograft Antibody Mediated Rejection and the Role of the “2-Hit Hypothesis” Current Opinion in Transplantation 2016(In Press).
193. Musat AI, Pigott CM, Ellis TM, Agni RM, Leverson GE, Powell AJ et al. Pretransplant donor- specific anti-HLA antibodies as predictors of early allograft rejection in ABO-compatible liver transplantation. Liver Transpl 2013;19(10):1132-1141.
194. Castillo-Rama M, Castro MJ, Bernardo I, Meneu-Diaz JC, Elola-Olaso AM, Calleja-Antolin SM et al. Preformed antibodies detected by cytotoxic assay or multibead array decrease liver allograft survival: role of human leukocyte antigen compatibility. Liver Transpl 2008;14(4):554-562.
195. Musat AI, Agni RM, Wai PY, Pirsch JD, Lorentzen DF, Powell A et al. The significance of donor-specific HLA antibodies in rejection and ductopenia development in ABO compatible liver transplantation. Am J Transplant 2011;11(3):500-510.
196. Paterno F, Shiller M, Tillery G, O'Leary JG, Susskind B, Trotter J et al. Bortezomib for acute antibody-mediated rejection in liver transplantation. Am J Transplant 2012;12(9):2526-2531.
197. Kozlowski T, Rubinas T, Nickeleit V, Woosley J, Schmitz J, Collins D et al. Liver allograft antibody- mediated rejection with demonstration of sinusoidal C4d staining and circulating donor-specific antibodies. Liver Transpl 2011;17(4):357-368.
198. Kamar N, Lavayssiere L, Muscari F, Selves J, Guilbeau-Frugier C, Cardeau I et al. Early plasmapheresis and rituximab for acute humoral rejection after ABO-compatible liver transplantation. World J Gastroenterol 2009;15(27):3426-3430.
199. Schadde E, d'Alessandro AM, Musat AI, Torrealba JR, Knechtle SJ. Donor-specific HLA-antibody- mediated humoral rejection in a liver transplant recipient fully reversed with plasmapheresis and immunoglobulin. Clin Transpl 2006:479-482.
200. Wilson CH, Agarwal K, Carter V, Burt AD, Hubscher S, Talbot D et al. Late humoral rejection in a compliant ABO-compatible liver transplant recipient. Transplantation 2006;82(7):988-989.
201. Del Bello A, Congy-Jolivet N, Danjoux M, Muscari F, Lavayssiere L, Esposito L et al. De novo donor-specific anti-HLA antibodies mediated rejection in liver-transplant patients. Transpl Int 2015;28(12):1371-1382.
202. O'Leary JG, Samaniego M, Barrio MC, Potena L, Zeevi A, Djamali A et al. The Influence of Immunosuppressive Agents on the Risk of De Novo Donor-Specific HLA Antibody Production in Solid Organ Transplant Recipients. Transplantation 2016;100(1):39-53.
203. Wong T, Nouri-Aria KT, Devlin J, Portmann B, Williams R. Tolerance and latent cellular rejection in long-term liver transplant recipients. Hepatology 1998;28(2):443-449.
204. Feng S, Bucuvalas J, Demetris A, Spain K, Mazariegos G, Burrell B et al. Deceased Donor and Class II Donor Specific Antibody Predict Interface Activity While Increased Age at Time of Biopsy Predicts Fibrosis in Long-Term Pediatric Liver Allografts With Normal Liver Tests: iWITH Clinical Trial [abstract]. . In. *Am J Transplant.* 2015; 15 (suppl 3). 2015.
205. Bohne F, Martinez-Llordella M, Lozano JJ, Miquel R, Benitez C, Londono MC et al. Intra-graft expression of genes involved in iron homeostasis predicts the development of operational tolerance in human liver transplantation. The Journal of clinical investigation 2012;122(1):368-382.
206. Taubert R, Danger R, Londoño MC, Christakoudi S, Martinez M, Rimola A et al. Hepatic infiltrates in operational tolerant patients after liver transplantation show enrichment of regulatory T cells before proinflammatory genes are down-regulated. Am J Transplant 2015.
207. Dragun D, Catar R, Philippe A. Non-HLA antibodies in solid organ transplantation: recent concepts and clinical

relevance. Curr Opin Organ Transplant 2013;18(4):430-435.
208. Sellares J, Reeve J, Loupy A, Mengel M, Sis B, Skene A et al. Molecular diagnosis of antibody- mediated rejection in human kidney transplants. Am J Transplant 2013;13(4):971-983.
209. Wu KY, Budde K, Schmidt D, Neumayer HH, Rudolph B. Acute cellular rejection with isolated v- lesions is not associated with more favorable outcomes than vascular rejection with more tubulointerstitial inflammations. Clin Transplant 2014;28(4):410-418.

Figure 1.

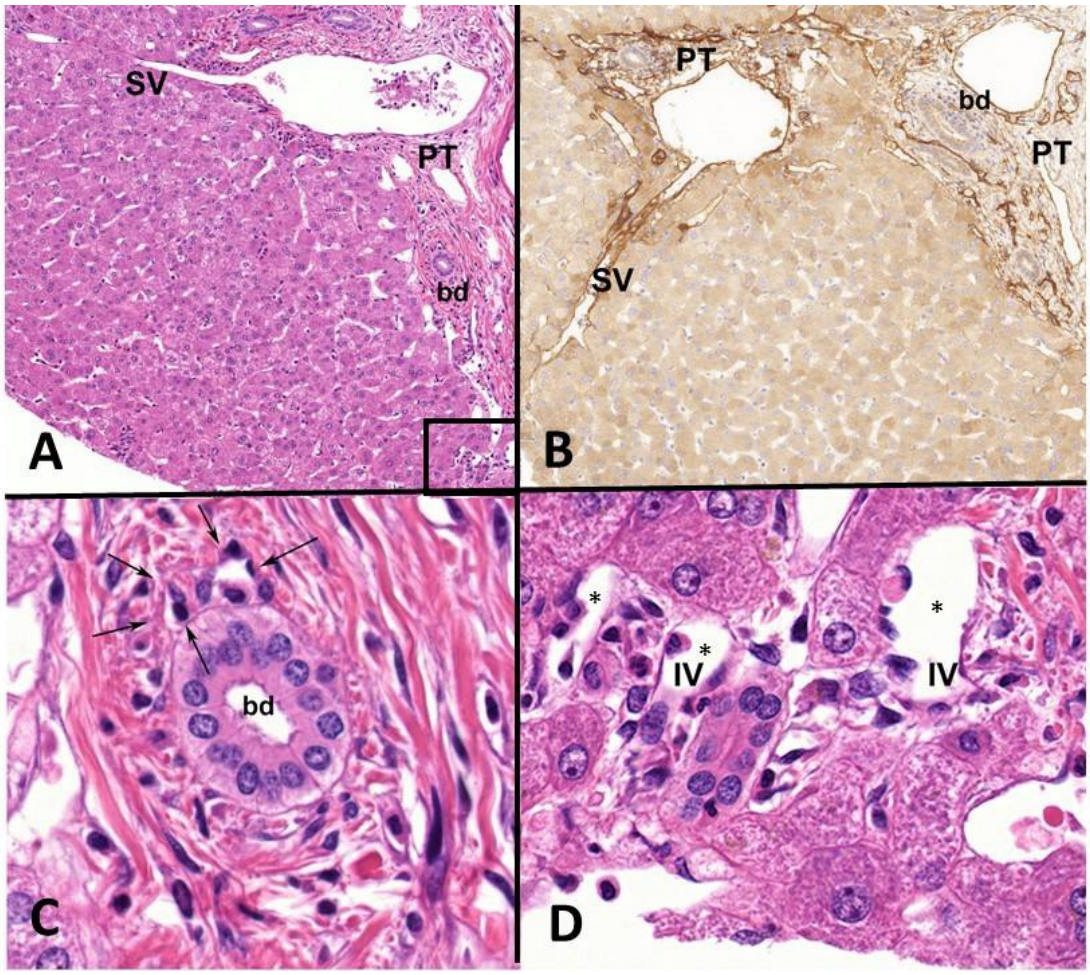

Figure 2.

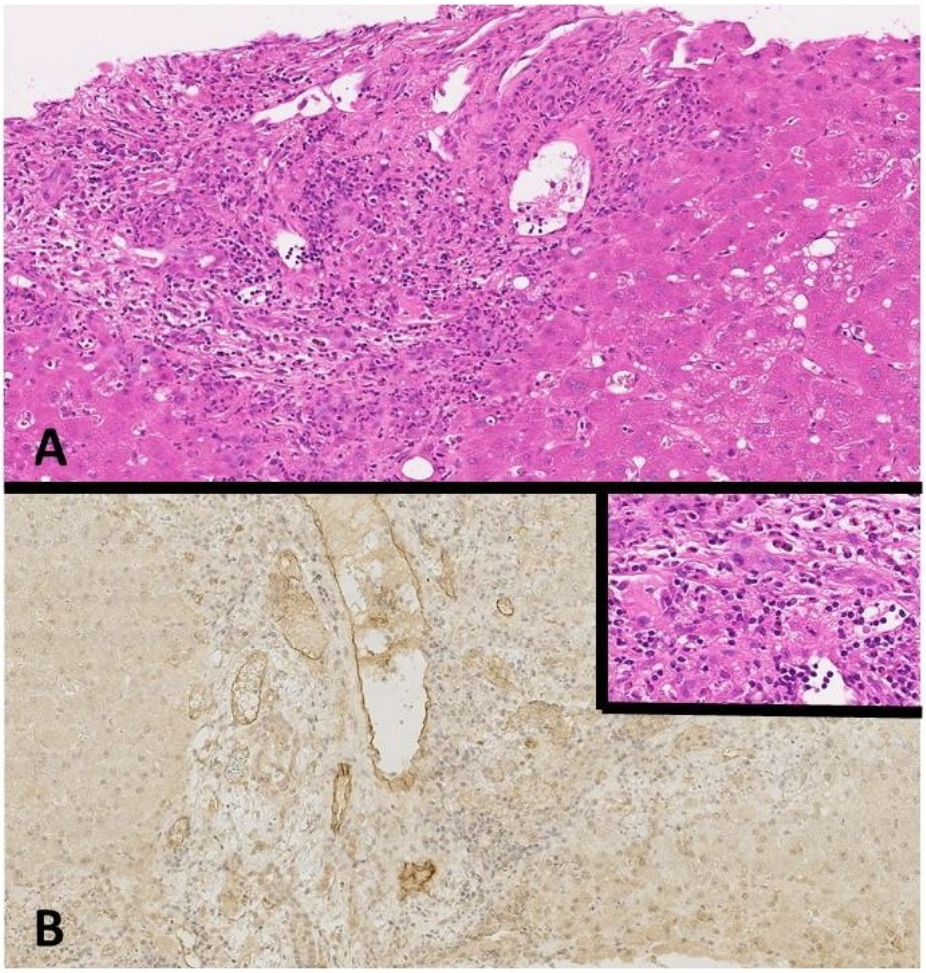

Figure 3.

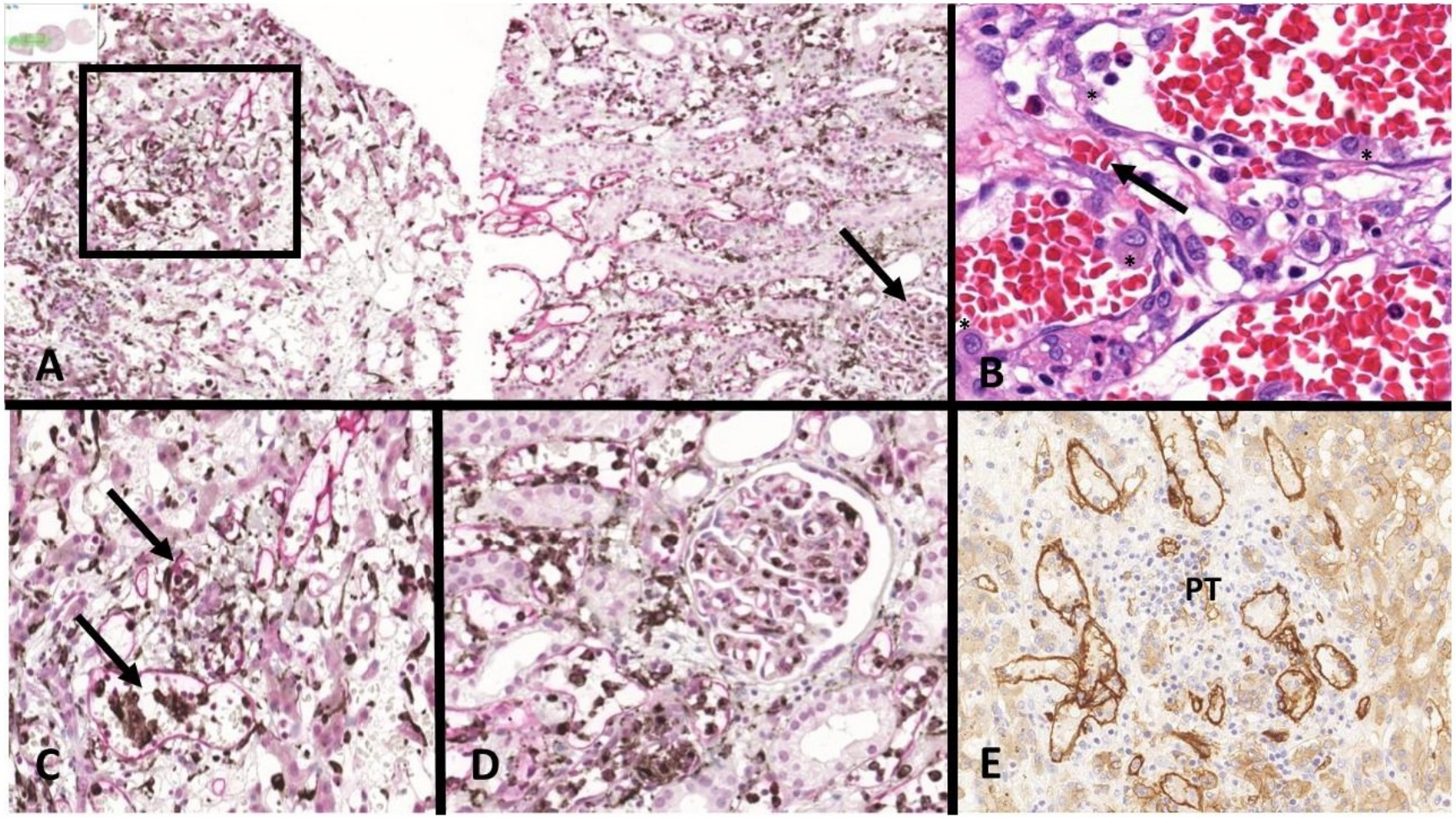

Figure 4.

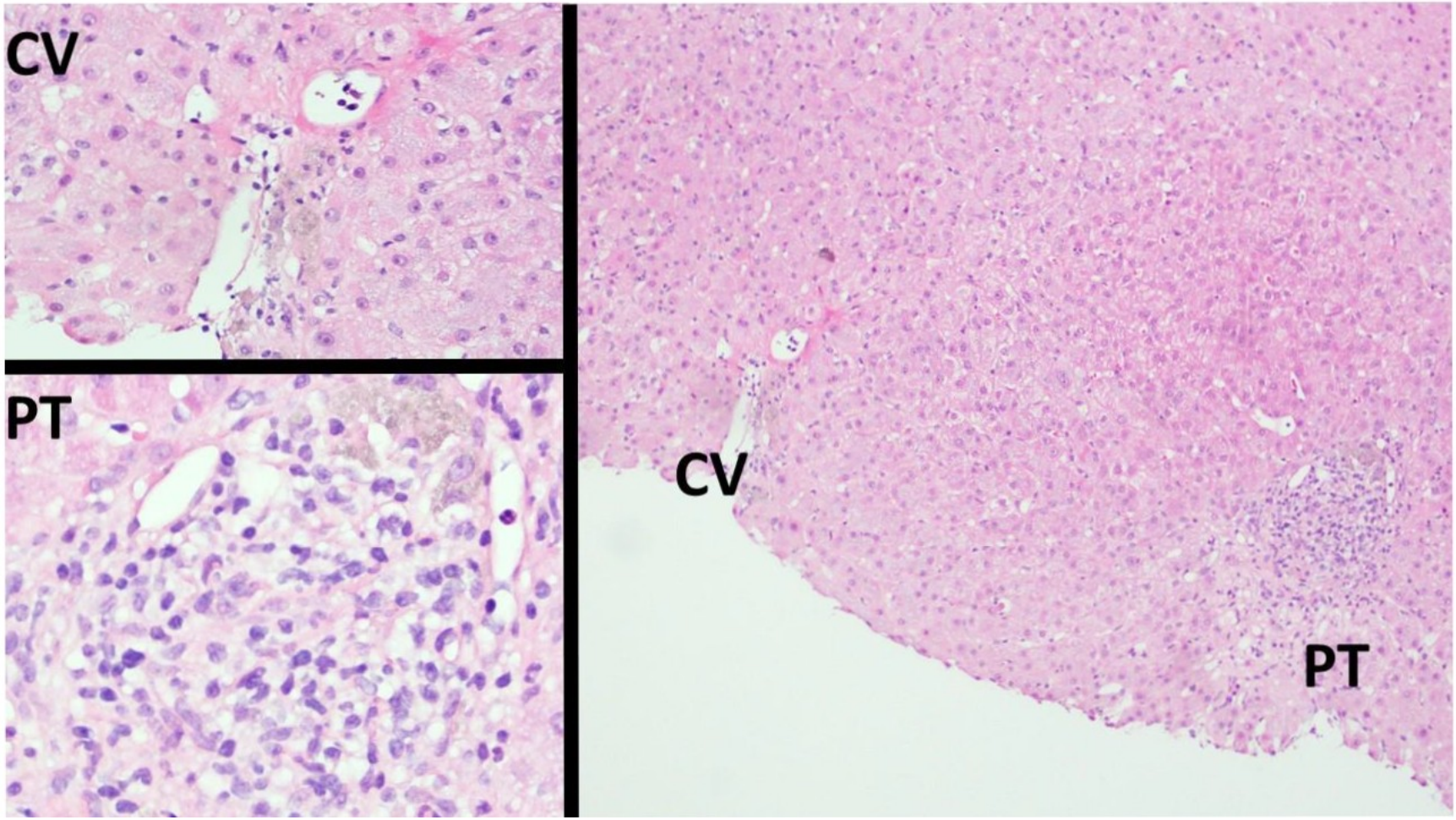

Figure 5.

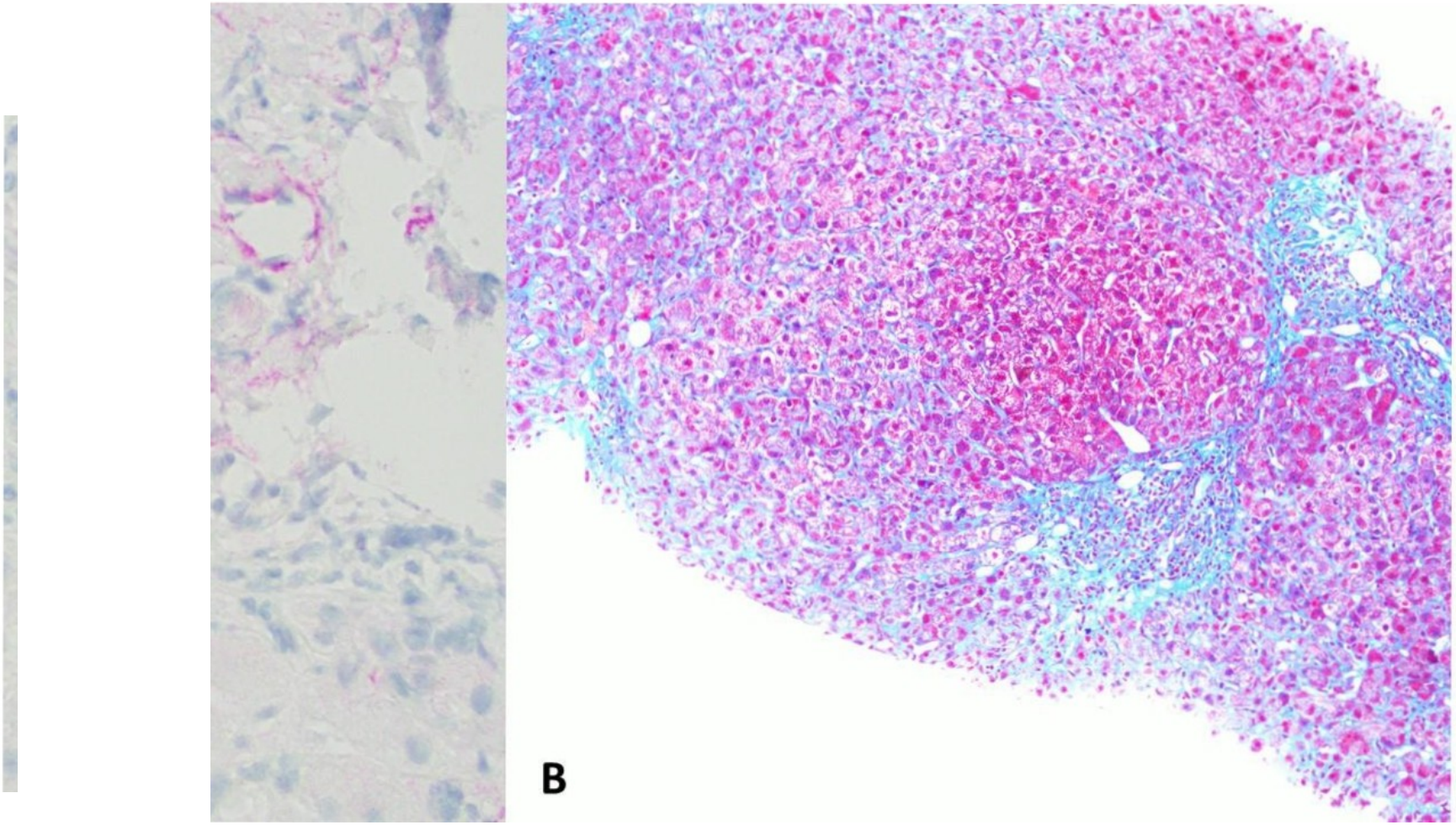

A

Banff 2016 Participants

Demetris, A. Jake Director; University of Pittsburgh Medical Center, Pittsburgh Bellamy, Chris Co-Director; The University of Edinburgh, Edinburgh Hubscher, Stefan Co-Director; University of Birmingham, Birmingham, UK Adeyi, Oyedele Toronto General Hospital/Research Institute (UHN), Toronto Alexander, Graeme University of Cambridge, Cambridge

Baiocchi, Leonardo University of Rome Tor Vergata, Rome, Italy
Balasubramanian, Manju Einstein Medical Center, Philadelphia
Batal, Ibrahim Columbia University Medical Center, New York
Bellamy, Christopher The University of Edinburgh, Edinburgh
Bhan, Atul K. Harvard Medical School, Massachussets General Hospital, Boston
Bucuvalas, John Cincinnati Children's Hospital Medical Center, Cincinnati
Cerski, Carlos T. S. Universidade Federal do Rio Grande do Sul, Hospital de Clınicas de Porto Alegre, Porto Alegre, Brazil
Charlotte, Frédéric Hôpital Pitié-Salpêtrière, Paris, France
Colvin, Robert B. Harvard Medical School, Massachussets General Hospital, Boston
Czaja, Albert J. Mayo Clinic College of Medicine, Rochester, MN Del Bello, Arnaud Hopital Rangueil, Toulouse
De Vera, Michael Loma Linda University, Loma Linda
ElMonayeri, Magda Ain Shams University, Cairo
Feng, Sandy UCSF Medical Center, San Francisco
Fiel, MariaIsabel Mount Sinai Hospital, New York
Fontes, Paulo University of Pittsburgh Medical Center, Pittsburgh
Fung, John J. Cleveland Clinic, Cleveland
Furth, Emma E. Hospital of the University of Pennsylvania, Philadelphia
Gouw, Annette S. H. University Medical Center Groningen, Groningen
Hafezi-Bakhtiari, Sara UHN Toronto General Hospital, Toronto
Haga, Hironori Kyoto University, Kyoto
Hart, John University of Chicago Hospitals, Chicago
Honsova, Eva Institute for Clinical and Experimental Medicine, Prague
Hübscher, Stefan G. University of Birmingham, Birmingham, UK Ismail, Wesam Bani Sueif University, Beni Suef, Egypt Itoh, Tomoo Kobe University Hospital, Kobe
Jhala, Nirag C. Temple University, Philadelphia
Khettry, Urmila Lahey Hospital and Medical Center, Burlington, MA Klintmalm, Goran B. Baylor University Medical Center, Dallas
Knechtle, Stuart Duke University Health System, Durham
Koshiba, Takaaki Fukushima Medical University, Fukushima
Kozlowski, Tomasz University of North Carolina at Chapel Hill, Chapel Hill Lassman, Charles R. David Geffen School of Medicine at UCLA, Los Angeles Lerut, Jan Cliniques Universitaires Saint-Luc, Brussels
Levitsky, Josh Northwestern University Feinberg School of Medicine, Chicago
Licini, Lisa Pope John XXIII Hospital, Bergamo
Liotta, Rosa Mediterranean Institute for Transplantation and Advanced Specialized Therapies, Palermo
Mazariegos, George Children's Hospital of Pittsburgh of UPMC, Pittsburgh

McCaughan, Geoff Royal Prince Alfred Hospital, Sydney
Minervini, Marta I. University of Pittsburgh Medical Center, Pittsburgh
Misdraji, Joseph Harvard Medical School, Massachussets General Hospital, Boston
Mohanakumar, Thalachallour St. Joseph's Hospital, Norton Thoracic Institute, Phoenix
Mölne, Johan University of Gothenburg, Gothenburg, Sweden Nasser, Imad Beth Israel Deaconess Medical Center, Boston Neil, Desley University Hospital Birmingham, UK
Neuberger, James University Hospital Birmingham, UK O'Leary, Jacqueline Baylor University Medical Center, Dallas
O'Neil, Maura University of Kansas Medical Center, Kansas City
Pappo, Orit Hadassah Medical Center, Jerusalem
Petrovic, Lydia University of Southern California, Keck School of Medicine Randhawa, Parmjeet S. University of Pittsburgh Medical Center, Pittsburgh Reinholt, Finn P. University of Oslo and Oslo University Hospital, Oslo
Ruiz, Phillip University of Miami Health System, Miami, FL Sağol, Özgül Dokuz Eylul University School of Medicine, Izmir Sanchez Fueyo, Alberto King's College Hospital, London
Sasatomi, Eizaburo University of North Carolina School of Medicine
Schiano, Thomas Mount Sinai Hospital, New York
Sebagh, Mylène AP-HP Hôpital Paul-Brousse, Paris
Shaked, Abraham University of Pennsylvania Health System, Philadelphia
Shiller, Michelle Baylor University Medical Center, Dallas
Shimizu, Tomokazu Toda Chuo General Hospital, Saitama
Sis, Banu University of Alberta Hospital, Edmonton, CA Smith, Maxwell L. Mayo Clinic Health System, Scottsdale Sonzogni, Aurelio Pope John XXIII Hospital, Bergamo
Stevenson, Heather L. University of Texas Medical Branch, Galveston
Tanigawa, Ryan Y. Instituto do Câncer do Estado de São Paulo, Hospital das Clínicas, São Paulo
Thung, Swan N. Mount Sinai Health System, New York Tisone, Giuseppe University of Rome – Tor Vergata Wernerson, Annika Karolinska University Hospital
Wu, Tong Tulane University School of Medicine
Yilmaz Funda University of Ege, Izmir
Zeevi, Adriana University of Pittsburgh, Pittsburgh
Zen, Yoh Kobe University Hospital, Kobe