THE UNIVERSITY of EDINBURGH

Edinburgh Research Explorer

Equine guttural pouch empyema, why does it become chronic?

Citation for published version:
Dixon, P & James, O 2018, 'Equine guttural pouch empyema, why does it become chronic?', *Equine Veterinary Education*, vol. 30, no. 2, pp. 80-84. https://doi.org/10.1111/eve.12707

Digital Object Identifier (DOI):
10.1111/eve.12707

Link:
Link to publication record in Edinburgh Research Explorer

Document Version:
Peer reviewed version

Published In:
Equine Veterinary Education

General rights
Copyright for the publications made accessible via the Edinburgh Research Explorer is retained by the author(s) and / or other copyright owners and it is a condition of accessing these publications that users recognise and abide by the legal requirements associated with these rights.

Take down policy
The University of Edinburgh has made every reasonable effort to ensure that Edinburgh Research Explorer content complies with UK legislation. If you believe that the public display of this file breaches copyright please contact openaccess@ed.ac.uk providing details, and we will remove access to the work immediately and investigate your claim.

OPEN ACCESS

Download date: 12. Oct. 2024

Clinical commentary - Equine guttural pouch empyema, why does it become chronic?

PM Dixon and O James

Division of Veterinary Clinical Studies, Royal (Dick) School of Veterinary Studies, The University of Edinburgh and The Roslin Institute, Easter Bush Campus, Midlothian, EH25 9RG, Scotland.

Keywords: horse, guttural pouches, guttural pouch infection, chondroids, strangles infection

Guttural pouch empyema is defined as the presence of purulent exudate or chondroids within one or both pouches (Freeman and Hardy 2012). The article by DeLoache et al (2016) in the current issue of Equine Veterinary Education ***Guttural pouch empyema caused by Corynebacterium pseudotuberculosis in a pregnant mare*** highlights the need to broaden our horizons when considering the aetiology of guttural pouch disease to include empyema caused by *C. pseudotuberculosis*, the causative agent of "pigeon fever", that is a common disease in certain areas of the USA.

Aetiopathogenesis of guttural pouch empyema

The guttural pouches are lined by the common respiratory mucosa and thus are affected by all generalised viral respiratory infections. Endoscopy of horses with such viral respiratory infections frequently shows mucopurulent exudate draining bilaterally from the guttural pouches. Similar exudate is also commonly seen draining from the sino-nasal ostia ("sinus drainage angles") in such infections, because the sinuses are also lined by the common respiratory mucosa and are similarly affected by these acute infections. Most such infections are self-limiting and no treatment, other than rest, is usually required. A more chronic and purulent guttural pouch infection may occur with upper respiratory infections caused by bacteria, most commonly a primary nasopharyngeal and guttural pouch infection with *Streptococcus equi var equi* (strangles) and less commonly by other bacteria including *Streptococcus zooepidemicus* (Judy et al.. 1999), that may be primary infections or secondary to viral respiratory infections. As shown in DeLaoache et al's (2016) paper, guttural pouch infection with *C. pseudotuberculosis* also needs to be considered in some geographical areas.

With strangles infection, abscessed retropharyngeal lymph nodes on the floor of the medial guttural pouch compartment can rupture and drain into the guttural pouch lumen (Fintl and Dixon 2000) and initiate the empyema (Fig 1).

It is unclear if empyema of the guttural pouches by other types of bacteria are caused by direct pyogenic infection of the guttural pouch mucosa, or occur following rupture of abscessed retropharyngeal lymph nodes into the guttural pouch lumen. Most acute cases of guttural pouch empyema resolve spontaneously and resolution is aided by postural drainage from the pouches that occurs when the head is lowered, in conjunction with the normal opening of the ostia during swallowing. However, such postural drainage, that is encouraged by feeding at ground level, does not necessarily completely empty the guttural pouches of

exudate by gravity, because areas lateral to the guttural pouch pharyngeal ostium are ventral to its internal ostium when the head is lowered. The presence of normal guttural pouch mucociliary clearance is also required for complete drainage of exudate. Continuing mucosal inflammation with loss of cilia inhibits normal movement of exudate that has increased quantity due to the local mucosal inflammation and is also of a more viscous nature than normal guttural pouch mucus secretions due to the leucocyte breakdown products it contains. Inflammation of the guttural pouch ostia may also impede drainage at this stage.

If guttural pouch empyema does not fully drain for the above reasons, the exudate can gradually become viscous (Fig 2), and may eventually dehydrate further and form firm chondroids, that become spherical or ovoid from kneading type movements on the floor of the pouch during head movements, and eventually become solid (Fig 2). The presence of chondroids, that essentially are infected, porous foreign bodies, will cause ongoing mucosal inflammation and thus make the guttural pouch empyema permanent until they are removed. A similar situation occurs with chronic paranasal sinus empyema, if the more dependant sinuses (especially the ventral conchal and rostral maxillary sinuses) develop inspissated pus that in turn, makes the sinus empyema permanent. It is unclear if equine pus is more prone to become inspissated than exudate of other species, or whether this predisposition to inspissation is anatomical, due to species-related poor drainage of their guttural pouches and sinuses.

Other less common reasons for guttural pouch empyema to become chronic, include persistent drainage of the retropharyngeal lymph nodes that usually heal over after they rupture into the guttural pouches (Fig 3) or guttural pouch penetration from sharp ingested foreign bodies (Fig 4). Foals with guttural pouch tympany, frequently have concurrent empyema related to poor drainage and to anatomical distension of affected pouches. Guttural pouch neoplasia can affect drainage predisposing to infection (Drew et al. 2016).

Restricted guttural pouch drainage can also cause ongoing empyema for different reasons. If extreme distension of a guttural pouch with exudate occurs (Fig 5) this pouch distension can put pressure on the mucosal flap (plica salpingopharyngeus) at the inflamed pharyngeal ostium that occludes drainage. Less commonly, a permanent anatomical stenosis of the ostium can occur with or without any history of prior upper airway infection. Ostial stenosis can lead to the accumulation of viscous mucoid (indicating possible developmental origin or acquired stenosis of non-infectious cause) or more commonly purulent exudate (possibly indicating prior guttural pouch infection), usually involving one pouch. Occasionally, such guttural pouches with restricted drainage may spontaneously fistulate into the nasopharynx, but if they contain chondroids larger than the acquired ostium, they cannot drain fully (Fig 5) and the guttural pouch empyema will remain.

Confirmation of Diagnosis

Cases of guttural pouch empyema may have a history of contact with strangles-infected horses, and such cases may initially have a bilateral purulent nasal discharge, which later becomes unilateral, if empyema develops in just one guttural pouch. Initially, affected horses may have painful swelling of the submandibular and parotid area lymph nodes, abnormal head and neck carriage. Stertor and dysphagia can develop if gross distension of pouches occur due to empyema (Fig 6), or to swollen retropharyngeal lymph nodes in acute cases. Nasal culture, PCR and serological blood tests for strangles infection are often initially used

to diagnose strangles and clinicians are often reluctant to perform upper airway endoscopy at this stage, because the expense of dealing with the inevitable contamination of equipment and clothing, and knowing that most cases will resolve without such intervention. Molecular analysis (e.g. PCR) and/or bacterial culture of nasal swabs may confirm strangles, or may indicate an alternative pathogen, such as found in the accompanying case report.

In cases of more persistent nasal discharge, endoscopy of the upper airway is required, initially to assess if other causes of unilateral nasal disease are present, such as sinusitis, nasal conchal bulla infection or infection of the rostral maxillary cheek teeth with nasal drainage. Endoscopy of the guttural pouch area may show exudate draining from one or both ostia, and or compression of the nasopharyngeal roof, that often appears bilateral even in cases of unilateral guttural pouch distension (Fig 7).

Passage of the endoscope into the guttural pouch via the nasopharyngeal ostium may show purulent exudate or chondroids lying on the guttural pouch floor. Samples of exudate can be collected for culture and/or PCR analysis for evidence of strangles. Standing, lateral radiographs can also be used to assess for fluid lines or chondroids within the guttural pouches, but it is not always possible to radiographically ascertain whether unilateral or bilateral GP disease is present (Fig 6).

Treatment

Lower grade guttural pouch empyema can be treated conservatively by postural drainage, including isolation of such cases if infectious disease is suspected. Non-responding cases can have guttural pouch lavage as described by DeLoache et al (2016) and this can be performed using an indwelling commercially available guttural pouch catheter; a Foley or custom made catheter, or trans-endoscopically. Lukewarm saline is the treatment of choice; added antiseptics will cause inflammation of the guttural pouch mucosa and may hamper drainage. If persistent infection remains following saline lavage and in the absence of chondroids or draining lymph nodes, antibiotic can be infused into the guttural pouches, including gelatin-infused depot antibiotics. Excessive pressure should not be used during lavage as this can tear the guttural pouch lining and cause cellulitis of the head and neck, that may even progress down the fascial planes of the neck resulting in thoracic empyema.

As noted above, gross distension of guttural pouches by exudate can be self-perpetuating due to ostium compression and such cases may be treated by catheterisation (with difficulty) and drainage of the affected pouch(es) that in turn will allow greatly improved drainage. If stenosis of the guttural pouch ostium is present, it is not usually possible to catheterise the distended pouch and creation of a large drainage ostium by trans-endoscopic laser surgery on the thin-walled, rostro-dorsal aspect of the affected pouch is indicated. Fenestration of the cartilaginous ostium is much more difficult and may later granulate over and become occluded. Unlike in cases of guttural pouch tympany, fenestration of the guttural pouch septum via the contra-lateral guttural pouch may not be successful with guttural pouch empyema/chondroids, although success with this technique has been reported (Hawkins et al, 2001). Although earlier descriptions exist of surgical drainage of guttural pouch empyema via Viborg's triangle, this technique is difficult unless gross distension is present, and should be avoided. If small numbers of firm chondroids are present, they can be removed trans-

endoscopically (Fig 8). Larger numbers of chondroids require surgical removal. Surgery on the standing horse has many anatomical and practical advantages over surgery under general anaesthesia and also prevents contamination of the surgery theatre (Perkins et al 2006) (Fig 9).

Fig 1. Drainage of pus from a ruptured lymph node on the floor of the medial compartment into the guttural pouch lumen.

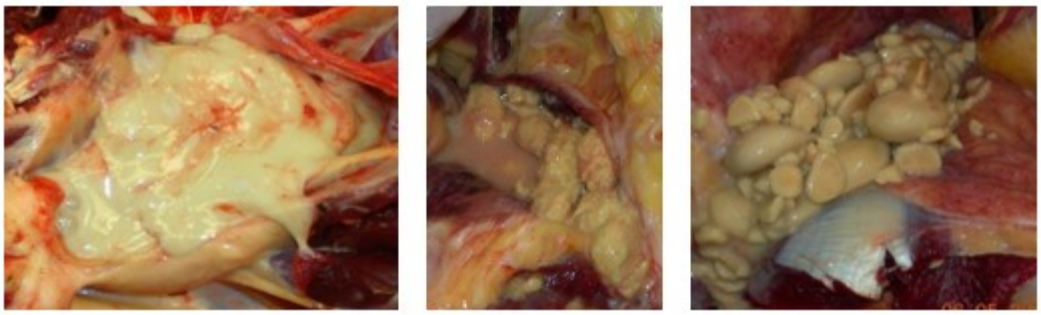

Fig 2. Post mortem images of different strangles-infected guttural pouches showing different stages in the development of chondroids. Left image: gross empyema, middle image: soft, semi-formed chondroids: right: firm, formed chondroids.

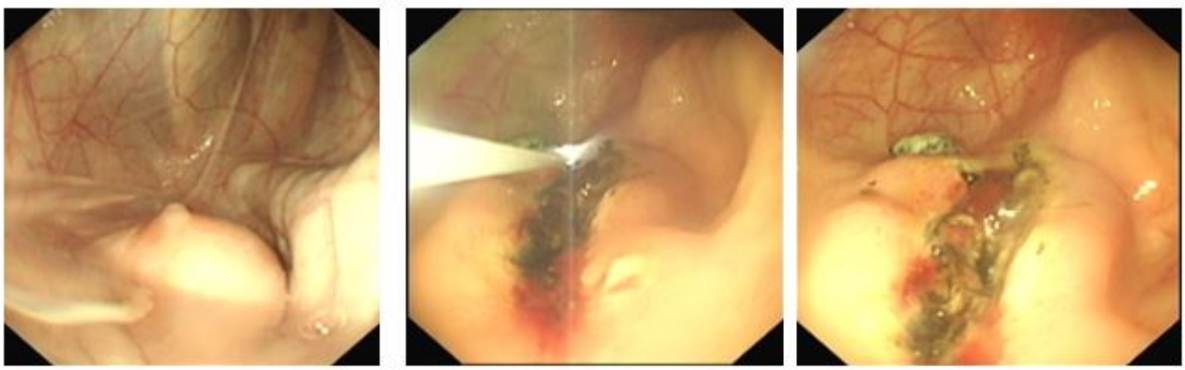

Fig 3. Left. This chronically infected lymph node on the floor of the medial guttural pouch compartment (surrounded by local anaesthetic and pus) never fully drained and was believed to be the cause of the ongoing guttural pouch infection with *S equi var equi*. Middle and right images shows its drainage by laser surgery (image courtesy of R Reardon)

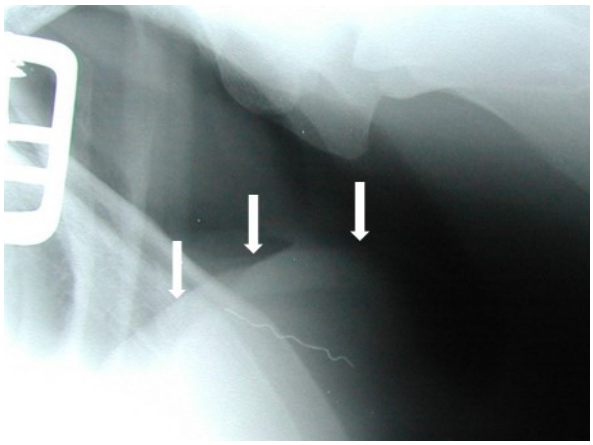

Fig 4. An ingested metallic foreign body (broken hairclip) has penetrated the guttural pouch causing chronic empyema with a large abscess on its floor (arrows).

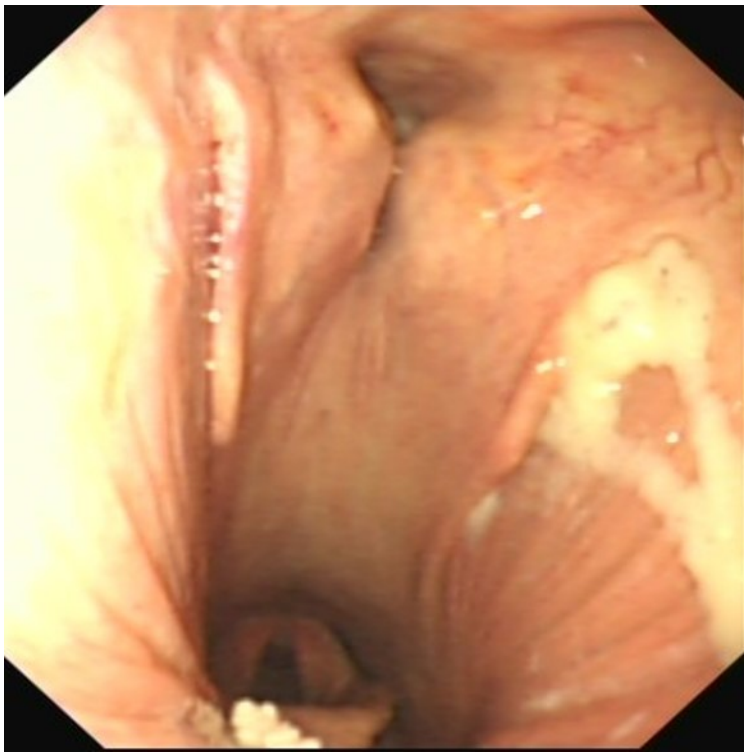

Fig 5. Endoscopic image of the roof of the nasopharynx of a horse that presented with chronic, mainly left-sided nasal discharge. This image shows the nasopharyngeal recess that contains a nasopharyngeal-guttural pouch fistula. Chondroids are visible within the left guttural pouch that cannot drain through the small fistula – ensuring persistent infection of this guttural pouch.

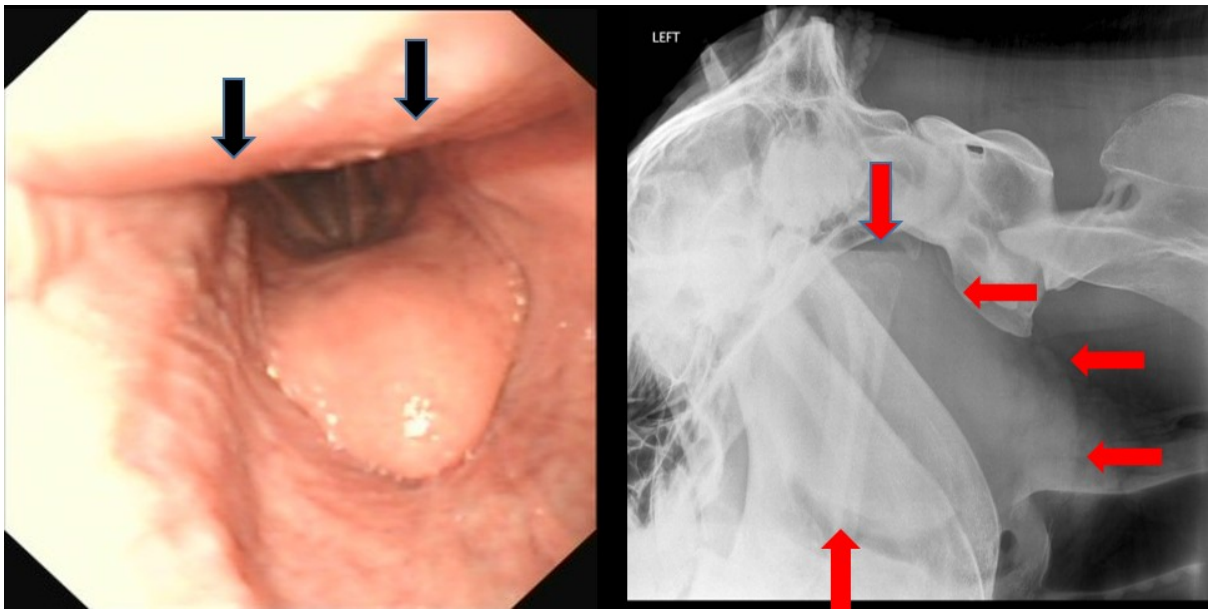

Fig 6. Marked guttural pouch empyema. Left: endoscopic view of the caudal nasopharynx and larynx showing collapse (arrows) of the nasopharyngeal roof and some laryngeal obstruction. Right: this lateral radiograph shows extreme distension of the guttural pouch (arrows) with a fluid line dorsally (single arrow, blue outline), great compression on and narrowing of the nasopharyngeal lumen ventrally (single arrow) and caudal distension of the GP towards the neck (horizontal arrows).

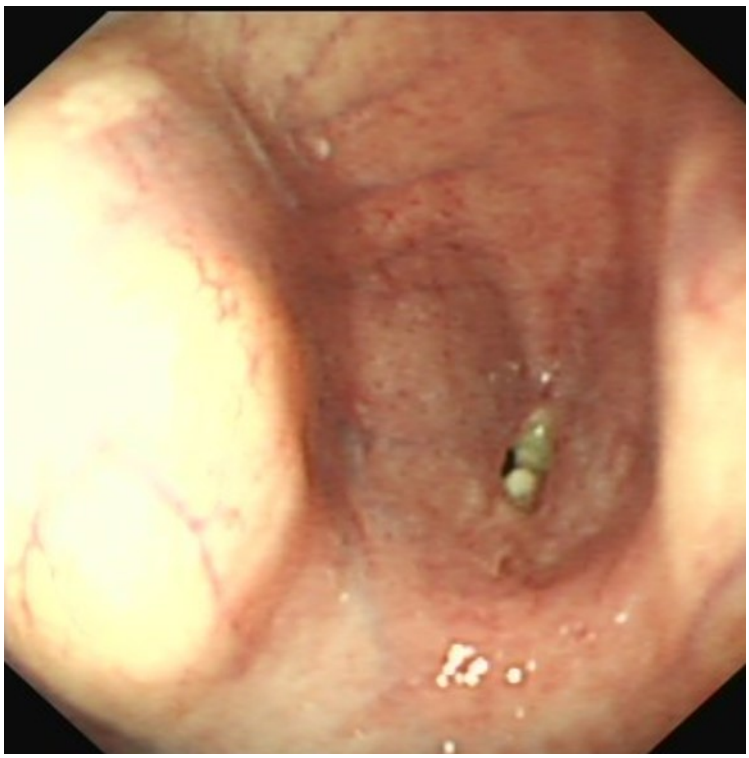

Fig 7. Endoscopic image showing purulent material draining from a distended left guttural pouch via its nasopharyngeal ostium

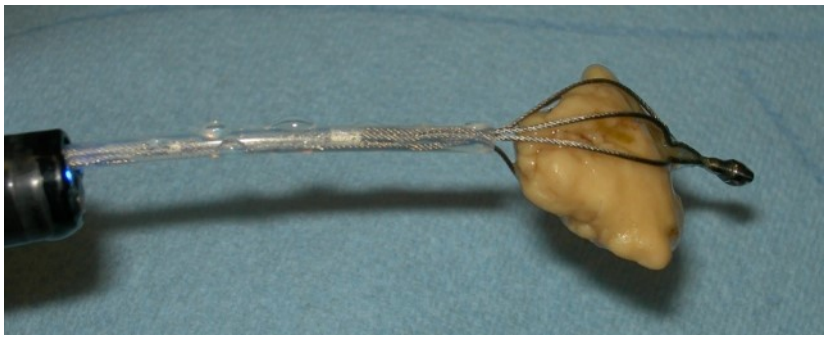

Fig 8. A chondroid removed using an endoscopically guided basket snare.

Fig 9. Left: Standing surgical removal of left-sided guttural pouch chondroids under endoscopic guidance using a modified Whitehouse approach – note left-sided nasal discharge in affected horse. Right top: A loop curette can be endoscopically seen amongst semi-solid chondroids in the affected pouch during this surgery. Right bottom: The long-handled spoon shown in the kidney dish with extracted chondroids is also useful in removing chondroids.

References

1. DeLoache, P., Whelchel, D., Beetz, R., Carter., Eichelberger, A. and Pusterla, N. (2016) Guttural pouch empyema caused by Corynebacterium pseudotuberculosis in a pregnant mare. Equine Vet. Educ. IN Press

2. Drew, S.J., Meehan, L., Rearden, R.J.M., McGorum, B.C., Dixon, P.M. and Del-Pozo, J. (2016) Guttural pouch leiomyosarcomma causing nasopharyngeal compression in a pony. Equine Vet. Educ. Doi:10.1111/eve.12607.

3. Fintl, C., Dixon, P.M., Brazil, T.J., Pirie, R.S., McGorum, B.C. (2000) Endoscopic and bacteriological findings in a chronic outbreak of strangles. Vet. Rec. **147**, 480-484.

4. Freeman, D.E. and Hardy, J. (2012) Guttural Pouch. In: Equine Surgery, 4th edn, J.A. Auer and J.A. Stick, Elsevier Saunders, St Louis Missouri. pp 627-28.

5. Hawkins, J.F., Frank, N., Sojka, J.E., Levy, M. (2001) Fistulation of the auditory tube diverticulum (guttural pouch) with a neodymium:yttriumaluminium-garnet laser for treatment of chronic empyema in two horses. J. Am. Vet. Med. Ass. **218**, 405-407

6. Judy, C.E., Chaffin, M.K., Cohen, N.D. (1999) Empyema of the guttural pouch (auditory tube diverticulum) in horses: 91 cases (1977-1997). J. Am. Vet. Med. Ass. **215**, 1666-70.

7. Perkins, J.D., Schumacher, J., Kelly, G., Gomez, J.H. and Schumacher, J. (2006) Standing surgical removal of inspissated guttural pouch exudate (Chondroids) in ten horses. Vet. Surg. **35**, 658-662