A case of variably protease-sensitive prionopathy treated with doxycyclin

Citation for published version:
Assar, H, Topakian, R, Weis, S, Rahimi, J, Trenkler, J, Höftberger, R, Aboulenein-Djamshidian, F, Ströbel, T, Budka, H, Yull, H, Head, MW, Ironside, JW & Kovacs, GG 2015, 'A case of variably protease-sensitive prionopathy treated with doxycyclin', *Journal of Neurology, Neurosurgery & Psychiatry*, vol. 86, no. 7, pp. 816-818. https://doi.org/10.1136/jnnp-2014-309871

Digital Object Identifier (DOI):
10.1136/jnnp-2014-309871

Published In:
Journal of Neurology, Neurosurgery & Psychiatry

A case of variably protease-sensitive prionopathy treated with doxycyclin

Hamid Assar MD[1], Raffi Topakian MD[2], Serge Weis MD PhD[3], Jasmin Rahimi MD[4], Johannes Trenkler MD[5], Romana Höftberger MD[4], Fahmy Aboulenein-Djamshidian MD[6], Thomas Ströbel PhD[4], Herbert Budka MD[7], Helen Yull MSc[8], Mark W. Head PhD[8], James W. Ironside FRCPath FMedSci[8], Gabor G. Kovacs MD PhD[4]

1: Neuromedizinische Ambulanzzentrum, State Neuropsychiatric Hospital Wagner-Jauregg, Linz, Medical School, Johannes Kepler University, Linz, Austria;

2: Department of Neurology, Klinikum Wels-Grieskirchen, Wels, Austria;

3: Laboratory of Neuropathology, Department of Pathology and Neuropathology, State Neuropsychiatric Hospital Wagner-Jauregg, Medical School, Johannes Kepler University Linz, Austria;

4: Institute of Neurology, Medical University of Vienna and Austrian Reference Centre for Human Prion Diseases Vienna, Austria;

5: Institute of Radiology, State Neuropsychiatric Hospital Wagner-Jauregg, Linz, Medical School, Johannes Kepler University, Linz, Austria;

6: Karl Landsteiner Institute for Neuroimmunological and Neurodegenerative Disorders, Department of Neurology, SMZ-Ost Donauspital, Vienna, Austria

7: Institute of Neuropathology, University Hospital Zürich, Zürich, Switzerland

8: National CJD Research & Surveillance Unit, University of Edinburgh, Edinburgh, United Kingdom;

Running head title: VPSPr treated with doxycyline

Word count title: 9

Word count text: 1000

Number of references: 5

Number of figures: 1

Number of supplementary Files: 1

Key words: Creutzfeldt-Jakob disease; doxycycline; prion disease; prion protein; variably protease-sensitive prionopathy;

Address correspondence to:

Gabor G. Kovacs, MD, PhD; Institute of Neurology, AKH 4J, Währinger Gürtel 18-20, A-1097 Vienna, Austria; Phone: +43-1-40400-55070; Fax +43-1-40400-55110;

Email: gabor.kovacs@meduniwien.ac.at

Variably protease-sensitive prionopathy (VPSPr) is a recently described neurodegenerative disorder characterized by the presence of spongiform encephalopathy and an unusual immunostaining and immunoblotting pattern for the disease-associated prion protein (PrP^{Sc}).[1] This links VPSPr to human prion diseases, which are uniformly fatal disorders. The clinical symptoms and the longer duration of illness make VPSPr distinct from sporadic or idiopathic Creutzfeldt-Jakob disease (sCJD).[1] Doxycycline treatment has been evaluated in patients with prion disease, however, there is little evidence that it can reverse the clinical symptoms or reduce the underlying disease progress once established.[2] We present here a patient with VPSPr who received doxycycline and survived for an extended period of time in an akinetic and mute state.

Neuropathological examination was performed using published methods and various anti-PrP antibodies.[3] Frozen tissues from selected brain regions were available for biochemical analysis. Tissues were analysed for the presence of protease resistant PrP (PrP^{res}) as previously described (see also Supplemental online material).[4]

In May 2007, a registered psychiatrist suspected an organic affective disorder in a 54-year-old Austrian woman. Two months earlier, medical work-up for presumed weight loss of 16 kilograms within the past 18 months had been unremarkable. In June 2007, she was admitted to a clinic specialized in disorders of the nervous system. Her family history was negative for neurodegenerative diseases and there was no evidence of exposure to toxins. She reported depressed mood and short-term memory problems, and difficulties with balance, walking, driving and cooking. On neuropsychological examination she was oriented to time, place, person and situation, Mini Mental State Examination (MMSE) score was 22/30, clock drawing test score was 3/9. She had word-finding difficulties, ideational apraxia, acalculia, and visuoconstructive deficits. She displayed affective incontinence with crying fits. She had gait ataxia, and extensor plantar responses were observed with increased tone in both arms and legs. Baseline magnetic resonance imaging (MRI) of the brain revealed symmetric increased signal in the basal ganglia in T2-weighted images and, less marked, cortical ribbon hyperintensity with widespread restricted diffusion in the cortex (**Figure 1 A, B**). Electroencephalography (EEG) studies showed generalized slowing only; Western blot assay for the 14-3-3 protein in the cerebrospinal fluid was weakly positive. Accordingly, this case fulfilled surveillance criteria for probable sCJD. Analysis of the *PRNP* gene excluded any mutation and revealed VV homozigosity at codon 129. Following the guidelines of an

ongoing therapeutic trial,[2] she was treated with 100 mg doxycycline per day. Until December 2008, she was examined five times (see Supplemental online material). By November 2007 she developed extrapyramidal signs and dystonic postures and frequent falls. Repeated EEG still showed generalized slowing. There was no myoclonus. From July 2008 onwards she was in a state of akinetic mutism. She was repeatedly treated with antibiotics for aspiration pneumonia and urinary tract infections. In April 2011 levetiracetame was started due to new-onset focal epilepsy. Doxycycline was stopped after four years. Diffusion restriction was less pronounced 3.5 years after baseline imaging (see Supplemental online material). CT scan showed atrophy 4.5 years after baseline MRI imaging (see Supplemental online material). The patient died in May 2013, six years after recognition of the first symptoms and after nearly five years in an akinetic mute state.

Histopathological features comprised spongiform change with intermediate sized vacuoles, mild to moderate reactive gliosis in cortical and subcortical areas (**Figure 1 C-E**) and moderate neuronal loss and presence of eosinophilic cytoplasmic Lewy bodies in the brainstem pigmented nuclei. Immunostaining for PrP showed a diffuse synaptic pattern with loose clusters of granular deposits in the cortex (**Figure 1 F, G**). In the thalamus and cerebellar cortex mostly the granular- and microplaque-like PrP immunoreactivity was seen (**Figure 1H-J**) Immunostaining for phospho-tau (AT8) revealed small neuritic profiles. Immunostaining for α-synuclein showed Lewy bodies, thin and thick neurites and dots (**Figure 1K**), corresponding to Braak stage 4 of Lewy related pathology or transitional/limbic type according to the McKeith criteria of dementia with Lewy bodies (for details on neuropathological alterations see online supplemental file).

Western blot analysis of a specimen of frontal cortex from this case showed abundant PrP prior to limited digestion with proteinase K (**Figure 1L**). Following digestion with 50μg/ml proteinase K, two faint bands were seen: one between 20kDa and 30kDa and the other in the low molecular mass region. Analysis of a greater volume of brain homogenate (with PrP^{res} collected by centrifugation) showed a single strong clear band of approximately 8kDa (**Figure 1 L, M**). This approximately 8kDa band was present in occipital cortex, basal ganglia, cerebellum in addition to frontal cortex, but was not detectable in a specimen of white matter from the cerebrum (**Figure 1 M, N**). In the cerebellum the approximately 8kDa band was accompanied by the presence of two bands with similar electrophoretic mobilities to the bottom and middle bands of the type 2A PrP^{res} profile that is found in some forms of CJD. A

very faint band at approximately 17kDa was also seen, giving the appearance of a ladder of PrP^{res} fragments (**Figure 1 M, N**).

The neuropathological and biochemical features of this case are consistent with VPSPr.[1, 4] The clinical course was biphasic; within 14 months the symptoms had progressed to akinetic mutism, following which the patient survived 5 years. Although the early psychiatric symptoms were similar to those described in VPSPr cases,[1] the clinical phenotype was compatible also with sCJD, including the striatal and cortical increased signals detected in baseline MRI, and the positive CSF 14-3-3 test,[5] which have been reported only in a single VPSPr case with VV homozigosity at codon 129.[1] While prolonged survival is not unusual in VPSPr cases,[1] in none of the reported VPSPr cases has there been such a protracted state of akinetic mutism reported. In contrast to the present case, in sCJD long-standing akinetic mutism is associated with severe pathology in the cortex and white matter, referred to as the panencephalopathic form of CJD. Although the long survival associated with less prominent histopathological alterations could suggest that doxycycline might have reduced the neurotoxic effect of disease-associated PrP, this observation merits further confirmation.

Acknowledgements

The NCJDRSU is funded by the Policy Research Programme of the Department of Health, and by the Scottish Government (DH121/5061). The views expressed in this publication are those of the authors and not necessarily those of the Department of Health. Edinburgh Brain Banks is supported by the Medical Research Council (MRC G0900580). The Austrian Reference Center for Human Diseases (OERPE) is supported by the Austrian Federal Ministry of Health (BMG). We acknowledge the helpful discussions with Dr. Ellen Gelpi, Barcelona, Spain.

Competing Interests

H.A., R.T., S.W., J.T., R.H., F.AE-D., T.S., H.B., H.Y., M.W.H., do not report any conflict of interest. J.R. and G.G.K. report grants from Austrian Federal Ministry of Health (BMG), during the conduct of the study; G.G.K. reports grants from EU FP7 Project Develage, outside the submitted work. J.W.I. reports grants from Department of Health, London, grants from Medical Research Council, personal fees and non-financial support from Piramal, personal fees from Covance, personal fees and non-financial support from Springer, outside the submitted work.

References

1. Zou WQ, Puoti G, Xiao X, et al. Variably protease-sensitive prionopathy: a new sporadic disease of the prion protein. *Ann Neurol* 2010; **68**:162-72.

2. Haik S, Marcon G, Mallet A, et al. Doxycycline in Creutzfeldt-Jakob disease: a phase 2, randomised, double-blind, placebo-controlled trial. *Lancet Neurol* 2014;**13**:150-8.

3. Kovacs GG, Peden A, Weis S, et al. Rapidly progressive dementia with thalamic degeneration and peculiar cortical prion protein immunoreactivity, but absence of proteinase K resistant PrP: a new disease entity? *Acta Neuropathol Commun* 2013;**1**:72.

4. Head MW, Yull HM, Ritchie DL, et al. Variably protease-sensitive prionopathy in the UK: a retrospective review 1991-2008. *Brain* 2013;**136**:1102-15.

5. Zerr I, Kallenberg K, Summers DM, et al. Updated clinical diagnostic criteria for sporadic Creutzfeldt-Jakob disease. *Brain* 2009;**132**:2659-68.

Figure legends

Figure 1. Cranial MRI, neuropathology and immunoblotting observations.
T2-weighted images show bilateral hyperintense signal in the basal ganglia (**A**). Diffusion weighted images show restricted diffusion in the basal ganglia as well as in widespread areas of the cortex (**B**). Haematoxylin and eosin staining reveals spongiform change in the frontal cortex (**C**), more prominent reactive astrogliosis in the caudate nucleus (**D**) and mild vacuolation in the molecular layer of the cerebellum (**E**). Granular and synaptic PrP immunoreactivity appearing in loose clusters shown here in the parietal cortex (**F** and enlarged in **G**). Granular PrP deposits in the thalamus (**H**). Prominent PrP immunoreactivity in the cerebellum (**I** and enlarged in **J**). Prominent alpha-synuclein immunoreactive Lewy related pathology in the substantia nigra (**K**). Western blot analysis (**L-N**) of frontal cortex (**L** lanes 2,4,6,8 and **M, N** lane 3) 10% w/v brain homogenate from this case, loaded as 5µl without proteinase K digestion (**L** lane 2), or as 0.5µl (**L** lane 6), 5µl (**L** lane 4), or 50µl collected by centrifugation (**L** lane 8) after proteinase K digestion. Molecular mass standards (**L** and **M, N**, lanes 1) and ~5µl of 10% w/v proteinase K digested frontal cortex from sporadic CJD MM1 subtype (**L** lanes 3 and 7, **M, N** lanes 2 and 10), sporadic CJD VV2A subtype (**L** lane 10, **M, N** lane 8) and variant CJD (**L** lane 5 and 9, **M, N** lane 9) are shown for reference. In (**M, N**) 50µl of samples of 10% w/v brain homogenates of frontal cortex (lane 3) occipital cortex (lane 4), basal ganglia (lane 5), white matter from frontal lobe (lane 6) and cerebellum (lane 7) were proteinase K digested and collected by centrifugation before Western blot analysis. Western blot is shown after short (**M**) and long (**N**) exposure times. The prion protein antibody used was 3F4. Bar in (**A**) represents 150 µm for **A-C**, and **G**; 200 µm for **D**; 500 µm for **H**; and 50 µm for **F** and **I-O**.

Figure 1

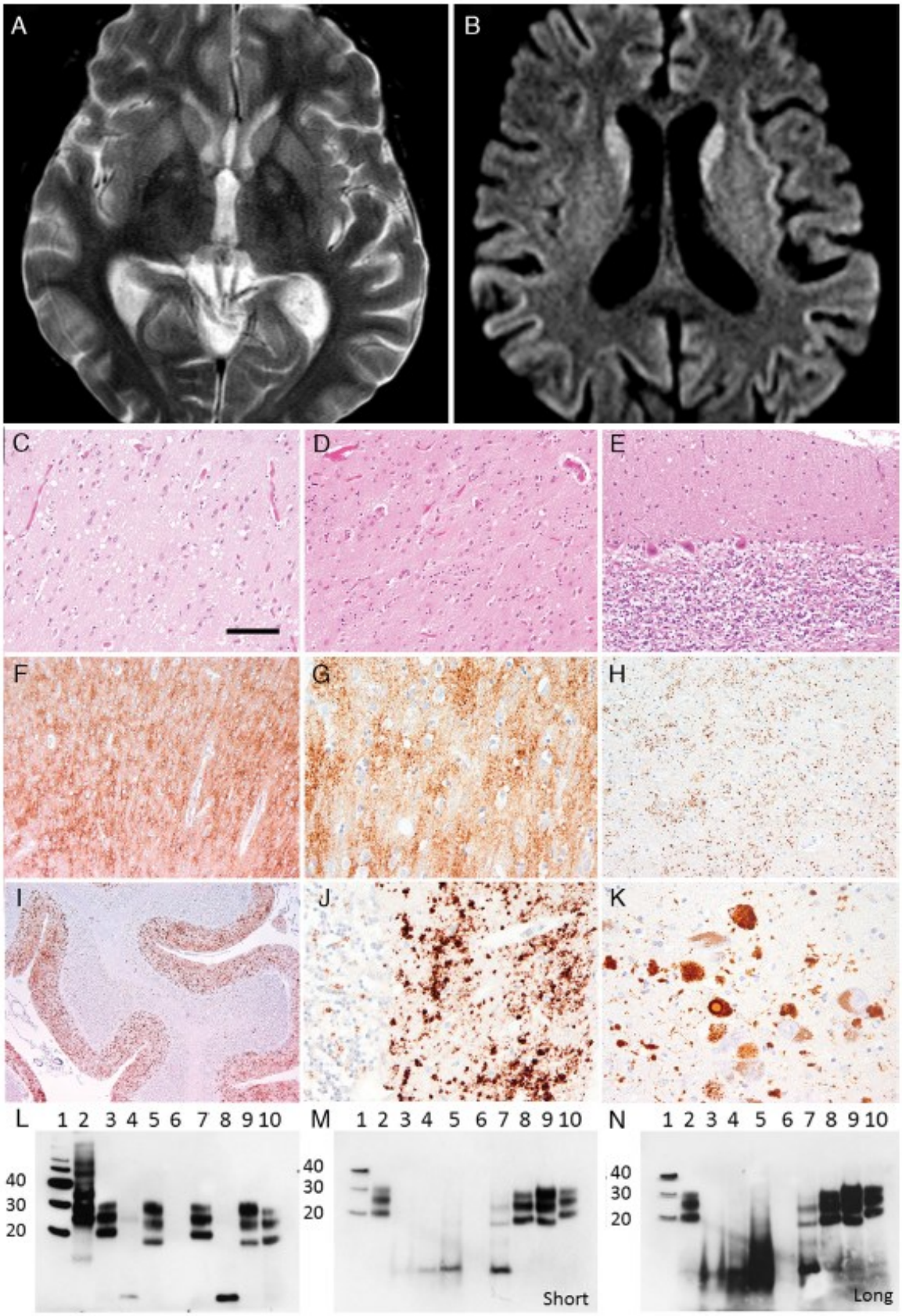
A
B
C
D
E
F
G
H
I
J
K
L
1 2 3 4 5 6 7 8 9 10
40
30
20
M
1 2 3 4 5 6 7 8 9 10
40
30
20
Short
N
1 2 3 4 5 6 7 8 9 10
40
30
20
Long

Online Supplementary File

Details on material and methods, clinical, laboratory and neuropathological observations and comments on the results.