



THE UNIVERSITY *of* EDINBURGH

Edinburgh Research Explorer

A systematic review of brain frontal lobe parcellation techniques in magnetic resonance imaging

Citation for published version:

Cox, SR, Ferguson, KJ, Royle, NA, Shenkin, SD, MacPherson, SE, Maclullich, AMJ, Deary, IJ & Wardlaw, JM 2014, 'A systematic review of brain frontal lobe parcellation techniques in magnetic resonance imaging', *Brain Structure and Function*, vol. 219, no. 1, pp. 1-22. <https://doi.org/10.1007/s00429-013-0527-5>

Digital Object Identifier (DOI):

[10.1007/s00429-013-0527-5](https://doi.org/10.1007/s00429-013-0527-5)

Link:

[Link to publication record in Edinburgh Research Explorer](#)

Document Version:

Peer reviewed version

Published In:

Brain Structure and Function

Publisher Rights Statement:

© Cox, S. R., Ferguson, K. J., Royle, N. A., Shenkin, S. D., MacPherson, S. E., Maclullich, A. M. J., Deary, I. J., & Wardlaw, J. M. (2013). A systematic review of brain frontal lobe parcellation techniques in magnetic resonance imaging. *Brain structure & function*, 219(1), 1-22. [10.1007/s00429-013-0527-5](https://doi.org/10.1007/s00429-013-0527-5).

General rights

Copyright for the publications made accessible via the Edinburgh Research Explorer is retained by the author(s) and / or other copyright owners and it is a condition of accessing these publications that users recognise and abide by the legal requirements associated with these rights.

Take down policy

The University of Edinburgh has made every reasonable effort to ensure that Edinburgh Research Explorer content complies with UK legislation. If you believe that the public display of this file breaches copyright please contact openaccess@ed.ac.uk providing details, and we will remove access to the work immediately and investigate your claim.



**A Systematic Review of Brain Frontal Lobe Parcellation Techniques in Magnetic
Resonance Imaging**

**Simon R. Cox^{1,2,3*}, Karen J. Ferguson^{2,4}, Natalie A. Royle^{1,2,5}, Susan D. Shenkin^{2,4}, Sarah E.
MacPherson^{2,3}, Alasdair M.J. MacLulich^{2,4,6}, Ian J. Deary^{2,3} and Joanna M. Wardlaw^{1,2,5}**

*¹Brain Research Imaging Centre, ²Centre for Cognitive Ageing and Cognitive Epidemiology,
³Department of Psychology, ⁴Geriatric Medicine, University of Edinburgh, UK, ⁵Scottish
Imaging Network, a Platform for Scientific Excellence (SINAPSE) Collaboration, Edinburgh,
UK, ⁶Endocrinology Unit, University of Edinburgh, UK*

** Corresponding author: Department of Psychology, 7 George Square, Edinburgh, EH8 9JZ.*

E-mail: simon.cox@ed.ac.uk, Fax: 0131 651 1771, Telephone: 0131 651 1303.

Running Head: Frontal Lobe Parcellation Review

Abstract

Manual volumetric measurement of the brain's frontal lobe and its sub-regions from Magnetic Resonance Images (MRIs) is an established method for researching neural correlates of clinical disorders or cognitive functions. However, there is no consensus between methods used to identify relevant boundaries of a given region of interest (ROI) on MRIs, and those used may bear little relation to each other or the underlying structural, functional and connective architecture. This presents challenges for the analysis and synthesis of such results. We therefore performed a systematic literature review to highlight variations in the anatomical boundaries used to measure frontal regions, contextualised by up-to-date evidence from histology, hodology and neuropsychology. We searched EMBASE and MEDLINE for studies in English reporting three-dimensional boundaries for manually delineating the brain's frontal lobe or sub-regional ROIs from MRIs. Exclusion criteria were: exclusive use of co-ordinate grid systems; insufficient detail to allow method replication; publication in grey literature only. Papers were assessed on quality criteria relating to bias, reproducibility and protocol rationale. There was a large degree of variability in the three-dimensional boundaries of all regions used by the 208 eligible papers. Half of the reports did not justify their rationale for boundary selection, and each paper met on average only three-quarters of quality criteria. For the frontal lobe and each sub-region (frontal pole, anterior cingulate, dorsolateral, inferior-lateral, and orbitofrontal) we identified reproducible methods for a biologically-plausible target ROI. It is hoped that this synthesis will guide the design of future volumetric studies of cerebral structure.

Keywords: Frontal; cortex; parcellation; segmentation; MRI; cytoarchitecture

1. Introduction

The brain's frontal lobes are both cytoarchitectonically and functionally diverse, and a large body of research examines their contributions to a range of cognitive processes and clinical conditions. Regions of the frontal lobes are differentiated by laminar organisation dependent on neuronal density, presence of granule cells, glial content, afferent and efferent connectivity (Zald, 2007). Such differences have functional implications, broadly supported by evidence from both neuropsychology and cognitive neuroscience that either discrete lesions to, or blood- oxygen level dependent response in, a specific region can be related to behavioural symptoms or hypothesised function, due to the high degree of segregation in the parallel fronto-subcortical circuits (Middleton and Strick, 2001). As a result, attempting to reveal the 'neural correlates' of a disorder by scrutinising the structure of a particular sub-region in relation to a specific symptomatology has become a widespread practice, with the aim of providing insight into the developmental aetiology or pathogenesis. Structural abnormalities of the frontal lobe (or their absence) have been reported in psychiatric, behavioural and neurological disorders and also in normal development and ageing (e.g. Convit et al. 2001; Salat et al. 2001; Yucel et al. 2008). However, the methods used to define and measure frontal regions are highly variable among publications. This variability has critical implications for the analysis, reporting and synthesis of neuroanatomical abnormalities in clinical populations, and could explain areas of inconsistency amongst findings of the reported neuroanatomical characteristics of a population (Zhou et al. 2005). A full review of such inconsistencies is beyond the scope of this review¹.

1.1 Tools for brain measurement

Methods to measure brain structure fall into two categories: manual and automated. Manual delineation of ROIs affords precise control over boundary placement on a slice-by-slice basis for the MR image of each participant. Although this confers a high degree of reliability and allows adherence to individual differences in brain morphology, it requires expertise in neuroanatomy and involves significant time investment. Automated methods can require less user input thereby reducing personnel time-cost, making these methods potentially more feasible for studying large cohorts. It also avoids the potential for bias and reproducibility issues introduced by manual rater drift. However, choices throughout the processing chain may introduce other forms of systematic and non-systematic bias; even automated parcellation methods require user-driven input in the first instance. That is, the software for automated segmentation of a target samples must be based on a particular structural schema or atlas. As there is no standardised protocol to manually identify the ROIs in the first place, the parcellations derived from automated atlas-based methods can only be as good as the manually-delineated approach on which they are based. For example, the Desikan-Killiany atlas for Freesurfer (Desikan et al. 2006), the Harvard Brain Atlas (Kikinis et al. 1996) and anatomical labels for SPM (Tzourio-Mazoyer et al. 2002) are derived from the manual schema outlined by Rademacher et al. (1992), and subsequent modifications by Caviness et al. (1996) and Tzourio et al. (1997). The frontal lobe divisions for each of these are included in this review. In addition, different methods of spatial registration (which attempt to account for individual differences in brain morphology and size) can yield markedly different outcomes. Thus, choices of atlas selection and registration method significantly influence automated parcellation results (Bohland et al. 2009; Pantazis et al. 2010), and also offer no direct control over the positioning of ROI

boundaries for each individual. Consequently, although the remainder of this article is concerned with the methods used in manual parcellation of the frontal lobes, the findings extend to automated methods predicated on a manually-derived atlas.

1.2 Approximating cellular field locations

In manual parcellation, the approximation of cellular field locations on the cortex using only neuroanatomical cues from an MR image gives rise to a complex set of issues which are likely to be the main source of variability between methods for frontal lobe parcellation. There is little doubt that distinct sub-regions of the frontal lobes can be defined histologically by distinct patterns of cell distribution over the cortex, as evidenced by the general accord between many influential brain cartographers over the last century. When examining the frontal lobes, Brodmann (1909), Campbell (1905), Smith (1907), von Economo and Koskinas (1925), Sarkisov (1949) and Petrides and Pandya (1994) amongst others, each identify an anterior tip, a region anterior to the central sulcus, and intermediate regions on the lateral and ventral convexity of the frontal cortex based on patterns of cell distribution. However, more detailed comparison of these maps reveals subtle differences in the way in which sub-regions relate to cortical topography, making it difficult to derive a clear and robust set of rules to apply to the topography of the MR image to be parcellated. Discrepancies between cytoarchitectural maps are partly due to different concepts of cortical organisation and different histology methods (Zilles and Amunts, 2010), but it also reflects the high level of individual differences in frontal lobe morphology, both at the micro and macro scale. Small sample sizes are typical in studies of cortical cellular fields, such that a single study (and resultant map) is unlikely to have captured much of the possible variation in morphology. As a result, differences between study samples can also partially account for

differences between these maps. It is understandable, then, that this margin for interpretation has resulted in a variety of approaches for frontal lobe parcellation.

More recent studies of neuroarchitecture have gone some way to addressing the issue of individual variability in selected ROIs. These studies are relevant for two reasons. Firstly, they address one of the basic assumptions of manual parcellation; that the relationship between underlying cell structure and gross morphology is more or less stable across individuals. Secondly, they enable a more robust method for identification of ROIs by using sulcal and gyral landmarks. The importance of the first point cannot be overstated, as without a generally stable relationship between macro- and micro-anatomical variation, cortical parcellation would be futile. Examinations of cortical fields such as Brodmann Areas (BAs) 17, 41, 3b, 4 (Rademacher et al. 1993), 4, 6, 17, 18, (Fischl et al. 2008), the functional activation of the Frontal Eye Fields and sensory-motor regions (Frost and Goebel, 2012) have all been shown to hold a strikingly consistent position with specific gyri across a modest number of individual brains. Although other regions such as the fusiform face area, Broca's area (Frost and Goebel, 2012), orbitofrontal regions (Ongür et al. 2003), BAs 9 and 46 (Rajkowska and Goldman-Rakic, 1995) and BAs 44 and 45 (Fischl et al. 2008) show some inter-individual variability of position on the folds of the cortex, general observations about their likely location across individuals are still sufficiently robust to allow a meaningful measure to be derived from the sulcal and gyral pattern evident on an MR scan (Fischl et al. 2008)². This suggests that not only can one be relatively confident about the relationship between topography and underlying structure, but that parcellation approaches should be sympathetic to the individual variability in gyrification rather than using

gross geometric boundaries derived from unrelated landmarks or coordinate systems (Devlin and Poldrack, 2007; Uylings et al. 2005).

Even with this proviso, variations in parcellation approach can be attributed to different configurations of the same gyri. Moreover, some regions are difficult to identify because no study has yet identified a sulcus that reliability indicates a sub-field boundary, so the boundary is sometimes determined using other easily-identifiable extrinsic landmarks that vary between methods.

1.3 Aims of the review

The implications of the contradictory definitions of ROIs within studies of the frontal lobes are far-reaching. These underplayed methodological discrepancies confound assessment of the relationship between brain region and function or clinical symptom. Establishing an overview of putative neural correlates of a given disorder or function is fundamentally undermined by using standard nomenclature (e.g. “dorsolateral” or “orbitofrontal”) to label non-standardised brain measures. The current review aims to determine the range of frontal lobe sub-regional definitions that have been adopted, compare these with known relationships between architecture and morphology and comment on factors of study quality. This synthesis of studies investigating structure, function and connectivity offers useful guidance in relating underlying cellular fields to topographical position for the most part, and also highlights gaps in our understanding for some ROIs in particular. Compromises between accuracy (does it make good biological sense?) and reproducibility (is it objective, feasible and applicable to all brains?) drive the commentary and identification of areas for future research.

2. Methods

2.1 Study Identification

We undertook a systematic literature review of published articles reporting a manual tracing method of the human frontal lobe, following PRISMA guidelines (Liberati et al. 2009). Searching abstracts and article titles using MESH headings eliminated a number of relevant articles identified in a preliminary scoping of the literature. Consequently, a full-text search in both Medline and EMBASE was conducted (covering articles from 1946 to present) on 22nd September 2011 using the following search string: (*structural OR structure OR volume OR volumetric*) AND (*parcellate OR parcellated OR parcellation OR measure OR measurement OR estimate OR estimation*) AND (*frontal OR prefrontal*). The references of all screened articles were searched for further relevant papers.

2.2 Screening and Eligibility

All studies reporting a method for manual tracing the human frontal lobe or its sub-regions from landmarks on magnetic resonance images were included. Further inclusion criteria were: studies which reported three-dimensional boundaries for manually delineating the frontal lobe or sub-regional ROIs from MR images; and English language. Exclusion criteria were: exclusive use of co-ordinate grid systems (Uylings et al. 2005); insufficient detail to allow reproduction of the majority of reported ROIs; and publication in grey literature only (as defined by the Grey Literature International Steering Committee; www.glisc.com). This latter criterion was selected because grey literature would be unlikely to contain the amount of detail required to describe a complete segmentation protocol. Information was reviewed from both publication and

supplementary material where available. Where a protocol was unpublished, the authors were contacted in the first instance, and the study excluded if there was no reply.

c2.3 Data Extraction and Synthesis

The following information was collected: boundary limits for ROI in frontal lobes, study population, sample size, age range, MR sequence used, magnet strength, slice thickness, image pre-processing steps, and inter- and intra-rater correlation coefficients.

2.4 Study Quality

To quantify the steps taken by each paper to avoid bias and to justify and validate their protocols, the QUADAS quality assessment tool (Whiting et al. 2003) was adapted for the current review. The following criteria were used to rate reviewed publications: (1) Sufficient detail provided to reproduce the protocol. (2) Justification for selection of anatomical landmarks and sub-regional boundaries as evidence that the relationship between topography and neuroarchitecture had been considered. (3) The reporting of intra-class correlation coefficients (ICCs) was considered the minimum method for checking the reproducibility of the protocol in question. Ideally, both inter- and intra-rater metric, and measures of spatial concordance, should be reported. (4) Blinding to participant status where possible. (5) Robust rules accounting for topographical variation. Applicable for regions known to vary significantly between individuals (e.g. cingulate and orbital regions – discussed in 3.4.3 and 3.4.6). (6) Summary statistics of volumes reported. (7) Demographics of the participant groups, including age, gender, number and clinical characteristics reported. Both of these final points are useful in identifying systematic biological variance both within and between participant groups, and whether or not

the protocol may be appropriately applied to another population. Duplicate scoring was conducted independently by two raters (SRC & NAR) for a subset of papers (90) describing the posterior frontal lobe boundary only, and points of disagreement were discussed and resolved. For each publication, a score of 0 or 1 was given for each of the eligible criteria, and the total was converted to a percentage as an indicator of quality.

3. Results

3.1 Study Selection

A total of 1740 records were initially identified, and reduced to 1544 once duplicates were removed. Of these, 1312 reports did not meet the inclusion criteria mainly due to using automated structural methods, functional MR techniques, or animals. Papers that repeated the same method for the same participants were excluded. Studies applying the same protocol to different cohorts were not excluded as they contribute unique information concerning validity and reproducibility in a range of clinical populations or age groups. Further, their inclusion gives an undiluted picture of general publication quality for the entire spectrum of clinical topics studied using manual parcellation. The remaining 232 were potentially eligible for inclusion into the review. Twenty-four of these were excluded due to: lack of boundary information (n=13), regions not intended to be exclusively frontal (n=5), grey literature (n=1), and re-reporting previous results (n=5). This left 208 reviewed publications (Figure 1).

- Insert Figure 1 around here -

3.2 Study Characteristics

The 208 reviewed papers include 11071 participants, with a mean of 29 per participant group (median = 22, range = 1-200). The main topics of interest were schizophrenia (25%), affective disorders (unipolar, bipolar, major and minor depressive disorders 13%), dementia (7%), and healthy adults of various ages (26%). Study dates span 1988-2011, and MRI scanners range from 0.1T to 3T in magnet strength.

3.3 Study Quality

On average, papers satisfied about three-quarters of the quality criteria (median score = 71.43%, range = 16.67-100%); 50% of papers did not attempt to justify their boundary selections either explicitly or by citation. Reporting methods for controlling rater bias were also low, with 25% not reporting reliability measures, and 33% not reporting blindness to participant status. Amongst those papers that relied on topography to carry out the protocol, 31% failed to give explicit instructions on how to deal with known topographical variants, although only 4% did not provide sufficient detail for all necessary boundaries. Twenty-one percent did not report the raw volumes from their method, and almost 6% did not report the demographics of their participants.

3.4 Synthesis of Results

Two differences in the general type of approach to frontal lobe parcellation were noted. Firstly, geometrical cut-planes were used in most methods, combined with sulcal and gyral cues, or to demarcate large areas of lobe. The application of straight boundaries across the cortex clearly has advantages. As observed by Lacerda et al. (2003), this method is faster to execute and is more robust to rater subjectivity and difficulties caused by the highly variable sulcal patterning between brains that can lead researchers to exclude brains from analysis (e.g. Szeszko et al. 1999a, b). Nevertheless, this approach is unlikely to offer sufficient sensitivity to capture subtle sub-regional differences, and is not sympathetic to brain topography. Given the known relationship between cortical folding and underlying cytoarchitecture, landmarks that have been used to derive a limit geometrically are usually distant from the ROI (for example, using a coronal plane at the optic chiasm as the posterior extent of frontal cortex). Such landmarks are less likely to account for inter-individual variations in both brain size and shape, or the different

effects of age and disease on the brain, potentially introducing error into the resultant measurements. Thus, using gyrification as a cue to underlying cellular composition (where possible) is a way in which such ambiguities can be controlled.

Secondly, the way in which white matter has been assigned to lobar sub-regions was found to vary amongst protocols. Of those articles reviewed, two approaches established a central point in each hemisphere and used radiating lines to the cortex to designate each segment of white matter to its corresponding cortical area (Convit et al. 2001; Sanfilipo et al. 2000). Other approaches quantified the cortex and sub-regional shallow white matter by drawing lines between key sulci (van Elst et al. 2003; MacLulich et al. 2006; Sanches et al. 2009; Schenker et al. 2005; Semendeferi et al. 1997) or separating CSF, grey and white matter.

A common misconception is that difficulties in reconciling anatomical findings across publications are due to differences in nomenclature (as observed by Bohland et al. 2009), rather than underlying differences in the method of ROI measurement. However, the reviewed papers used fairly consistent names to identify broadly similar ROIs. Each frontal sub-region will be discussed in turn under commonly used nomenclature, starting with the posterior frontal lobe boundary, then the frontal pole, anterior cingulate, dorsolateral, inferior-lateral and orbital. Each region below contains a brief introduction, results and short discussion. Finally, the most plausible boundaries based on the discussed evidence will be summarised for each frontal sub-region. For ease of reference throughout, only the papers from which a given protocol originated will be cited in the proceeding text, although full details of all the reviewed papers are available as supplementary material (Online Resources 1 & 2), and online at www.bric.ed.ac.uk/research/imageanalysis.html.

3.4.1 Posterior Frontal Boundary

Introduction. At its posterior-lateral edge, the frontal lobe is situated anterior to the central sulcus. Also known as the central fissure of Rolando, this deep sulcus runs from the medial wall, over the lateral convexity until its ventrolateral termination at the sylvian fissure, separating the frontal lobe from parietal tissue. The precentral sulcus (PrCS) contains the primary motor cortex (BA4), with supplementary motor areas (SMA; BA6) immediately anterior to the PrCS (Duvernoy, 1999). The differentiation between frontal and prefrontal lobe is traditionally made on the lateral surface, with the latter excluding both motor and supplementary motor regions (Semendeferi et al. 2001). The frontal lobe is ventrolaterally separated from the temporal lobe by the sylvian fissure, and on the ventral aspect is divided from the insular cortex by the circular sulcus of the insula.

Results. Amongst the reviewed publications, there were a number of variations in the use of lateral, medial and ventral aspects of the posterior frontal lobe boundary. We identified 19 different methods, using 15 different landmarks, for establishing the posterior frontal boundary (Figure 2), which has clear implications for between-study comparison. The central sulcus was commonly adopted as the overall posterior boundary for the lateral surface, but the central sulcus is more difficult to determine this boundary on the medial surface. The use of two coronal cut planes, one above the body of the corpus callosum where the central sulcus traverses the midsagittal line and one below the genu that intersects the anterior point of the inner surface of the genu, were applied in studies after Crespo-Facorro et al. (1999). The absence of a clear topographical landmark makes identifying the anterior limit of the supplementary motor area (and therefore the posterior extent of the prefrontal region) problematic. This has led to common

use of the precentral sulcus (PrCS) as the most posterior boundary for defining the prefrontal (as opposed to frontal) lobe. Thirty-one papers reported that their measures began anterior to the PrCS. Although use of either central or pre-central sulcus was common, it can be challenging to determine their course when visualising the brain in 2D slices, as reported by several authors (Coffey et al. 1991, Lyoo et al. 1998 and Pantel et al. 1997). Common strategies to overcome this were the use of simultaneous tracing in multiple slice orientations or software that allows ‘painting’ onto 3D renderings to be visualised as a guide during tracing onto standard 2D slices were used.

- Insert Figure 2 around here -

Given the difficulty in accurately identifying caudal aspects of the frontal lobe where such methods are unavailable, imposing a coronal cut-plane as the posterior boundary was also found to be a common method. The slice just anterior to, or in which the genu of the corpus callosum appeared was cited by 45 papers as the frontal lobe posterior boundary. Pantel et al. (1997) used the splenium of the corpus callosum but only in the superior slices where it appeared; above the mamillary bodies, a horizontal line from the lateral sulcus (Sylvian fissure) to the midline was used. Other studies used a coronal plane at the midpoint of the corpus callosum (Jernigan et al. 1991), or a coronal plane a set distance anterior to the most anterior coronal extent of the white matter connecting frontal and temporal lobes, known as the temporal stem (after Wible et al. 1995). Coronal cut planes have also been employed at the anterior commissure (Bjork et al. 2009; Bremner et al. 2000; Filipek et al. 1997; Nifosi et al. 2010), anterior extent of the lateral ventricles (Coffey et al. 1998), bilateral appearance of the insula

(Bäckman et al. 1997; Ginovart et al. 1997), the optic chiasm (Coffey et al. 1991; Lyoo et al. 1998), the mamillary bodies and splenium in inferior slices (Cowell et al. 1994), or 6mm posterior to the septum pellucidum (Noga et al. 1995). Several papers (Convit et al. 2001; Gold et al. 2005) attempt to distinguish the supplementary motor area from the prefrontal lobe by identifying the coronal plane that equally divides the distance between the anterior extent of the cingulate sulcus and the precentral sulcus.

Although the majority of cut-plane methods use the selection of distant, sub-cortical landmarks to position cut-planes for the posterior frontal boundaries, explicit attempts to combine cortical topography and cut-planes have also been applied. Kates et al. (2002) selected a coronal slice at the appearance of the precentral gyrus, which aimed to exclude the supplementary motor area between this plane and the precentral gyrus, based on relevant cortical folding and presumed underlying cytoarchitecture.

A number of cut planes have also been used to limit the most posterior extent of the ventral frontal lobe. The substantia perforata is a landmark used for many of the papers after Rademacher et al. (1992) to define the posterior boundary of the orbital regions, although Szeszko et al (1999a, b) report difficulties in identifying this. They suggest instead using the most posterior coronal slice in which the olfactory sulcus maintains its characteristic shape, although this, too, may be subject to interpretation. However, the majority of studies that utilise the central or precentral sulcus to guide frontal lobe segmentation stated the use of the circular sulcus of the insula as the ventral boundary, following traditional anatomical and functional convention. The medial boundary was not discussed in the majority of cases, possibly due to the difficulty in following sulcal/gyral patterns on the medial surface (Coffey et al., 1991). As already mentioned, Crespo-Facorro et al (1999) used two cut planes to determine this boundary.

Bartzokis et al., (1993) suggested that as the Sylvian fissure is followed to the circular sulcus, the insula is excluded from the frontal lobe measurement. A straight line is drawn from the fundus of the most superior portion of the insula to the superior and lateral most point of the lateral ventricle.

Discussion. Delineation of conventional anatomical sulci results in general lobar delineation where practicable. Whilst the method by Kates et al. (2002) may be a promising approach to exclude BA8 because it avoids the difficulty in following the central or PrCS in two dimensions and takes account of local cortical topography to some degree, further work would establish whether the area of frontal lobe excluded is equivalent in each individual. Though the extent of variation in the angle of the precentral gyrus as it ascends from the dorsal aspect of the brain is relatively small (SD of 6°; Reignes et al., 2000), the volumetric and cytoarchitectural nature of the excluded region are unknown. Likewise, the consistency with which more distant landmarks such as the anterior commissure, mammillary bodies or lateral ventricles relate to the cortex is untested, and thus does not provide a solid basis on which to parcellate the lobe. The lateral ventricles vary greatly in size within a healthy population (Blatter et al. 1995), as well as in pathological and ageing populations, and would be a significant determinant of the resultant volumes if using these boundaries.

3.4.2 Frontal Pole

Introduction. Designated as area 10 by Brodmann, the anterior tip of the frontal lobe, known as the frontal pole (FP) has been identified as a cellularly-distinct sub-region by a large number of brain cartographers (Brodmann, 1909; Campbell, 1905; von Economo and Koskinas, 1925; Hof et al. 1995; Ongur et al. 2003; Petrides and Pandya, 1994; Sarkisov, 1949;

Semendeferi et al. 2001; Smith, 1907; Uylings et al. 2010). In addition to its structural distinctiveness, it is phylogenetically the most recent addition to the cerebrum (Semendeferi et al. 2001), is subject to an unusually long period of development and maturation (Burgess et al. 2006; Dumontheil et al. 2008) and thought to make functional contributions to higher cognitive processes such as analogical reasoning and self-referential thought (Benoit et al. 2010; Volle et al. 2010), and general intelligence (Gläscher et al. 2010; Jung and Haier, 2007). FP activity has been reported during a wide variety of stimulus- and task-related processes, when the mind wanders and when engaged in a demanding cognitive task (Dumontheil et al. 2010). It has been proposed that the FP acts as a ‘gateway’ through which the balance between stimulus-oriented and stimulus-independent thought is controlled (Burgess et al. 2006; Gilbert et al. 2006).

The frontal pole is a clearly distinct sub-region, and like the posterior frontal lobe boundary, volumes of some or all FL regions are dependent upon the FP boundary. If this region is ignored, the resultant measures (of the frontal gyri for example) potentially include excess noise resulting from distributing the anterior portion of the frontal lobes between multiple regions. A further complication of ignoring this region then arises, as the anterior-most portions of the frontal gyri in the coronal plane become more difficult to differentiate in 2D, making continuing sub-regional parcellation challenging and potentially unreliable.

Results. The results of the systematic review revealed that, of the 71 papers reporting sub-regional volumes extending to the anterior-most portion of the frontal lobe, 47 (66%) did not include a measure of the FP. Amongst the remaining 24 studies (34%) that did, we identified 14 distinct posterior boundaries. As displayed in Figure 2, this variability can have a striking effect on the reported size of the frontal pole.

Analysis of the variety of approaches shows that a commonly adopted method to deal with the lack of a clear landmark was to orient all brains to a standard alignment, and then use a single cut-plane in the coronal orientation to signify the FP boundary, based on a consistent and readily-identifiable feature. It is the selection of the feature itself that differs between studies. Several used a coronal plane positioned a fixed distance from a particular boundary (Planes B – Wible et al. 1997; D – Sanfilipo et al. 2000, Tisserand et al. 2002; and I – Gilbert et al. 2001). Others used a coronal plane at the anterior extent of the temporal lobes (Plane H – Rankin et al. 2004, Rosen et al. 2002), the termination of the anterior horizontal ramus of the Sylvian fissure (Plane G – Sanches et al. 2009), the anterior-most extent of the ACC (Plane F – Convit et al. 2001), or the anterior termination of the olfactory sulcus (ATOS; Plane A – John et al. 2006, McLaughlin et al. 2009; Nakamura et al. 2008). Finally, Iordanova and colleagues (2006) used the fronto-marginal sulcus (FMS) to define the posterior fronto-polar limit, including the transverse fronto-polar gyri into measure of the superior and middle frontal measures.

Discussion. Whilst imposing a plane at a fixed distance from a landmark affords a high degree of reproducibility, imposing a rigid dimension (e.g. x most anterior slices) on each individual's frontal pole fails to take into account individual differences in global and local brain size and morphology. A similar issue can be said to apply to methods that use distant, unrelated landmarks such as the anterior extent of the temporal lobes (Rankin et al. 2004, Rosen et al. 2002). The use of the termination of the anterior horizontal ramus of the Sylvian fissure to identify the lateral FP boundary (Sanches et al. 2009), or the FMS for the dorsal limit (Iordanova et al. 2006) are preferable in terms of proximity; however, it has not been made clear how these sulci relate to underlying structure. Although a reliable cortical landmark (Ono et al. 1990), the FMS as a dorsal FP boundary does not correspond readily with numerous maps of

cytoarchitecture on the medial wall and may well exclude dorsal fronto-polar areas. Moreover, this landmark was used to limit the tracing of the lateral frontal gyri by Iordanova and colleagues (2006) and so no ventral boundary was proposed.

Use of the anterior-most extent of the ACC (Convit et al. 2001) or paracingulate gyrus where present, seems to concur more readily with reported cytoarchitecture, in that no reports have yet suggested that the frontopolar cortex encroaches on the cingulate or paracingulate gyrus (e.g. Petrides & Pandya, 1994; Ongur et al., 2003 area 10p). This structure presents a proximal, clear and logical boundary for the most anterior medial point that we can be fairly certain does not represent BA10, though how much more anteriorly this cellular field actually lies in different people, or how it relates to the fronto-lateral gyri is unclear.

Finally, the ATOS appears to correspond to the posterior FP boundaries on schematics reported by Brodmann (1909), Sarkisov (1949), von Economo and Koskinas (1925), Ongur et al. (2003), Semendeferi et al. (2001) and Hof et al. (1995). Furthermore, it is the least variable (Chiavaras et al. 2001; Uylings et al. 2010) and earliest of the orbitofrontal sulci to appear during development (Chi et al. 1977) suggesting it may be a common feature between individuals. In spite of the weight of this supportive evidence cited by John et al. (2007), they are cautious to observe that whilst FP volumes using this approach show relatively little variance and correspond with a previous post-mortem measure of BA10 (Semendeferi et al. 2001), this cannot be taken as the 'true' limit of FP, and the ATOS may not necessarily be appropriate in other populations. Uylings et al (2010) observed that using this boundary did not contain all of area 10, and we found that using the ATOS as a boundary in AC-PC aligned MRIs of 88 healthy 72 year old males yielded far greater variability than for any other region (SRC – unpublished data). Whether this finding is reflective of the small sample used by John et al. (20 young healthy

volunteers), positional changes in the ATOS through generalised atrophy, a possible compromise may be to use a coronal plane that bisects the distance between the ATOS and the anterior tip of the cingulate sulcus, which appears to exclude the majority of area 10 in a small sample (Uylings et al., 2010). However, work in a larger sample could usefully compare the degree of BA10 inclusion/exclusion between methods that incorporate this highly variable landmark (ATOS) with those that use the most anterior extent of the cingulate/paracingulate gyrus. Just as with the posterior boundary of the frontal ROIs, establishing the optimum FP boundary is of key importance given the sizeable volumetric impact that a shift in the frontal pole boundary has on the numerous other frontal ROIs with which this boundary is shared, thus further work is needed to relate individual differences in morphology to underlying neuroarchitecture in a large and varied sample of individuals before the accuracy of FP measurement from MRIs can be improved.

3.4.3 Anterior Cingulate Cortex

Introduction. The anterior cingulate cortex (ACC) is the rostral portion of the cingulate gyrus running immediately dorsal to the corpus callosum, wrapping around its most anterior extent (genu) on the medial wall of the frontal lobes. This region is generally considered to comprise BAs 24 (from callosal to cingulate sulcus) and 32 (between cingulate and paracingulate sulci; Vogt 2008). Convergent evidence suggests that the ACC can be divided into at least two distinct segments with differing connectivity (Beckmann et al. 2009), receptor distribution (Palomero-Gallagher et al. 2009) and function (for a functional meta-analysis see Bush et al. 2000). The dorsal region is involved in goal-based action selection through its strong connections to lateral frontal and pre-motor regions, while the ventral region contributes to emotional

processing and is preferentially connected to the ventral and medial frontal areas (Mansouri et al. 2009). This has made the ventral ACC a particular ROI for research into various affective disorders.

Results. We found 14 reports that incorporated the cingulate gyrus into a more general sub-regional measure (Beyer et al. 2009; Bjork et al. 2009; Carper and Courchesne, 2005; Gur et al. 2000; Medina et al. 2008; Ratnanather et al. 2001; Sanfilipo et al. 2000; Semendeferi et al. 1997, Wilde et al. 2005). Amongst the remaining 59 papers measuring the cingulate, there were 26 distinct methods for delineating the ACC and its subregions, using a total of 19 different boundaries, calculated from 12 landmarks. Two main points of variability between authors were: 1) the way in which a second cingulate or paracingulate gyrus (PCG) was considered; and 2) the selection of anterior and posterior limits. These are discussed below:

Firstly, the cingulate area is a site of considerable inter-person morphological variation, and authors have taken account of this in a variety of ways. A PCG is present in 30-60% of cases and there tends to be a greater likelihood of a PCG in the left hemisphere (Fornito, 2004; Ono et al. 1990; Yucel et al. 2001). Given that, where present, the PCG shares a boundary with the cingulate gyrus, it also tends to result in a 39% decrease in cingulate volume compared to individuals without a paracingulate sulcus when controlling for head size (Fornito et al. 2006). Its presence (and the rater's ability to detect it) is also likely to impact the medial superior frontal gyrus volume as well as that of the frontal pole (particularly where the measure is taken as the anterior-most extent of the cingulate formation). Interest in the PCG is relatively recent and the functional implications of its presence are not well understood, it has been reported to associate with executive functioning (Fornito et al. 2004). Evidence suggests that the connectivity between

other regions and the cingulate is comparable, irrespective of the presence or absence of a PCG (Beckmann et al. 2009; Devinsky et al. 1995).

Out of a total of 56 reviewed publications reporting cingulate boundaries, 13 do not mention the PCG (Ballmaier et al. 2004; van Elst et al. 2003; Flashman et al. 2001; Raz et al. 1995; Salat et al. 2001; Sowell et al. 2002; Woodward et al. 2006). Three treated the PCG as part of the cingulate region (Convit et al. 2001; Ranta et al. 2009; Wible et al. 1995), 10 included it as part of the superior frontal gyrus on the medial aspect (Bremner et al. 1998; John et al. 2006; Lindberg et al. 2009; MacLulich et al. 2006; Suzuki et al. 2005; Szeszko et al. 1999a, b; Yamasue et al. 2004), though 27 treat it as a separate entity altogether (Bremner et al. 2002; Crespo-Facorro et al. 1999; Fornito et al. 2006; McCormick et al. 2006; Monkul et al. 2007; Noga et al. 1995; Paus et al. 1996; Rademacher et al. 1992; Riffkin et al. 2005; Takahashi et al. 2002).

Secondly, both the sub-genua and posterior limit of the ACC vary between studies. Although cytoarchitectonic explorations of the region consistently discriminate between the anterior and posterior cingulate cortices, the boundary separating the two regions cannot be readily identified from clear proximal landmarks in an MR image, resulting in an array of approaches (summarised in Figure 3). Whilst some simply do not divide the cingulate gyrus into two at all (Convit et al. 2001; Sowell et al. 2002; Tzourio et al. 1997), the most commonly adopted landmarks for the ACC's posterior extent use sub-cortical markers such as the anterior commissure (Bremner et al. 2002; Fornito et al. 2006; Kaur et al. 2005; Nifosi et al. 2010; Paus et al. 1996; Takahashi et al. 2002; Tisserand et al. 2002; Yucel et al. 2008) which is thought to exclude the SMA (Jones et al., 2006), the most anterior or dorsal extents of the corpus callosum (Bremner et al. 1998; Haznedaar et al. 1997; Ranta et al. 2009; Raz et al. 1995; Salat et al. 2001),

the septum pellucidum (Noga et al. 1995) and mammillary bodies (Yamasue et al., 2004), whilst others have selected more proximal cortical features such as where the ascending ramus of the Sylvian fissure joins the cingulate sulcus (McCormick et al. 2006) or the dorsal termination of the precentral sulcus on the medial wall (Rademacher et al. 1992). Though there are several informative studies on cingulate cytoarchitecture and receptor distribution (Vogt and others, 1995, 2008; Palomero-Gallagher et al., 2009), there is little specific guidance on how posterior cytoarchitectural ACC limit covaries with local cortical landmarks across individuals.

Nevertheless, data from a probabilistic connectivity analysis appear to show that the cingulate area ventral to the central and precentral sulci on the medial wall contains connections to motor and premotor areas, whereas immediately more anterior cingulate regions connect to premotor and dorsal prefrontal cortex (Beckmann et al. 2009). This converges well with evidence from classical structural maps, suggesting that the spatial relationship between the central/precentral sulci may give a more accurate index of the posterior ACC boundary than more distant landmarks.

- Insert Figure 5 around here -

The anteroventral extent of the cingulate gyrus also affects the consistency of reported cingulate volumes between studies. Figure 3 shows that several groups have elected to trace the cingulate to its natural gyral extent; others use the appearance of the internal capsule or septum pellucidum. The use of the genu of the corpus callosum is widespread for limiting the cingulate

gyrus or for excluding sub-genua cingulate regions altogether, though very few papers give an explicit justification for adopting this boundary.

Convergent evidence from cytoarchitecture and tractography (discussed above) suggests that the anterior cingulate may be divided into sub-regions, but the number and position of these is not clear. For example, Ongur et al. (2003) suggests that the sub-genua extent of the paracingulate stops near the superior rostral sulcus (similar to Smith, 1907 and Sarkisov, 1949), whilst the ventral cingulate gyrus only becomes divided in very posterior sections. This latter observation is consistent with Brodmann (1909), von Economo and Koskinas (1925), and Petrides and Pandya (1994) although they each depict sub-genua continuity of the paracingulate with von Economo and Koskinas identifying sub-regions for the paracingulate only. In contrast, Vogt et al. (1995, 2008) and Smith (1907) depict multiple cingulate regions on both ventral and dorsal aspects with a continuous paracingulate, which relates closely to recent connectivity analysis (Beckmann et al. 2009; Johansen-Berg et al. 2008), and broadly with previous reviews of neuropsychology data (Bush et al. 2000; Devinsky et al. 1995).

Amongst the various methods for cingulate parcellation identified in the review, several attempted to mirror the rostral 'cognitive' and ventral 'affective' cingulate divisions. Nineteen reported boundaries were derived from the corpus callosum (Asami et al. 2008; Botteron et al. 2002; Brambilla et al. 2002; Coryell et al. 2005; Crespo-Facorro et al. 1999; Drevets et al. 1997; Fornito, 2006; Hastings et al. 2004; Hirayasu et al. 1999; Kegeles et al. 2003; Lindberg et al. 2009; McCormick et al. 2006; Nifosi et al. 2010; Rauch et al. 2003; Takahashi et al. 2003), and one used the anterior extent of the internal capsule (Bremner et al. 2002). Further differentiation between smaller sub-regions used a coronal plane extended both above and below the genu

(Fornito et al. 2006; Takahashi et al. 2003), or the anterior extent of the internal capsule can be seen (Coryell et al. 2005; Drevets et al. 1997; Nifosì et al. 2010).

Discussion. The correspondence between multiple studies of the architecture, function and connectivity not only gives some indication of appropriate anterior and posterior boundaries, but shows that there is a reasonably stable relationship between distinct connectivity profiles and their location on the gyral surface across individuals. It is currently still unclear to what extent the geometrical partitioning of these sub-regions in manual tracing can take account of true individual variability in these boundaries and to what extent it is simply arbitrary. It is worth bearing in mind that although landmarks such as the corpus callosum and internal capsule appear to provide a convenient way of partitioning the ACC, the resultant volumes (and their reported correlations with symptoms) could represent differences in morphology of these extrinsic landmarks rather than the ACC itself. Particularly where small ROIs are concerned, even small fluctuations in boundary selection could result in a large percentage difference in the brain matter being measured.

3.4.4 Dorsolateral Frontal Cortex

Introduction. Commonly referred to as the dorsolateral prefrontal cortex (DLPFC), BA 9 and 46 exhibit some variation in cortical positioning between individuals, based on the detailed examination of brains post-mortem (Rajkowska and Goldman-Rakic, 1995). Nevertheless, BA46 lies predominantly on the middle frontal gyrus (MFG), whereas BA9 lies mainly on the superior frontal gyrus (SFG; Figure 4). Evidence from functional imaging and lesion studies link this area with working memory (Petrides, 2000), attentional control, switching (Cabeza and Nyberg,

2000; Shallice et al. 2008), planning (Unterrainer and Owen, 2006) and fluid intelligence (Deary et al. 2010; Jung and Haier, 2007).

Results. Dorsal and ventral borders of the DLPFC on the lateral wall vary between protocols. Whilst the superior and inferior frontal sulci were used consistently as boundary guides, combinations of two or even all three frontal gyri were used. We identified 55 papers reporting methods for measuring the lateral convexity of the frontal lobe. Of these, 7 explicitly combined SFG and MFG (Croxson et al. 2005; Gansler et al. 2009; McLaughlin et al. 2009; Rosso et al. 2010; Sanches et al. 2009; Seidman et al. 2006; Tisserand et al. 2002), and 22 measured the superior and middle frontal gyri separately (based on methods proposed by Crespo- Faccorro et al. 1999; Flashman et al. 2001; Iordanova et al. 2006; John et al. 2006; Rademacher et al. 1992; Ranta et al. 2009; Suzuki et al. 2005; van Petten et al. 2004; Wible et al. 1997; Zuffante et al. 2001).

In contrast, 6 papers separated the SFG and combined IFG and MFG, contrary to Rajkowska and Goldman-Rakic (Baaré et al. 1999; Bjork et al. 2009; Gilbert, 2001; Prasad et al. 2005; Seidman et al. 1994, Wilde et al. 2005). Twenty publications combined all three frontal gyri (Carper and Courchesne, 2005; van Elst et al. 2003; Head et al. 2002; Raz et al. 1995; Salat et al. 2001) or used geometrically derived boundaries without accounting for individual variation in topography (Harris et al. 1994; Hill et al. 2003; Medina et al. 2008; Nagel et al. 2006; Ranta et al. 2009; Schlaepfer et al. 1994). It must be noted that Ranta et al. used cut planes following the trajectory of the superior and inferior frontal sulci, but this is not fully sympathetic to individual differences in the course of the frontal sulci.

Another significant variation is the differentiation of lateral and medial portions of the SFG. Methods explicitly dividing lateral and medial SFG identify relevant matter up to the

lateral extent of the lateral ventricles from the midline (Bjork et al. 2009), lateral extent of grey matter at the lateral orbital sulcus (Gur et al. 2000), or a straight line into the grey matter at the superior margin of the inter-hemispheric fissure (Carper and Courchesne, 2005; Semendeferi et al. 1997; Suzuki et al. 2005; Tzourio et al. 1997). One alternative method used the longitudinal fissure for anterior slices and the deepest part of the MFG more posteriorly (McLaughlin et al. 2009).

- Insert Figure 4 around here -

Discussion. There is some variation in the use of frontal gyri to delineate the DLPFC, although the extant data suggests combining superior and middle frontal gyri to the exclusion of the inferior frontal gyrus most plausibly reflects BAs 9 and 46 (Rajkowska & Goldman-Rakic, 1995). The division between superior and medial SFG may be important in task switching behaviours, where superior medial areas are explicitly implicated in activating novel, non-learned response operations (for a review, see Shallice et al. 2008). Nevertheless, it is unclear which regions of superior medial frontal cortex are involved due to the lack of spatial resolution afforded by lesion studies and possible issues with registration of functional neuroimaging in this region. The method for defining medial and lateral SFG volumes is fairly reproducible, although more work is needed to establish a clear cytoarchitectural and functional basis for this approach.

3.4.5 Inferior Lateral Frontal Cortex

Introduction. The inferior frontal gyrus extends ventrally from the inferior frontal sulcus and comprises the pars opercularis and triangularis (BA44 and BA45, also known as Broca's Area), and the pars orbitalis (BA47; Keller et al., 2009; Petrides et al 2012). Posteriorly, it is

bound by the precentral gyrus, and anteriorly by the frontal pole. In Brodmann's original designation, area 47 referred to a large cellular field extending dorsally from the pars triangularis to the medial orbital sulcus. However, more recent investigations suggest that this region can be divided by the lateral orbital sulcus (LOS) in order to achieve better concordance with Walker's (1940) map of the macaque frontal lobe which serves not only to preserve the correspondence to primate models from which a great deal of functional detail has been learned, but also preserves the lateral portions of the orbital frontal cortex which have been reported to exhibit distinct functions (see next section; Mackey and Petrides, 2009; Petrides and Pandya, 1994). Other cytoarchitectural studies do not agree on the number of lateral orbital subregions or their relation to orbital morphology (Ongur et al. 2003; Uylings et al. 2010). In terms of functional contribution, the left IFG has been consistently associated with word comprehension and production (for reviews, see Costafreda et al. 2006; Bookheimer 2002), whilst the right IFG has been implicated in response inhibition (for a review, see Aron et al. 2004). The IFG is thought to be a core substrate of the mirror neuron system and the pathophysiology of disturbed action imitation and social reciprocity in autism spectrum disorders (Yamasaki et al. 2010). The IFG has also been implicated in thought disorder (reviewed in Nishitani et al. 2005) which has made this region of interest in schizophrenia research (e.g. Suga et al. 2010; Suzuki et al. 2005; Yamasue et al. 2004).

Results. All 28 papers reporting IFG measures used the inferior frontal sulcus as a guide for the superior boundary (and their anterior and posterior boundary selections are discussed in 3.4.1 and 3.4.2), but there was some disagreement regarding the ventrolateral limit. Seventeen publications used the anterior horizontal ramus of the Sylvian fissure to differentiate orbital regions from the IFG (Convit et al. 2001; Bremner et al. 1998; Knaus et al. 2006; Rademacher et

al. 1992; Suga et al. 2010; Tisserand et al. 2002; Yamasaki et al. 2010) or as a landmark for an axial cut-plane (Baaré et al. 1999). As a result, the pars orbitalis was excluded from the IFG in these cases, whereas in other studies, it was included when the lateral orbital sulcus was used as the ventral boundary (Crespo-Faccorro 1999; John et al. 2006; Iordanova et al. 2006; Suzuki et al. 2005) or middle orbital sulcus (Salat et al. 2001) though in one case it was not clear how the pars orbitalis and OFC were divided (Tzourio et al. 1997).

A small group of papers also examined sub-regions of the IFG in isolation. There is some evidence to suggest that in this region too, researchers have been able to identify the functional differentiations that underlying differences in architecture suggest. Based on a meta-analysis of functional studies reporting activity during verbal fluency tasks, a significant difference in the reported loci of activation was found between phonologic and semantic verbal fluency tasks, with the former activating dorsal regions on the left IFG, and the latter activating ventral regions (Costafreda et al., 2006), while the orbitalis is thought to facilitate semantic retrieval (Sabb et al. 2007). This supports the possibility of functionally meaningful parcellation of the IFG. There is consensus amongst parcellation methods that this can be done by using the horizontal and vertical rami of the Sylvian fissure. Yet here too, morphology patterns are highly variable between individuals. Amongst 50 individuals, Keller et al. (2007) documented great variation in the morphology of the inferior frontal and diagonal sulci (both the horizontal ramus of the Sylvian fissure and a diagonal sulcus within the pars opercularis) and document instances in which these sulci are discontinuous or entirely absent. Likewise, Amunts et al. (1999) demonstrated that macroscopic features could not reliably differentiate areas 44 and 45. In contrast, Tomaiuolo et al. (1999) examined the variability of the pars opercularis in 54 brains and reported a large degree of variability, but that the vertical ramus of the Sylvian fissure was a

consistent and reproducible landmark in 106 of the 108 sampled hemispheres. Another study reported that the distinct cytoarchitecture of the triangularis and orbitalis regions can be consistently distinguished near the anterior horizontal ramus of the Sylvian fissure, based on a combination of MRI and histological methods in a total of 27 brains (Uylings et al. 2010).

Discussion. The variance in ventral IFG boundaries reflects confusion concerning cellular architecture of the pars orbitalis and its inconsistent reclassification in recent studies of cytoarchitecture (e.g. Petrides et al., 2012; Ongur et al., 2003; Uylings et al. 2010). It also reflects the wide array of topographical variations exhibited by the orbital surface of the frontal lobes (Chiavaras and Petrides, 2000; Lacerda et al. 2003). Consequently, the ventral limit of the IFG is a compromise between approximating the presumed distribution of cellular fields and ensuring consistent identification of the boundary on MR scans.

Further parcellation of the IFG into subregions shows some consensus amongst reviewed methods. However, the difficulty in accurately identifying the anterior horizontal ramus has been highlighted both in histological and volumetric studies. Ono et al. (1990) observed that this sulcus was not present in some of the brains they examined. Difficulty in identifying this landmark during parcellation (Foundas et al. 2001) has led to excluding participants apparently without a horizontal ramus (Szeszko et al. 1999a, b; Rupp et al. 2005). Furthermore, Fischl et al. (2008) and Amunts et al. (1999) demonstrated that BAs 44 and 45 have more inter-individual variability in gyral configuration than non-frontal regions; suggesting that correspondence between architecture and cortical location may also vary considerably.

Taken together, this evidence highlights the potential of measuring the IFG and its subregions. The traditional anatomical definition of the IFG (lying between the IFS and LOS; Keller et al., 2009; Petrides et al., 2012) can be reliably applied, and may then further be divided at the

horizontal ramus of the Sylvian fissure (given the difficulty of reproducibly placing a boundary into the midpoint of this fissure on the lateral orbital gyrus as suggested by Uylings et al., 2010). However, the significant and unreliable covariance of cortical folding and underlying cytoarchitecture for areas 44 and 45 suggest that further parcellation may be problematic.

3.4.6 Orbitofrontal Cortex

Introduction. The orbitofrontal cortex (OFC) is found on the ventral aspect of the frontal lobes immediately superior to the orbital part of the frontal bones, anterior to the insula cortex, and extending dorso-medially to the sub-genua cingulate sulcus (Petrides & Pandya, 1994; Chiavaras et al., 2001). Although originally designated as comprising BAs 11, 12 and 47 by Brodmann (1909), some authors use areas 13 and 14 to describe more posterior OFC areas, although these were originally positioned in the insular cortex by Brodmann himself (see Uylings et al., 2005). Animal models, human imaging and lesion studies suggest this region combines the processing of taste and smell with representations of emotional valence and expected reward value of stimuli (Hof et al. 1995). Through its dense interconnectivity with other frontal and non-frontal regions, it influences decision-making from situations involving basic sensory reward to complex social and emotional interactions by processing the emotional salience of potential actions (Rolls and Grabenhorst, 2008; Torralva et al. 2007). As a consequence, this region has been of particular interest in psychiatric disorders where affect is low or flattened (such as depression), schizophrenia in which olfactory insensitivity has also been observed (Moberg et al. 1997; Rupp et al. 2005), obsessive compulsive disorder and affective disorders, in which OFC abnormalities have been reported (Blumberg et al. 1999; Cotter et al. 2005; Rajkowska et al. 2005). However, reports of OFC volume from MRI in these

disorders have been inconsistent in schizophrenia (as discussed in Nakamura et al. 2008) and bipolar disorder (see Najt et al. 2007), as are the selections of anatomical limits we have identified in this review.

Results. Amongst these methods, two points of contention were noted from our search³. Firstly, the medial extent of the orbital region varied significantly (Figure 5). The OFC extended onto the medial wall in 37 protocols using the superior rostral, cingulate or supraorbital sulcus as the dorsal boundary (Baaré et al. 1999; Berryhill et al. 1995; Convit et al. 2001; Crespo-Faccorro et al. 1999; Crosson et al. 2005; Flashman et al. 2001; Rademacher et al. 1992; Szeszko et al. 1999a, b; Rankin et al. 2004; Ranta et al. 2009; Rosen et al. 2002; Salat et al. 2001; Tisserand et al. 2002; Suzuki et al. 2005; Uylings et al. 2010; Wible et al. 1997). Other researchers imposed a limit on the medial wall at the depth of the olfactory sulcus (OS), although we found 7 different methods amongst 15 papers for identifying this. Three papers used the shortest straight line to the midline from the deepest point of the OS in coronal slices (Ballmaier et al. 2004). The dorsal disappearance of the olfactory sulcus was also used, defined as either most superior axial slice in which >50% of the OS can still be seen (Bremner et al. 1998), where combined grey matter and CSF comprise less than three-quarters of the overall length of the OFC (Lai et al. 2000), or where grey matter ran its entire length (Wilde et al. 2005). Other geometric approaches applied an axial cut-plane at the most anterior extent of the genu of the corpus callosum (Medina et al. 2008) or the anterior commissure (Bjork et al. 2009; Gur et al. 2000). One further approach used the anterior cingulate sulcus until it intersected a geometrically-determined cut-plane more anteriorly. The plane begins at the genu of the corpus callosum. Its angle is determined coronally, as a line drawn from the intersection of horizontal and vertical lines at the lateral and ventral extents of the hemisphere to a point at the most ventral extent of the corpus callosum

(Lacerda et al. 2003). Conversely, some studies excluded the medial wall by using the central fissure via a limit through the crown of the gyrus rectus (Semendeferi et al. 1997), or olfactory sulcus (Raz et al. 1995) as the medial boundary.

- Insert Figure 5 around here -

The second subject of variability between methods is in the further parcellation of the OFC. As discussed in depth by Uylings et al. (2010), the nomenclature, methods and criteria for architectural analysis of orbitofrontal composition are inconsistent for orbital sub-regions. There is consensus on a lateral/medial differentiation amongst cellular maps, and also partial support for an anterior-posterior boundary (e.g. Brodmann, 1909; Beck, 1949; Hof et al., 1995; Petrides & Pandya, 1994; Ongur et al., 2003; Sarkissov et al., 1955; von Economo & Koskinas, 1925). These two directional trends also have support from functional studies, whereby lateral and medial OFC are involved in punishment and reward evaluation respectively, and the anterior-posterior divide corresponds to a spectrum of complexity from abstract to simple reinforcers (Kringelbach and Rolls, 2004 as cited in Uylings et al. 2010). Nevertheless, the ease with which subregions can be identified is dependent upon how consistent the main orbital landmarks are among brains. Unfortunately the cortical features on the orbital surface are subject to marked inter-individual variability (Chiavaras and Petrides, 2000; Nakamura et al. 2008; Uylings et al. 2010).

Amongst the reviewed parcellation methods, we found that further parcellation of the ventral surface was achieved by dividing the straight gyrus from the orbital gyri either by using

the olfactory sulcus (Ballmaier et al. 2004; Bremner et al. 1998; Crespo-Faccorro et al. 1999; Flashman et al. 2001; Nakamura et al. 2008; Rademacher et al. 1992; Szeszko et al. 1999a, b; Suzuki et al. 2005) or the crown of the gyrus rectus itself (Tisserand et al. 2002; Uylings et al. 2010). On the medial wall, two approaches further divide the gyrus rectus and medial OFC using a line bisecting the depth of the olfactory sulcus (Crespo-Faccorro et al. 1999) or the inferior rostral sulcus (Suzuki et al. 2005). Several studies of neuroarchitecture justify dividing the ventral surface of the OFC using the middle and lateral orbital sulci (Croxson et al. 2005; Uylings et al. 2010).

Discussion. As discussed in the previous section, contention over the status of the *pars orbitalis* is central to inconsistency in the lateral OFC boundary. Variability in the medial extent of the OFC is also apparent, although exclusion of the inferior rostral gyrus from orbital measures was not generally accompanied by a cytoarchitectural justification. Further parcellation of the orbital gyri may also be possible, but the variability of these gyri makes such detailed parcellation a technically demanding feat, particularly without the detailed knowledge and experience required to make sense of the variable orbital topography. Nevertheless, the extant data suggests that medial and lateral OFC can be differentiated by using the crown of the gyrus rectus, and that anterior/posterior border can be approximated by extrapolating the path of the transverse orbital sulcus; though there is no clear sulcal boundary and a wide anterior/posterior transition zone (Uylings et al., 2010).

4. Discussion

This review has identified a large body of literature whose methods aim to quantify the volumes of the frontal lobe and its sub-regions from MR images. Against a backdrop of research linking cortical positioning with frontal cytoarchitecture, connectivity and function, we have described the marked variability with which different research groups have defined and reported each ROI. Such discrepancies may not be immediately apparent, but may underlie fundamental inconsistencies between reports of the neural correlates of various conditions. The variety of methods discussed range from those using geometry to divide the lobes into gross measures, to fine-grained parcellation of a single sub-region using available gyral cues, with the majority of methods using a combination of the two. For each of the frontal ROIs, we have identified an assortment of boundaries and attempted to illustrate the large degree to which a named single anatomical region can vary.

Nevertheless, it would be premature to conclude that detailed volumetric analysis of the frontal lobes is intractably complex at the sub-regional level. There is sufficient evidence to assume that some local gyral landmarks are common to all individuals. Further, these are most likely to allow a biologically meaningful measure sympathetic to presumed individual differences in neuroarchitecture. Likewise, analyses of variability in cortical folding and its implications have also been published. Observations on identification, measurement and potential effects on adjacent structures can offer useful guidance for protocol design. Crucially, for each region we identify some pre-existing boundaries that allow a reproducible method for a biologically-plausible target ROI based on the information discussed. It is hoped that the synthesis of these in our review, in addition to comments on the need for measures to address

questions of bias and quality, will guide design decisions in future volumetric studies of frontal lobe and other regions.

Given the difficulties in identifying papers by their methodology rather than subject of interest (exemplified by the large proportion of papers identified from manual reference searching, Figure 1), it is possible that not all relevant publications were identified in our search, thereby under-representing the true variability of methods. In addition, the current review cannot be considered a definitive guide to frontal lobe parcellation, as it refers mainly to manual methods. The use of automated approaches is widespread, and although some of the reviewed protocols are directly implemented by Freesurfer and SPM, we do not discuss non-atlas-based approaches to frontal lobe parcellation, nor their comparative merits and drawbacks.

For some regions – notably the frontal pole and anterior cingulate – further work is needed to help identify cellular field boundaries from structural landmarks. Such work may come in the form of traditional histology – such as the direct comparison of OFC cytoarchitecture and MRI parcellation undertaken by Uylings et al. (2010) - or elsewhere. For example, a technique by which myelination patterns can be objectively assessed *in vivo* across most of the cortex holds promise (Glasser and Van Essen, 2011). By generating a contrast between T1 and T2 weighted MR images, myelin maps were shown to enable the delineation of numerous cortical sub-regions which corresponded well with probabilistic cytoarchitectonic areas mapped onto the same surface. Exploitation of the microstructural qualities of the cortex can also be further enhanced by high-field imaging; the use of 7T magnetic fields and more sensitive receiver coils enables extremely detailed visualisation of intracortical myeloarchitecture. This technique accurately resolves the border between somatosensory and primary motor cortex when compared to a post-mortem analysis of the same tissue (Geyer et al. 2011). Such an approach could not only allow

further investigations into 'problem' areas such as the frontal pole and posterior border of the ACC, but also has potential for the guidance of manual or semi-automated parcellation in the future, whereby intensity signal changes can be mapped as sub-field boundaries across the cortex to complement the use of cortical morphology when identifying ROIs. Finally, the use of resting state fMRI may also offer insights for structural brain parcellation. Combining this imaging modality with unsupervised clustering techniques, recent studies have reported parcellations of both lateral PFC (Goulas et al., 2012) and OFC (Kahnt et al., 2012) which successfully identify neuroanatomically realistic sub-regions.

In the meantime however, topographical boundaries that appear to fit most plausibly with current knowledge of frontal lobe sub-fields are as follows (Figure 6). The posterior boundary of the frontal lobe, excluding the motor cortex can be traced on the lateral surface anterior to the precentral sulcus and extended medially to the cingulate or paracingulate sulcus, and ventrally at the insular sulcus in order to differentiate OFC from insula. The presence of a 3D surface view of the studied brain, in combination with 3 orthogonal plane viewing is of considerable benefit to the rater (e.g. Gronenschild et al., 2010). In situations where one might wish to exclude pre-motor areas, or where 3D visualisation software is unavailable, use of a coronal cut plane at the most anterior extent of the precentral gyrus might be used for lateral aspects, and a coronal plane where the OFC and insula cannot be distinguished for ventral aspects of the frontal lobe. For the frontal pole, the use of a coronal cut plane at the most anterior extent of the ACC appears plausible. Between these two points, the lateral convexity can be parcellated into the three main frontal gyri, (affording the option to combine SFG and MFG into DLPFC), using the lateral orbital sulcus to differentiate OFC and IFG. Medial and lateral portions of OFC and SFG can be separated using the crown of the most medial gyrus. The anterior cingulate can be measured

from its most ventral sub-genua extent to its posterior dorsal border in line with dorso-medial and lateral limits. Distinction between dACC and vACC can be made using a sagittal or coronal cut plane at the genu of the corpus callosum, although further work is clearly needed to establish relationships between topography and architecture for both posterior- and mid-cingulate boundaries, and authors may wish to pay closer attention to certain regions using finer-grained parcellations, expanding upon this general schema.

The reviewed studies have made crucial contributions to the development of frontal lobe parcellation, but it is hoped that this review will contribute to a consensus which might eliminate persisting differences in methods and reduce noise in the field to maximise future progress.

5. Acknowledgements

We are grateful to Sheila Fisker for her consultation on search strategy development (Liaison Librarian for Edinburgh University Medical School), and to David A. Dickie for the use of his brain MRI for figures. We are also grateful to the reviewers for their detailed and constructive suggestions for improving the manuscript. The work was undertaken by the University of Edinburgh in the Brain Research Imaging Centre (www.bric.ed.ac.uk – part of the SINAPSE collaboration) and the Centre for Cognitive Ageing and Cognitive Epidemiology (www.ccace.ed.ac.uk - part of the cross council Lifelong Health and Wellbeing Initiative, G0700704/84698). Funding from the Biotechnology and Biological Sciences Research Council, Engineering and Physical Sciences Research Council, Economic and Social Research Council, Medical Research Council, and from the Scottish Funding Council through the SINAPSE collaboration (<http://www.sinapse.ac.uk>) is gratefully acknowledged.

6. Conflict of Interest

The authors declare that they have no conflict of interest.

Figures

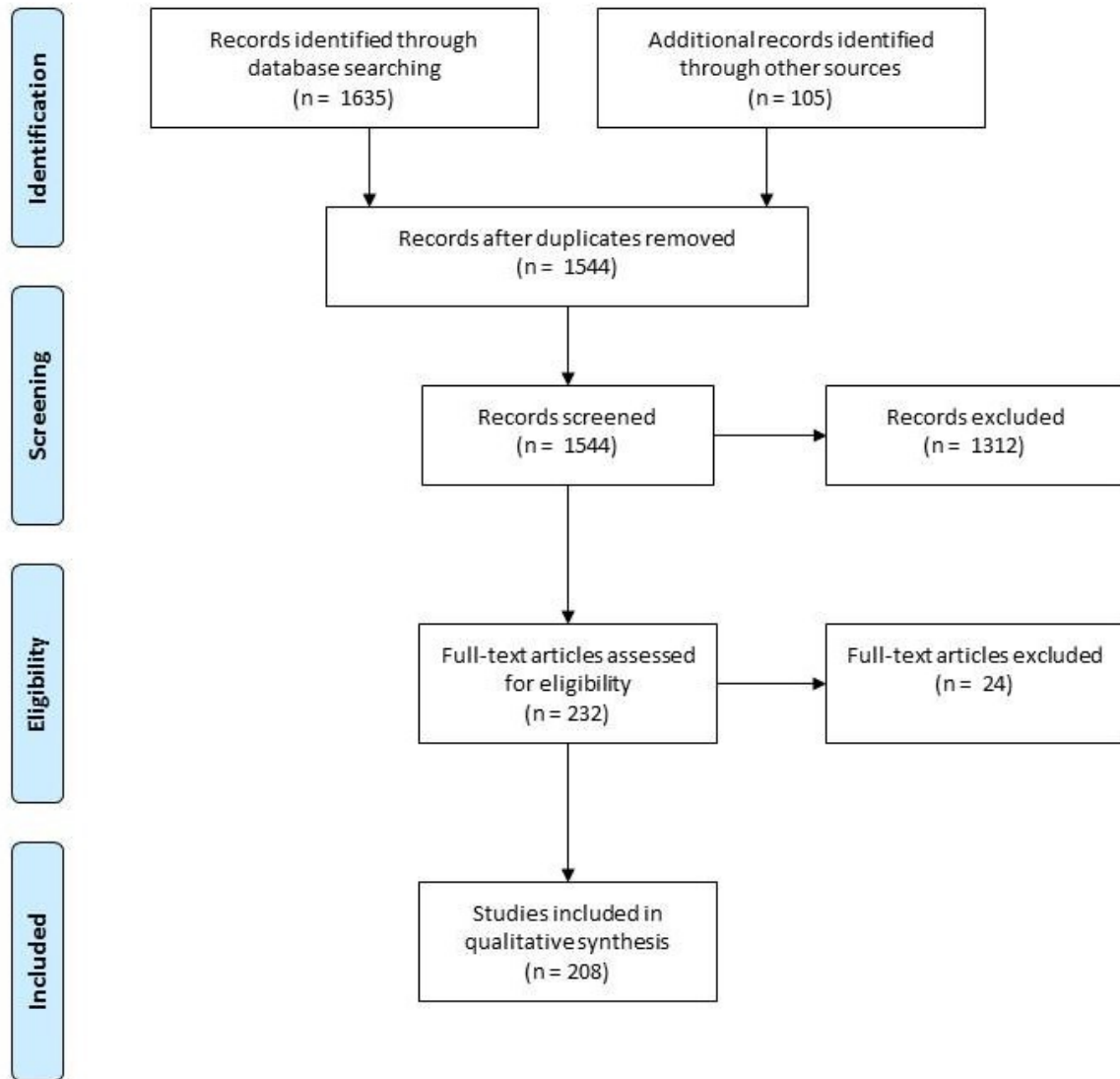


Fig. 1 Systematic literature review flow diagram, adapted from Moher et al. (2009).

Plane	Posterior Frontal Boundary
1	Anterior-most extent of the lateral ventricles
2	Anteriomost extent of the CC genu
3	Most anterior point at which the Insula is apparent bilaterally
4	Midway between the most posterior extent of the PrCS and most anterior extent of the cingulate sulcus // 6mm posterior to the first appearance of the septum pellucidum // meeting of the sylvian fissure and its anterior horizontal ramus.
5	Anteriomost point of the inner CC genu
6	Coronal plane at the optic chiasm
7	Coronal appearance of the mamillary bodies
8	Anterior extent of the temporal stem
9	Coronal appearance of the PrCG // anterior commissure
10	Midpoint of the corpus callosum
11	10mm anterior to the meeting of the SFS and PrCS
12	Splenium of the corpus callosum

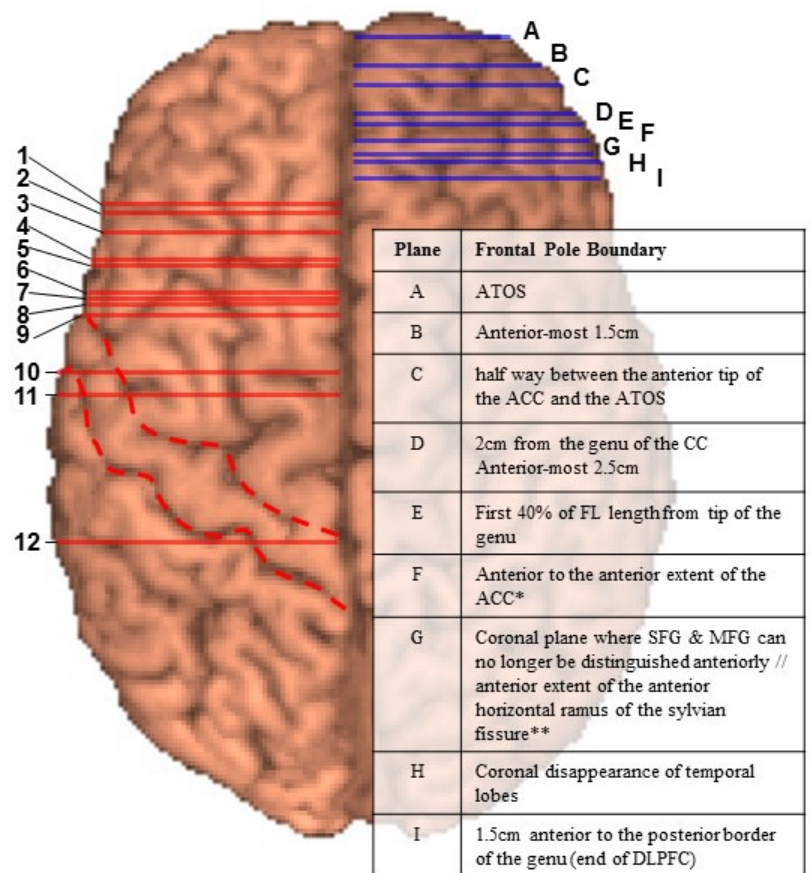


Fig. 2 Variation in boundary selection shown on a 3D rendering of an MRI of a young healthy male. Left hemisphere shows posterior frontal boundaries, Right hemisphere shows frontopolar boundaries. * medial FP border for the Rademacher/Caviness protocol, ** lateral FP border for the Rademacher/Caviness protocol, “//” marked plane corresponds to multiple landmarks. Caudal and rostral broken red lines follow the course of the Central and PreCentral sulci respectively. Omitted cut planes are variations of +/- xmm from landmarks shown in this figure. Fronto-marginal sulcus and method described by Flashman et al., (2001) not shown.

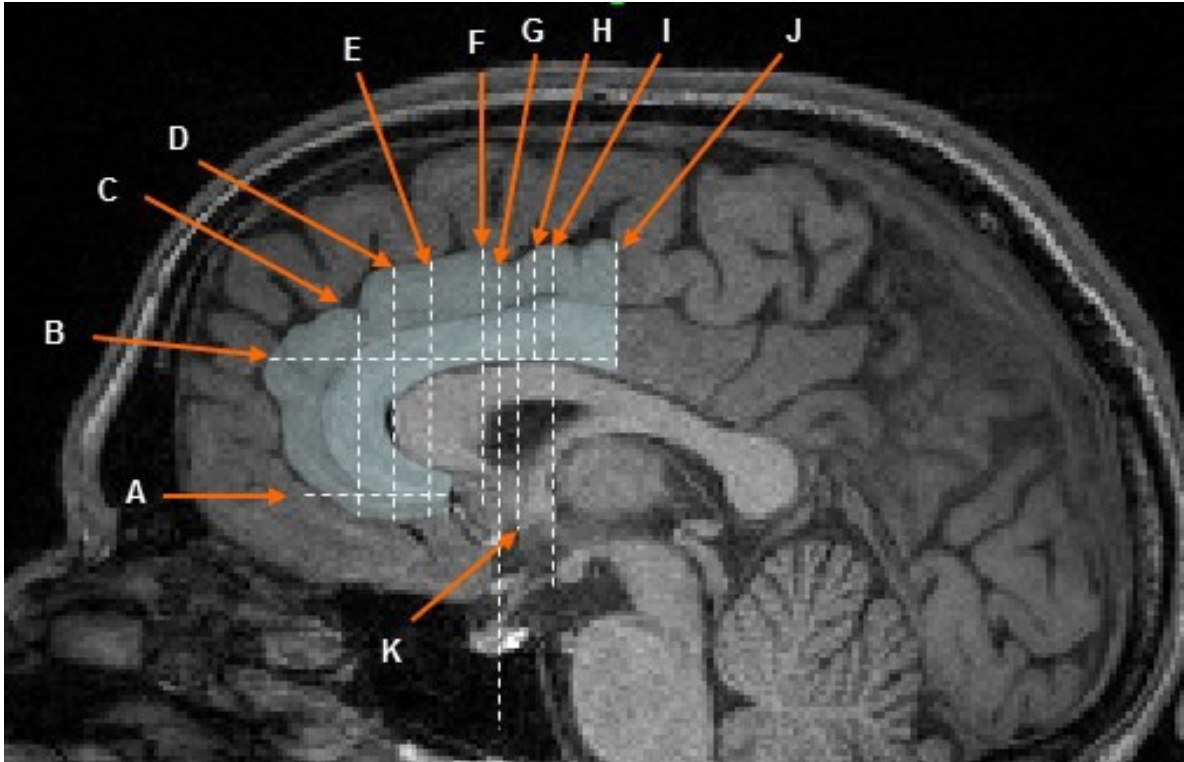


Fig. 3 Common anterior and posterior boundaries that have been used to delineate the ACC and its subregions, shown on a midsagittal MR slice of a young healthy male. A: Most ventral axial slice in which the globus pallidus, caudate and putamen can be clearly seen. B: Most dorsal axial slice where the CC divides the hemispheres. C: 16% of the distance between the CC genu and the tip of the frontal lobe. D: Coronal plane at the genu of the corpus callosum. E: Internal capsule separates caudate and putamen. F: Coronal plane at the posterior part of the CC genu. G: Most anterior coronal slice showing the temporal stem. H: Coronal plane at the most dorsal axial slice where the CC divides the hemispheres. I: Coronal appearance of the mammillary bodies. J: Coronal plane at the connection of the superior frontal sulcus and precentral sulcus / coronal plane at the dorsal termination of the precentral sulcus on the medial wall. K: Coronal plane at the anterior commissure.

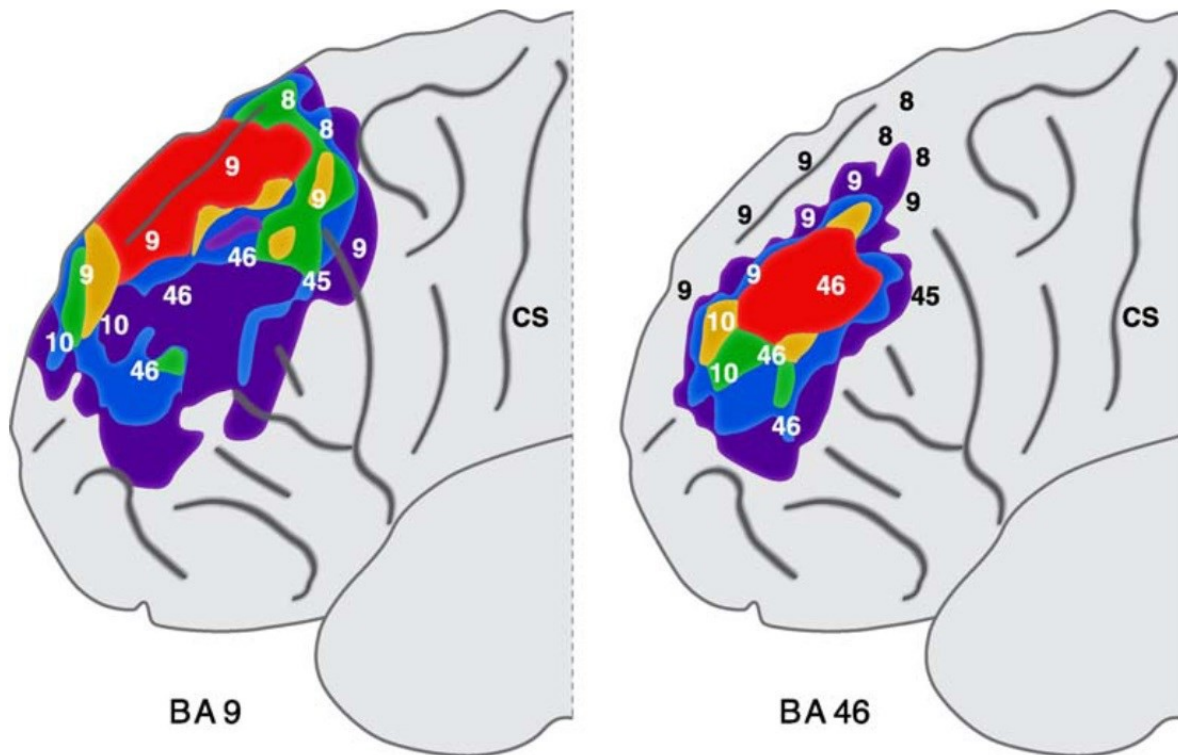


Fig. 4 Reconstructions of the variability of Brodmann Areas 9 and 46 based on 5 brains using the Talairach coordinate system. Red: overlap in all cases, orange: 4 brains, green: 3 brains, blue: 2 brains, purple: 1 brain, CS: central sulcus. Figure is an amended version of Rajkowska and Goldman-Rakic (1995) in Uylings et al. (2005), reproduced with permission.

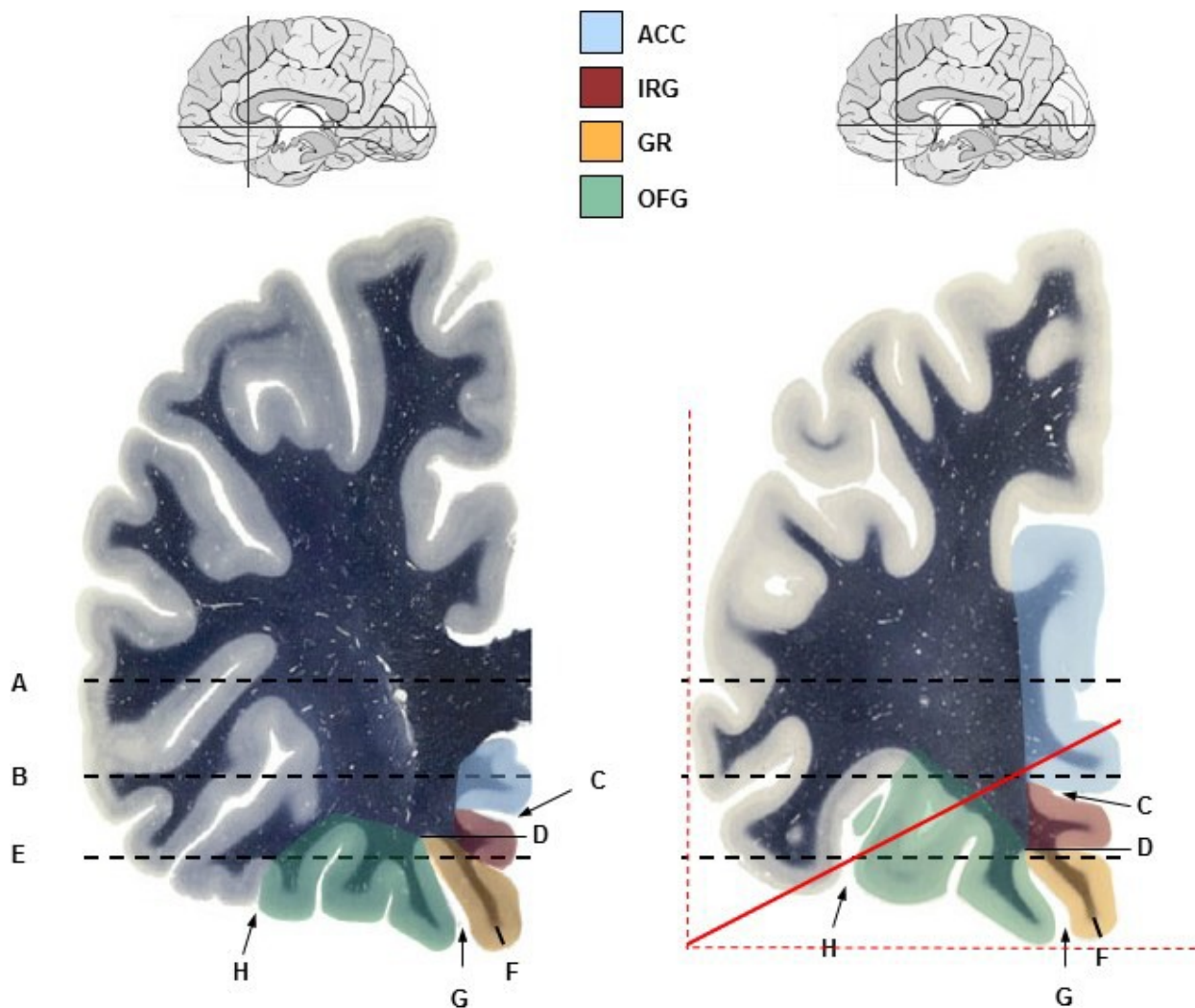


Fig. 5 Two frontal coronal sections immediately posterior (left) and anterior (right) to the genu of the corpus callosum showing various boundaries for the lateral and medial orbitofrontal cortex. A: Axial slice at the genu of the corpus callosum. B: Axial slice at the anterior commissure. C: Cingulate sulcus. D: Shortest line to the midline from the deepest part of the olfactory sulcus / rostral sulcus. E: Plane at the axial termination of the majority of the olfactory sulcus. F: Grey matter limited by the central fissure. G: Olfactory sulcus. H: Lateral orbital sulcus. ACC: Anterior Cingulate Cortex. IRG: Inferior Rostral Gyrus. GR: Gyrus Rectus. OFC: Orbitofrontal Gyri. Red lines indicate the tangent lines (dashed) and locator line (solid) which runs from 5 slices below the anterior commissure to the tangent bisection (from the Lacerda 2003 protocol). Images modified with permission from www.thehumanbrain.info

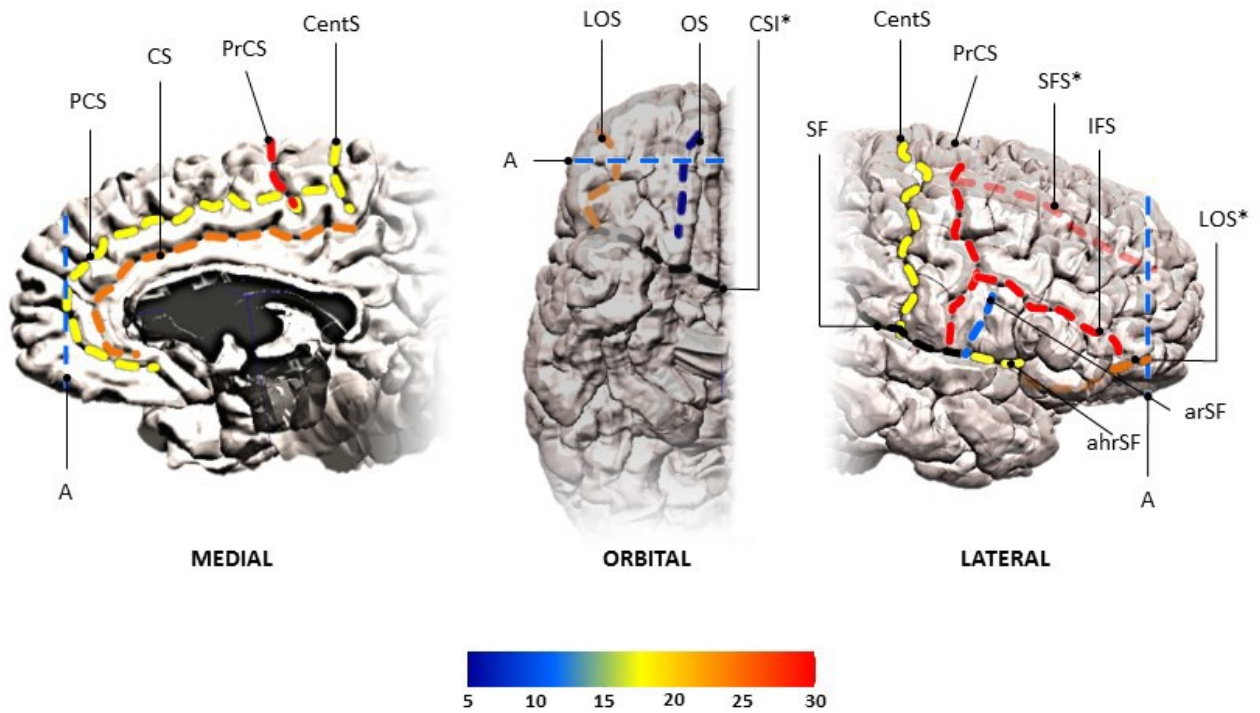


Fig. 6 Primary sulcal landmarks for the parcellation of the frontal lobes, shown on the right hemisphere. Colour-coded lines represent the number of papers that report using these boundaries. ahrSF: Anterior horizontal ramus of the Sylvian fissure; arSF: Ascending ramus of the Sylvian fissure; CS: Cingulate sulcus; CSI: Circular sulcus of the insula; CentS: Central sulcus; IFS: Inferior frontal sulcus; LOS: Lateral orbital sulcus; OS: Olfactory sulcus; PCS: Paracingulate sulcus; PrCS: Precentral sulcus; SF: Sylvian fissure; SFS: Superior frontal sulcus. Line A represents the most anterior extent of the cingulate or paracingulate sulcus (frontal pole). * denotes sulcus partially obscured from view (represented by transparency).

Footnotes:

¹ The data compiled over the course of this review (and the available supplementary material) may provide the basis for further reviews explicitly dealing with the effects of boundary variability on reported results and inconsistencies on a syndrome-specific basis.

² These studies too are examinations across a small number of brains and so may not have fully captured population-wide variability.

³ In addition to the difficulty in identifying the lateral boundary between the IFG and OFC, and the posterior and polar boundaries discussed above.

Online Resource 1 Excel spreadsheet of all reviewed parcellation methods. Bold horizontal dividers identify groups of papers that use broadly the same protocol, starting with the paper in which the cited method originated. Details of the sample, acquisition hardware, sub-regional boundaries and quality scores are included.

Online Resource 2 Complete references of all reviewed protocols.

7. References

- Amunts K, Schleicher A, Burgel U, Mohlberg H, Uylings HBM, Zilles K (1999). Broca's region revisited: Cytoarchitecture and intersubject variability. *J Comp Neurol* 412: 319-341
- Aron AR, Robbins TW, Poldrack RA (2004). Inhibition and the right inferior frontal cortex. *Trends in Cogn Sci*, 8(4): 170-177.
- Asami T, Hayano F, Nakamura M, Yamasue H, Uehara K, Otsuka T, Roppongi T, Nihashi N, Inoue T, Hirayasu Y (2008). Anterior cingulate cortex volume reduction in patients with panic disorder. *Psychiatry Clin Neurosci*, 62(3): 322-330.
- Baaré WF, Hulshoff PHE, Hijman R, Mali WP, Viergever MA, Kahn RS (1999). Volumetric analysis of frontal lobe regions in schizophrenia: relation to cognitive function and symptomatology. *Biol Psychiatry*, 45(12): 1597-605.
- Bäckman L, Robins-Wahlin TB, Lundin A, Ginovart N, Farde L (1997). Cognitive deficits in Huntington's disease are predicted by dopaminergic PET markers and brain volumes. *Brain*, 120(12): 2207-2217.
- Ballmaier M, Toga A, Blanton R, Sowell ER, Lavretsky H, Peterson BS, Pham D, Kumar A (2004). Anterior cingulate, gyrus rectus, and orbitofrontal abnormalities in elderly depressed patients: an MRI-based parcellation of the prefrontal cortex. *Am J Psychiatry*, 161: 99-108.

- Bartzokis G, Mintz J, Marx P, Osborn D, Gutkind D, Chiang F, Phelan CK, Marder SR (1993). Reliability of in vivo volume measures of hippocampus and other brain structures using MRI. *Magn Reson Imaging*, 11: 993-1006.
- Beck E (1949). A cytoarchitectural investigation into the boundaries of cortical areas 13 and 14 in the human brain. *Journal of Anatomy* 83: 147–157
- Beckmann M, Johansen-Berg H, Rushworth MFS (2009). Connectivity-based parcellation of human cingulate cortex and its relation to functional specialization. *J Neurosci*, 29(4): 1175-1190.
- Benoit RG, Gilbert SJ, Volle E, Burgess PW (2010). When I think about me and simulate you: medial rostral prefrontal cortex and self-referential processes. *NeuroImage*, 50(3): 1340-1349.
- Berryhill P, Lilly MA, Levin HS, Hillman GR, Mendelsohn D, Brunder DG, Fletcher JM, Kufera J, Kent TA, Yeakley J, Bruce D, Eisenberg HM (1995). Frontal Lobe Changes after Severe Diffuse Closed Head Injury in Children: A Volumetric Study of Magnetic Resonance Imaging. *Neurosurg*, 37(3): 392–400.
- Beyer JL, Kuchibhatla M, Payne ME, Macfall J, Cassidy F, Krishnan KRR (2009). Gray and white matter brain volumes in older adults with bipolar disorder. *Int J Geriatr Psychiatry*, 24: 1445-1452.
- Bjork JM, Momenan R, Hommer DW (2009). Delay discounting correlates with proportional lateral frontal cortex volumes. *Biol Psychiatry*, 65(8): 710-713.

- Blatter DD, Bigler ED, Gale SD, Johnson SC, Anderson C, Burnett BM, Parker N, Kurth S, Horn S (1995). Quantitative volumetric analysis of brain MRI: normative database spanning five decades of life. *Am J Neuroradiol*, 16: 241–245.
- Blumberg HP, Stern E, Ricketts S, Martinez D, de Asis J, White T, Epstein J, Isenberg N, McBride PA, Kemperman I, Emmerich S, Dhawan V, Eidelberg D, Kocsis J, Silbersweig D (1999). Rostral and orbital prefrontal dysfunction in the manic state of bipolar disorder. *Am J Psychiatry*, 156: 1986–1988.
- Bohland JW, Bokil H, Allen CB, Mitra PP (2009). The brain atlas concordance problem: Quantitative comparison of anatomical parcellations. *PLoS ONE*, 4(9): e7200.
- Bookheimer S (2002). Functional MRI of language: new approaches to understanding the cortical organization of semantic processing. *Ann Rev Neurosci*, 25:151–188.
- Botteron KN, Raichle ME, Drevets WC, Heath AC, Todd RD (2002). Volumetric reduction in left subgenual prefrontal cortex in early onset depression. *Biol Psychiatry*, 51(4): 342-344.
- Brambilla P, Nicoletti MA, Harenski K, Sassi RB, Mallinger AG, Frank E, Kupfer DJ, Keshavan MS, Soares JC (2002). Anatomical MRI study of subgenual prefrontal cortex in bipolar and unipolar subjects. *Neuropsychopharmacology*, 27(5): 792-799.
- Bremner JD, Bronen RA, Erasquin GD, Vermetten E, Staib LH, Ng CK, Soufer R, Charney DS, Innis RB (1998). Development and reliability of a method for using magnetic resonance imaging for the definition of regions of interest for Positron Emission Tomography. *Clin Positron Imaging*, 1(3): 145-159.

Bremner JD, Narayan M, Anderson ER, Staib LH, Miller HL, Charney DS (2000). Hippocampal volume reduction in major depression. *Am J Psychiatry*, 157:115-117.

Bremner JD, Vythilingam M, Vermetten E, Nazeer A, Adil J, Khan S, Staib LH, Charney DS (2002). Reduced volume of orbitofrontal cortex in major depression. *Biol Psychiatry*, 51(4): 273-279.

Brodman, K (1909). *Vergleichende Lokalisationslehre der Großhirnrinde in ihren Prinzipien dargestellt auf Grund des Zellenbaues*. Barth, Leipzig, 1909; English translation available in Garey, L. J. *Brodman's Localization in the Cerebral Cortex*. Smith Gordon, London, 1994.

Burgess PW, Simons JS, Dumontheil I, Gilbert SJ (2006). The gateway hypothesis of rostral prefrontal cortex (area 10) function. In Duncan J, Phillips LH, McLeod P (eds), *Measuring the Mind: Speed, Control and Age Vol. 3*. Oxford University Press, Oxford, pp 217-248.

Bush G, Luu P, Posner M (2000). Cognitive and emotional influences in anterior cingulate cortex. *Trends in Cogn Sci*, 4(6): 215-222.

Cabeza R, Nyberg L (2000). Imaging cognition II: An empirical review of 275 PET and fMRI studies. *J Cogn Neurosci*, 12(1): 1-47.

Campbell, A. W (1905). *Histological Studies on the Localisation of Cerebral Function*. Cambridge University Press, Cambridge, UK.

Carper RA, Courchesne E (2005). Localized enlargement of the frontal cortex in early autism. *Biol Psychiatry*, 57(2): 126-133.

- Caviness VS, Meyer J, Makris N, Kennedy DN (1996). MRI-Based Topographic Parcellation of Human Neocortex: An Anatomically Specified Method with Estimate of Reliability. *J Cogn Neurosci*, 8(6): 566-587.
- Chi JG, Dooling EC, Gilles FH (1977). Gyral development of the human brain. *Ann Neurol* 11: 86-93.
- Chiavaras MM, Petrides M (2000). Orbitofrontal sulci of the human and macaque monkey brain. *J Comp Neurol*, 422(1): 35-54.
- Chiavaras MM, LeGoualher G, Evans A, Petrides M (2001). Three-dimensional probabilistic atlas of the human orbitofrontal sulci in standardized stereotaxic space. *NeuroImage*, 13(3): 479-496.
- Coffey CE, Weiner RD, Djang W, Figiel G, Soady S, Patterson L, Holt PD, Spritzer CE, Wilkinson WE (1991). Brain anatomic effects of electroconvulsive therapy. *Arch Gen Psychiatry*, 48: 1013-1021.
- Coffey CE, Lucke JF, Saxton JA, Ratcliff G, Uritas LJ, Billig B, Bryan RN (1998). Sex differences in brain aging: a quantitative magnetic resonance imaging study. *Arch Neurol*, 55(2): 169-79.
- Convit A, Wolf OT, de Leon MJ, Patalinjug M, Kandil E, Caraos C, Scherer A, Saint Louis LA, Cancro, R (2001). Volumetric analysis of the pre-frontal regions: findings in aging and schizophrenia. *Psychiatry Res: Neuroimaging*, 107(2): 61-73.

- Coryell W, Nopoulos P, Drevets W, Wilson T, Andreasen NC (2005). Subgenual prefrontal cortex volumes in major depressive disorder and schizophrenia: diagnostic specificity and prognostic implications. *Am J Psychiatry*, 162(9): 1706–1712.
- Costafreda SG, Fu CHY, Lee L, Everitt B, Brammer MJ, David AS (2006). A systematic review and quantitative appraisal of fMRI studies of verbal fluency: Role of the left inferior frontal gyrus. *Human Brain Mapping* 27(10): 799-810.
- Cotter, D., Hudson, L., Landau, S. (2005). Evidence for orbitofrontal pathology in bipolar disorder and major depression, but not in schizophrenia. *Bipolar Disorders* 7: 358–369.
- Cowell PE, Turetsky BI, Gur RC, Grossman RI, Shtasel DL, Gur RE (1994). Sex differences in aging of the human frontal and temporal lobes. *Journal Neurosci*, 14(8): 4748-55.
- Crespo-Facorro B, Kim JJ, Andreasen NC, O’Leary DS, Wisner AK, Bailey JM, Harris, G, Magnotta VA (1999). Human frontal cortex: an MRI-based parcellation method. *NeuroImage*, 10(5): 500-519.
- Croxson PL, Johansen-Berg H, Behrens TEJ, Robson MD, Pinski MA, Gross CG, Richter W, Kastner S, Rushworth MFS (2005). Quantitative investigation of connections of the prefrontal cortex in the human and macaque using probabilistic diffusion tractography. *J Neurosci*, 25(39): 8854-8866.
- Deary IJ, Penke L, Johnson W (2010). The neuroscience of human intelligence differences. *Nature Rev Neurosci*, 11(3): 201-211.

- Desikan, RS, Ségonne F, Fischl B, Quinn BT, Dickerson BC, Blacker D, Buckner RL, Dale AM, Maguire RP, Hyman BT, Albert MS, Killiany RJ (2006). An automated labeling system for subdividing the human cerebral cortex on MRI scans into gyral based regions of interest. *NeuroImage*, 31(3): 968-980.
- Devinsky O, Morrell MJ, Vogt BA (1995). Contributions of anterior cingulate cortex to behaviour. *Brain*, 118: 279-306.
- Devlin JT, Poldrack RA (2007). In praise of tedious anatomy. *NeuroImage*, 37(4): 1033-1041; discussion 1050-1058.
- Drevets WC, Price J, Simpson J, Todd R (1997). Subgenual prefrontal cortex abnormalities in mood disorders. *Nature*, 386: 824-827.
- Dumontheil I, Burgess PW, Blakemore, S-J (2008). Development of rostral prefrontal cortex and cognitive and behavioural disorders. *Dev Med Child Neurol*, 50(3): 168-181.
- Dumontheil I, Gilbert SJ, Frith CD, Burgess PW (2010). Recruitment of lateral rostral prefrontal cortex in spontaneous and task-related thoughts. *Q J Exp Psychol*, 63(9): 1740–1756.
- Duvernoy HM (1999). The human brain: Surface, blood supply, and three-dimensional sectional anatomy, 2nd Edition. Springer, Wien New York.
- Filipek PA, Semrud-Clikeman M, Steingard RJ, Renshaw PF, Kennedy DN, Biederman J (1997). Volumetric MRI analysis comparing subjects having attention-deficit hyperactivity disorder with normal controls. *Neurology*, 48(3): 589-601.

Fischl B, Rajendran N, Busa E, Augustinack J, Hinds O, Yeo BTT, Mohlberg H, Amunts K, Zilles K (2008). Cortical folding patterns and predicting cytoarchitecture. *Cereb Cortex*, 18(8): 1973-1980.

Flashman LA, McAllister TW, Johnson SC, Rick JH, Green RL, Saykin AJ (2001). Specific frontal lobe subregions correlated with unawareness of illness in schizophrenia: a preliminary study. *J Neuropsychiatry Clin Neurosci*, 13(2): 255-257, 2001.

Fornito A, Yucel M, Wood S, Stuart GW, Buchanan J-A, Proffitt T, Anderson V, Velakoulis D, Pantelis C (2004). Individual Differences in Anterior Cingulate/Paracingulate Morphology Are Related to Executive Functions in Healthy Males. *Cereb Cortex*, 14(4): 424-431.

Fornito A, Whittle S, Wood SJ, Velakoulis D, Pantelis C, Yücel M (2006). The influence of sulcal variability on morphometry of the human anterior cingulate and paracingulate cortex. *NeuroImage*, 33(3): 843-854.

Foundas AL, Weisberg A, Browning CA, Weinberger DR (2001). Morphology of the frontal operculum: A volumetric magnetic resonance imaging study of the pars triangularis. *J Neuroimaging*, 11:153-159.

Frost MA, Goebel R (2012). Measuring structural-functional correspondence: Spatial variability of specialised brain regions after macro-anatomical alignment. *NeuroImage*, 59(2): 1369-1381.

Gansler DA, McLaughlin NCR, Iguchi L, Jerram M, Moore DW, Bhadelia R, Fulwiler C (2009).

A multivariate approach to aggression and the orbital frontal cortex in psychiatric patients.

Psychiatry Res, 171(3): 145-154.

Geyer S, Weiss M, Reimann K, Lohmann G, Turner R (2011). Microstructural Parcellation of

the Human Cerebral Cortex – From Brodmann’s Post-Mortem Map to in vivo Mapping

with High-Field Magnetic Resonance Imaging. *Front Hum Neurosci*, 5: 1-7.

Gläscher J, Rudrauf D, Colom R, Paul LK, Tranel D, Damasio H, Adolphs R (2010). Distributed

neural system for general intelligence revealed by lesion mapping. *Proc Nat Acad Sci*,

107(10): 4705-4709.

Glasser MF, Van Essen DC (2011). Mapping Human Cortical Areas In Vivo Based on Myelin

Content as Revealed by T1- and T2-Weighted MRI. *J Neurosci*, 31(32): 11597-11616.

Gold SM, Dziobek I, Rogers K, Bayoumy A, McHugh PF, Convit A (2005). Hypertension and

hypothalamo-pituitary-adrenal axis hyperactivity affect frontal lobe integrity. *The J Clin*

Endocrinol Metab, 90(6): 3262-3267.

Gilbert AR (2001). Thalamic Volumes in Patients With First-Episode Schizophrenia. *Am J*

Psychiatry, 158(4): 618-624.

Gilbert SJ, Spengler S, Simons JS, Steele JD, Lawrie SM, Frith CD, Burgess PW (2006).

Functional specialization within rostral prefrontal cortex (area 10): a meta-analysis. *J Cog*

Neurosci, 18(6): 932-948.

Ginovart N, Lundin A, Farde L, Halldin C, Backman L, Swahn CG, Pauli S, Sedvall G (1997).

PET study of the pre- and post-synaptic dopaminergic markers for the neurodegenerative process in Huntington's disease. *Brain*, 120: 503-514.

Goulas A, Uylings HBM, Stiers P (2012). Unravelling the intrinsic functional organization of the

human lateral frontal cortex: A parcellation scheme based on resting state fMRI. *J Neurosci* 32(30): 10238-10252.

Gronenschild HBM, Burgmans S, Smeets F, Vuurman EFPM, Uylings HBM, Jolles J (2010). A

time-saving and facilitating approach for segmentation of anatomically defined cortical regions: MRI volumetry. *Psychiatry Res: Neuroimaging* 181: 211-218.

Gur RE, Cowell PE, Latshaw A, Turetsky BI, Grossman RI, Arnold SE, Bilker WB and Gur RC

(2000). Reduced dorsal and orbital prefrontal gray matter volumes in schizophrenia. *Arch Gen Psychiatry*, 57(8): 761-768.

Harris, GJ, Barta PE, Peng LW, Lee S, Brettschneider PD, Shah A, Henderer JD, Schlaepfer TE,

Pearlson GD (1994). MR gray and white matter segmentation using manual thresholding: Dependence on image brightness. *Am J Neuroradiol*, 15: 225-230.

Hastings RS, Parsey RV, Oquendo MA, Arango V, Mann JJ (2004). Volumetric analysis of the prefrontal cortex, amygdala, and hippocampus in major depression.

Neuropsychopharmacology, 29(5): 952-959.

Haznedar MM, Buchsbaum MS, Metzger M, Solimando A, Spiegel-Cohen J, Hollander E (1997).

Anterior cingulate gyrus volume and glucose metabolism in autistic disorder. *Am J Psychiatry*, 154: 1047-1050.

Head D, Raz N, Gunning-Dixon F, Williamson A, Acker JD (2002). Age-related differences in the course of cognitive skill acquisition: The role of regional cortical shrinkage and cognitive resources. *Psychol Aging*, 17(1): 72-84.

Hill DE, Yeo RA, Campbell RA, Hart B, Vigil J, Brooks W (2003). Magnetic resonance imaging correlates of attention-deficit/hyperactivity disorder in children. *Neuropsychology*, 17(3): 496-506.

Hirayasu Y, Shenton ME, Salisbury DF, Kwon JS, Wible CG, Fischer IA, Yurgelun-Todd D, Zarate C, Kikinis R, Jolesz FA, McCarley RW (1999). Subgenual cingulate cortex volume in first-episode psychosis. *Am J Psychiatry*, 156: 1091-1093.

Hof PR, Mufson EJ, Morrison JH (1995). Human orbitofrontal cortex: cytoarchitecture and quantitative immunohistochemical parcellation. *J Comp Neurol*, 359(1): 48-68.

Iordanova B, Rosenbaum D, Norman D, Weiner M, Studholme C (2006). MR imaging anatomy in neurodegeneration: A robust volumetric parcellations method of frontal lobe gyri with quantitative validation in patients with dementia. *Am J Neuroradiol*, 27: 1747-1754.

Jernigan TL, Archibald SL, Berhow MT, Sowell ER, Foster DS, Hesselink JR (1991). Cerebral structure on MRI, part1: Localization of age-related changes. *Biol Psychiatry*, 29: 55-67.

- Johansen-Berg H, Gutman DA, Behrens TEJ, Matthews PM, Rushworth MFS, Lozano AM, Mayberg HS (2008). Anatomical connectivity of the subgenual cingulate regions targeted with deep brain stimulation for treatment-resistant depression. *Cereb Cortex*, 18: 1374-1383.
- John JP, Wang L, Moffitt AJ, Singh HK, Gado MH, Csernansky JG (2006). Inter-rater reliability of manual segmentation of the superior, inferior and middle frontal gyri. *Psychiatry Res*, 148(2-3): 151-163.
- John JP, Yashavantha BS, Gado M, Veena R, Jain S, Ravishankar, Csernansky JG (2007). A proposal for MRI-based parcellations of the frontal pole. *Brain Struct Funct*, 212: 245-253.
- Jones BF, Barnes J, Uylings HBM, Fox NC, Frost C, Witter MP, Scheltens P (2006). Differential regional atrophy of the cingulate gyrus in Alzheimer disease: A volumetric MRI study. *Cereb Cortex*, 16(12): 1701-1708.
- Jung RE, Haier RJ (2007). The Parieto-Frontal Integration Theory (P-FIT) of intelligence: converging neuroimaging evidence. *Beh Brain Sci*, 30(2): 135-154.
- Kahnt T, Chang LJ, Park SQ, Heinzle J, Haynes J-D (2012). Connectivity-based parcellation of the human orbitofrontal cortex. *J Neurosci*, 32(18): 6240-6250
- Kates WR, Frederikse M, Mostofsky SH, Folley BS, Cooper K, Mazur-Hopkins P, Kofman O, Singer HS, Denckla MB, Pearlson GD, Kaufmann WE (2002). MRI parcellation of the frontal lobe in boys with attention deficit hyperactivity disorder or Tourette syndrome. *Psychiatry Res: Neuroimaging*, 116(1-2): 63-81.

- Kaur S, Sassi RB, Axelson D, Nicoletti M, Brambilla P, Monkul ES, Hatch JP, Keshevan MS, Ryan N, Birmaher B, Soares JC (2005). Cingulate cortex anatomical abnormalities in children and adolescents with bipolar disorder. *Am J Psychiatry*, 162(9): 1637-1643.
- Keller SS, Crow T, Foundas A, Amunts K, Roberts N (2009). Broca's area: Nomenclature, anatomy, typology and asymmetry. *Brain & Lang*, 109: 29-48.
- Keller SS, Highley JR, Garcia-Finana M, Sluming V, Rezaie R, Roberts N (2007) Sulcal variability, stereological measurement and asymmetry of Broca's area on MR images. *J Anat*, 211:534-555.
- Kegeles LS, Malone KM, Slifstein M, Ellis SP, Xanthopoulos E, Keilp JG, Campbell C, Oquendo M, van Heertum RL, Mann JJ (2003). Response of cortical metabolic deficits to serotonergic challenge in familial mood disorders. *Psychiatry Interpers Biol Process*, 160(1): 76-82.
- Kikinis R, Shenton ME, Iosifescu DV, McCarley RW, Saiviroonporn P, Hokama HH, Robatino A, Metcalf D, Wible CG, Portas CM, Donnino RM, Jolesz FA (1996). A digital brain atlas for surgical planning, model-driven segmentation, and teaching. *IEEE Trans Vis Comp Graphics*, 2(3), 232-241.
- Knaus TA, Bollich AM, Corey DM, Lemen LC, Foundas AL (2006). Variability in perisylvian brain anatomy in healthy adults. *Brain Lang*, 97:219-232.
- Kringelbach ML, Rolls ET (2004). The functional neuroanatomy of the human orbitofrontal cortex: evidence from neuroimaging and neuropsychology. *Prog Neurobiol*, 72(5): 341-372.

- Lacerda AL, Hardan AY, Yorbik O, Keshavan MS (2003). Measurement of the orbitofrontal cortex: a validation study of a new method. *NeuroImage*, 19(3): 665-673.
- Lai TJ, Payne ME, Byrum CE, Steffens DC, Krishnan KRR. Reduction of orbital frontal cortex volume in geriatric depression. *Biol Psychiatry*, 48(10): 971-975
- Liberati A, Altman DG, Tetzlaff J, Mulrow C, Gotzsche PC, Ionnadis JPA, Clarke M, Devereaux PJ, Kleijnen J, Moher D (2009). The PRISMA statement for reporting systematic reviews and meta-analyses of studies that evaluate healthcare interventions: explanation and elaboration. *BMJ*, 339:b2700.
- Lindberg O, Ostberg P, Zandbelt BB, Oberg J, Zhang Y, Andersen C, Looi JCL, Bogdanovic, Wahlund L-O (2009). Cortical morphometric subclassification of frontotemporal lobar degeneration. *Am J Neuroradiol*, 30(6): 1233-1239.
- Lyoo IK, Han MH, Cho DY (1998). A brain MRI study in subjects with borderline personality disorder. *J Affect Disord*, 50(2-3): 235-43.
- Mackey S, Petrides M (2009). Architectonic mapping of the medial region of the human orbitofrontal cortex by density profiles. *Neurosci*, 159: 1089-1107.
- MacLulich AMJ, Ferguson KJ, Wardlaw JM, Starr JM, Deary IJ, Seckl JR (2006). Smaller left anterior cingulate cortex volumes are associated with impaired hypothalamic-pituitary-adrenal axis regulation in healthy elderly men. *J Clin Endocrinol Metab*, 91(4): 1591-1594.
- Mansouri FA, Tanaka K, Buckley MJ (2009). Conflict-induced behavioural adjustment: A clue to the executive functions of the prefrontal cortex. *Nature Rev Neurosci*, 10:141-152.

- McCormick LM, Ziebell S, Nopoulos P, Cassell M, Andreasen NC, Brumm M (2006). Anterior cingulate cortex: an MRI-based parcellation method. *NeuroImage*, 32(3): 1167-1175.
- McLaughlin NCR, Moore DW, Fulwiler C, Bhadelia R, Gansler DA (2009). Differential Contributions of Lateral Prefrontal Cortex Regions to Visual Memory Processes. *Brain Imaging Beh*, 3(2): 202-211.
- Medina KL, McQueeney T, Nagel BJ, Hanson KL, Schweinsburg AD, Tapert SF (2008). Prefrontal cortex volumes in adolescents with alcohol use disorders: unique gender effects. *Alcoholism Clin Exp Res*, 32(3): 386-394.
- Middleton FA, Strick PL (2001). Cerebellar projections to the prefrontal cortex of the primate. *J Neurosci* 21(2): 700-712.
- Moberg PJ, Doty RL, Turetsky BI, Arnold SE, Mahr RN, Gur, R. C., Bilker, W, Gur RE (1997). Olfactory identification deficits in schizophrenia: correlation with duration of illness. *Am J Psychiatry*, 154(7): 1016-1018.
- Moher D, Liberati A, Tetzlaff J, Altman DG, The PRISMA Group (2009). Preferred reporting items for systematic reviews and meta-analyses: The PRISMA Statement. *PLoS Med*, 6(6):e1000097. doi:10.1371/journal.pmed1000097.
- Monkul ES, Hatch JP, Nicoletti MA, Spence S, Brambilla P, Lacerda ALT, Sassi RB, Mallinger AG, Keshevan MS, Soares JC (2007). Fronto-limbic brain structures in suicidal and non-suicidal female patients with major depressive disorder. *Mol Psychiatry*, 12(4): 360-366.

- Nagel, B, Medina K, Yoshii J, Schweinsburg AD, Moadab I, Tapert SF (2006). Age-related changes in prefrontal white matter volume across adolescence. *Neuroreport*, 17(13): 1427-1431.
- Najt P, Nicoletti M, Chen HH, Hatch JP, Caetano SC, Sassi RB, Axelson D, Brmabilla P, Keshevan MS, Ryan ND, Birmaher and Soares JC (2007). Anatomical measurements of the orbitofrontal cortex in child and adolescent patients with bipolar disorder. *Neurosci*, 413(3): 183-186.
- Nakamura M, Nestor PG, Levitt JJ, Cohen AS, Kawashima T, Shenton ME, McCarley RW (2008). Orbitofrontal volume deficit in schizophrenia and thought disorder. *Brain*, 131(1), 180-195.
- Nifosì F, Toffanin T, Follador H, Zonta F, Padovan G, Pigato G, Carollo C, Ermani M, Amista P, Perini GI (2010). Reduced right posterior hippocampal volume in women with recurrent familial pure depressive disorder. *Psychiatry Res*, 184(1): 23-28.
- Nishitani N, Schurman M, Amunts K, Hari R (2005). Broca's region: from action to language. *Physiol* 20:60-69.
- Noga JT, Aylward E, Barta PE, Pearlson GD (1995). Cingulate gyrus in schizophrenic patients and normal volunteers. *Psychiatry Res*, 61(4): 201-208.
- Ongür D, Ferry AT, Price JL (2003). Architectonic subdivision of the human orbital and medial prefrontal cortex. *J Comp Neurol*, 460(3): 425-449.
- Ono M, Kubik S, Abernathey CC (1990). *Atlas of the cerebral sulci*. Stuttgart: Thieme Verlag.

Palomero-Gallagher N, Vogt BA, Schleicher A, Mayberg HS, Zilles K (2009). Receptor architecture of human cingulate cortex: evaluation of the four-region neurobiological model. *Hum Brain Mapp*, 30(8): 2336-2355.

Pantazis D, Joshi A, Jiang J, Shattuck D, Bernstein LE, Damasio H, Leahy RM (2010). Comparison of landmark-based and automatic methods for cortical surface registration. *Neuroimage*, 49(3): 2479-2493.

Pantel J, Schroder J, Essig M, Popp D, Dech H, Knopp MV, Schad LR, Eysenbach K, Backenstrass M, Friedlinger M (1997). Quantitative magnetic resonance imaging in geriatric depression and primary degenerative dementia. *J Affect Disord*, 42(1): 69-83.

Paus T, Otaky N, Caramanos Z, MacDonald D, Zijdenbos A, D'Avirro D, Gutmans D, Holmes C, Tomiauolo F, Evans AC (1996). In vivo morphometry of the intrasulcal gray matter in the human cingulate, paracingulate, and superior-rostral sulci: hemispheric asymmetries, gender differences and probability maps. *J Comp Neurol*, 376(4): 664-673.

Petrides M (2000). The role of the mid-dorsolateral prefrontal cortex in working memory. *Exp Brain Res*, 133(1): 44-54.

Petrides M, Pandya DN (1994). Comparative architectonic analysis of the human and the macaque frontal cortex. In: Boller F and Grafman J (eds) *Handbook of Neuropsychology*, Vol. 9. Elsevier, Amsterdam, pp 17-58.

- Petrides M, Tomiauolo F, Yeterian EH, Pandya DN (2013). The prefrontal cortex: comparative architectonic organization in the human and the macaque monkey brains. *Cortex*, 48(1): 46-57.
- Prasad KMR, Sahni SD, Rohm BR, Keshavan MS (2005). Dorsolateral prefrontal cortex morphology and short-term outcome in first-episode schizophrenia. *Psychiatry Res*, 140(2): 147-155.
- Rademacher J, Caviness VS, Steinmetz H, Galaburda AM (1993). Topographical variation of the human primary cortices: implications for neuroimaging, brain mapping, and neurobiology. *Cereb Cortex* 3(4): 313-329.
- Rademacher J, Galaburda AM, Kennedy DN, Filipek PA, Caviness VS (1992). Human Cerebral Cortex: Localization, Parcellation, and Morphometry with Magnetic Resonance Imaging. *J Cogn Neurosci*, 4(4): 352-374.
- Rajkowska G, Goldman-Rakic PS (1995). Cytoarchitectonic definition of prefrontal areas in the normal human cortex: II. Variability in locations of areas 9 and 46 and relationship to the Talairach Coordinate System. *Cereb Cortex* 5(4): 323-337.
- Rajkowska G, Miguel-Hidalgo JJ, Dubey P, Stockmeier CA, Krishnan RR (2005). Prominent reduction in pyramidal neuron density in the orbitofrontal cortex of elderly depressed patients. *Biol Psychiatry*, 58: 297-306.

Rankin KP, Rosen HJ, Kramer JH, Chaier GF, Weiner MW, Schuff N, Miller BL. Right and left medial orbitofrontal volumes shown an opposite relationship to agreeableness in FTD.

Dementia Geriatr Cogn Disord, 17(4): 328-332.

Ranta ME, Crocetti D, Clauss JA, Kraut MA, Mostofsky SH, Kaufmann WE (2009). Manual MRI parcellation of the frontal lobe. *Psychiatry Res*, 172(2): 147-154.

Ratnanather JT, Botteron KN, Nishino T, Massie AB, Lal RM, Patel SG, Peddi S, Todd RD, Miller MI (2001). Validating cortical surface analysis of medial prefrontal cortex.

NeuroImage, 14(5): 1058-1069.

Rauch SL, Shin LM, Segal E, Pitman RK, Carson MA, McMullin K, Whalen PJ, Makris N (2003). Selectively reduced regional cortical volumes in post-traumatic stress disorder.

NeuroReport, 14(7): 913-916.

Raz N, Torres IJ, Briggs SD, Spencer WD, Thornton AE, Loken WJ, Gunning FM, McQuain JD, Driesen NR, Acker JD (1995). Selective neuroanatomic abnormalities in Down's syndrome and their cognitive correlates: Evidence from MRI morphometry. *Neurology*, 45: 356-366.

Reignes MHT, Krings T, Nguyen H-H, Kuker W, Spetzger U, Rhode V, Hutter BO, Thron A, Gilsbach JM (2000). Virtual pointer projection of the central sulcus to the outside of the skull using frameless neuronavigation – accuracy and applications. *Acta Neurochirurgica*, 142: 1385-1390

Riffkin J, Yücel M, Maruff P, Wood SJ, Soulsby B, Olver J, Kyrios M, Velakoulis D, Pantelis C (2005). A manual and automated MRI study of anterior cingulate and orbito-frontal

cortices, and caudate nucleus in obsessive-compulsive disorder: comparison with healthy controls and patients with schizophrenia. *Psychiatry Res*, 138(2): 99-113.

Rolls ET, Grabenhorst F (2008). The orbitofrontal cortex and beyond: from affect to decision-making. *Prog Neurobiol*, 86(3): 216-44.

Rosen HJ, Perry RJ, Murphy J, Kramer JH, Mychack P, Schuff N, Weiner M, Levenson RW, Miller BL (2002). Emotion comprehension in the temporal variant of frontotemporal dementia. *Brain*, 125: 2286-2295.

Rosso IM, Makris N, Thermenos HW, Hodge SM, Brown A, Kennedy D, Caviness VS, Faraone SV, Tsuang MT, Seiman LJ (2010). Regional prefrontal cortex gray matter volumes in youth at familial risk for schizophrenia from the Harvard Adolescent High Risk Study. *Schizophrenia Res*, 123(1): 15-21.

Rupp CI, Fleischhacker WW, Kemmler G, Oberbauer H, Scholtz AW, Wanko C, Hinterhuber H (2005). Various bilateral olfactory deficits in male patients with schizophrenia. *Schizophrenia Bull*, 31(1): 155-165.

Sabb FW, Bilder RM, Chou M, Bookheimer SY (2007). Working memory effects on semantic processing: priming differences in pars orbitalis. *NeuroImage*, 37(1): 311-322.

Salat DH, Kaye JA, Janowsky JS (2001). Selective preservation and degeneration within the prefrontal cortex in aging and Alzheimer disease. *Arch Neurol*, 58(9): 1403-1408.

Sanches M, Caetano S, Nicoletti M, Monkul ES, Chen HH, Hatch JP, Yeh P-H, Mullis RL, Keshevan MS, Rajkowska G, Soares JC (2009). An MRI-based approach for the

measurement of the dorsolateral prefrontal cortex in humans. *Psychiatry Res*, 173(2): 150-154.

Sanfilippo M, Lafargue T, Rusinek H, Arena L, Loneragan C, Lautin A, Feiner D, Rotrosen J, Wolkin A (2000). Volumetric measure of the frontal and temporal lobe regions in schizophrenia: relationship to negative symptoms. *Arch Gen Psychiatry*, 57(5): 471-480.

Sarkisov S A, Filimonoff IN, Preobrashenskaya NS (1949). *Cytoarchitecture of the Human Cortex Cerebri*. Medgiz, Moscow.

Schlaepfer TE, Harris GJ, Tien AY, Peng LW, Lee S, Federman EB, Chase GA, Barta PE, Pearlson GD (1994). Decreased regional cortical gray matter volume in schizophrenia. *Am J Psychiatry*, 151: 842-848.

Seidman LJ, Yurgelun-Todd D, Kremen WS, Woods BT, Goldstein JM, Faraone SV, Tsuang MT (1994). Relationship of prefrontal and temporal lobe MRI measures to neuropsychological performance in chronic schizophrenia. *Biol Psychiatry*, 35(4): 235-246.

Seidman LJ, Valera EM., Makris N, Monuteaux MC, Boriol DL, Kelkar K, Kennedy DN, Caviness VS, Bush G, Aleari M, Faraone SV, Biederman J (2006). Dorsolateral prefrontal and anterior cingulate cortex volumetric abnormalities in adults with attention-deficit/hyperactivity disorder identified by magnetic resonance imaging. *Biol Psychiatry*, 60(10): 1071-1080.

Semendeferi K, Armstrong E, Schleicher A, Zilles K, Van Hoesen GW (2001). Prefrontal cortex in humans and apes: a comparative study of area 10. *Am J Phys Anthropol*, 114(3): 224-241.

Semendeferi K, Damasio H, Frank R, Van Hoesen GW (1997). The evolution of the frontal lobes: a volumetric analysis based on three-dimensional reconstructions of magnetic resonance scans of human and ape brains. *J Hum Evol*, 32(4): 375-388.

Schenker NM, Desgouttes A-M, Semendeferi K (2005). Neural connectivity and cortical substrates of cognition in hominoids. *J Hum Evol*, 49(5): 547-569.

Shallice T, Stuss DT, Picton TW, Alexander MP, Gillingham S (2008). Mapping task switching in frontal cortex through neuropsychological group studies. *Front Neurosci*, 2(1): 79-85.

Smith GE (1907). A new topographical survey of the human cerebral cortex, being an account of the distribution of the anatomically distinct cortical areas and their relationship to the cerebral sulci. *J Anat Physiol*, 41(4): 237-254.

Sowell ER, Trauner DA, Gamst A, Jernigan TL (2002). Development of cortical and subcortical brain structures in childhood and adolescence: a structural MRI study. *Develop Med Child Neurol*, 44(1): 4-16.

Suga M, Yamasue H, Abe O, Yamasaki S, Yamada H, Inoue H, Takei K, Aoki S, Kasai K (2010). Reduced gray matter volume of Brodmann's Area 45 is associated with severe psychotic symptoms in patients with schizophrenia. *Eur Arch Psychiatry Clin Neurosci*, 260: 465-473.

Suzuki M, Zhou S-Y, Takahashi T, Hagino H, Kawasaki Y, Niu L, Matsui M., Seto H, Kurachi M (2005). Differential contributions of prefrontal and temporolimbic pathology to mechanisms of psychosis. *Brain*, 128(9): 2109-2122.

- Szeszko PR, Bilder RM, Lencz T, Pollack S, Alvir JM, Ashtari M, Wu H, Lieberman JA (1999a). Investigation of frontal lobe subregions in first-episode schizophrenia. *Psychiatry Res*, 90(1): 1-15.
- Szeszko PR, Robinson D, Alvir JM, Bilder RM, Lencz T, Ashtari M, Wu H, Bogerts B (1999b). Orbital frontal and amygdala volume reductions in obsessive-compulsive disorder. *Arch Gen Psychiatry*, 56(10): 913-919.
- Takahashi T, Kawasaki Y, Kurokawa K, Hagino H, Nohara S, Yamashita I, Nakamura K, Murata M, Matsui M, Suzuki M, Seto H, Kurachi M (2002). Lack of normal structural asymmetry of the anterior cingulate gyrus in female patients with schizophrenia: a volumetric magnetic resonance imaging study. *Schizophrenia Res*, 55(1-2): 69-81.
- Takahashi T, Suzuki M, Kawasaki Y, Hagino H, Yamashita I, Nohara S, Nakamura K, Seto H, Kurachi M (2003). Perigenual Cingulate Gyrus Volume in Patients with Schizophrenia: A Magnetic Resonance Imaging Study. *Biol Psychiatry*, 53: 593-600.
- Tisserand DJ, Pruessner JC, Arigita EJS, Boxtel MPJV, Evans AC, Jolles J, Uylings HBM (2002). Regional Frontal Cortical Volumes Decrease Differentially in Aging: An MRI Study to Compare Volumetric Approaches and Voxel-Based Morphometry. *NeuroImage*, 17: 657- 669.
- Tomaiuolo F, MacDonald JD, Caramanos Z, Posner G, Chiavaras M, Evans AC, Petrides M (1999). Morphology morphometry and probability mapping of the pars opercularis of the inferior frontal gyrus: an *in vivo* MRI analysis. *Eur J Neurosci*, 11: 3033-3046.

Torrvalva T, Kipps CM, Hodges JR, Clark L, Bekinschtein T, Roca M, Calcagno ML, Manes F (2007). The relationship between affective decision-making and theory of mind in the frontal variant of fronto-temporal dementia. *Neuropsychologia*, 45(2): 342-349.

Tzourio N, Petit L, Mellet E, Orssaud C, Crivello F, Benali K, Salamon G, Mazoyer B (1997). Use of anatomical parcellation to catalog and study structure-function relationships in the human brain. *Hum Brain Mapp*, 5(4): 228-232.

Tzourio-Mazoyer N, Landeau B, Papathanassiou D, Crivello F, Etard O, Delcroix N, Mazoyer B, Joliot M (2002). Automated anatomical labeling of activations in SPM using a macroscopic anatomical parcellation of the MNI MRI single-subject brain. *NeuroImage*, 15(1): 273-89.

Unterrainer JM, Owen AM (2006). Planning and problem solving: from neuropsychology to functional neuroimaging. *J Physiol*, 99(4-6): 308-317.

Uylings HBM, Rajkowska G, Sanz-Arigita E, Amunts K, Zilles K (2005). Consequences of large interindividual variability for human brain atlases: converging macroscopical imaging and microscopical neuroanatomy. *Anat Embryology*, 210(5-6): 423-431.

Uylings HBM, Sanz-Arigita EJ, de Vos K, Pool CW, Evers P, Rajkowska G (2010). 3-D cytoarchitectonic parcellation of human orbitofrontal cortex correlation with postmortem MRI. *Psychiatry Res*, 183(1): 1-20.

van Elst, LTV, Hesslinger B, Thiel T, Geiger E, Haegele K, Lemieux L, Lieb K, Bohus M, Hennig J, Ebert D (2003). Frontolimbic brain abnormalities in patients with borderline

personality disorder: A volumetric magnetic resonance imaging study. *Biol Psychiatry*, 54(2): 163-171.

Van Petten C, Plante E, Davidson PSR, Kuo TY, Bajuscak L, Glisky EL (2004). Memory and executive function in older adults: Relationships with temporal and prefrontal gray matter volumes and white matter hyperintensities. *Neuropsychologia*, 42: 1313-1335.

Vogt BA, Nimchinsky EA, Vogt LJ, Hof PR (1995). Human cingulate cortex: Surface features, flat maps, and cytoarchitecture. *J Comp Neurol*, 359: 490-506.

Vogt BA (2008). Architecture, cytology and comparative organization of primate cingulate cortex. In Vogt B (ed), *Cingulate Neurobiology and Disease*. Oxford University Press, Oxford.

Volle E, Gilbert SJ, Benoit RG, Burgess PW (2010). Specialization of the rostral prefrontal cortex for distinct analogy processes. *Cereb Cortex*, 20(11): 2647-2659.

von Economo C, Koskinas G N (1925). *Die Cytoarchitektonik der Hirnrinde des erwachsenen Menschen*. Springer, Berlin.

Walker AE (1940). A cytoarchitectural study of the prefrontal area in the macaque monkey. *J Comp Neurol*, 73(1): 59-86.

Whiting P, Rutjes AWS, Reitsma JB, Bossuyt PMM, Kleijnen J (2003). The development of QUADAS: a tool for the quality assessment of studies of diagnostic accuracy included in systematic reviews. *BMC Med Res Methodol*, 3:25.

Wible CG, Shenton ME, Fischer IA, Allard JE, Kikinis R, Jolesz FA, Iosifescu DV, McCarley RW (1997). Parcellation of the human prefrontal cortex using MRI. *Psychiatry Res: Neuroimaging*, 76: 29-40.

Wible CG, Shenton ME, Hokama H, Kikinis R, Jolesz FA, Metcalf D, Mccarley RW (1995). Prefrontal cortex and schizophrenia. *Arch Gen Psychiatry*, 52: 279-288.

Wilde EAA, Hunter JV, Newsome MR, Schiebel RS, Bigler ED, Johnson JL, Fearing MA, Cleavinger HB, Li X, Swank PR, Pedroza C, Roberson GS, Bachevalier J, Levin HS (2005). Frontal and temporal morphometric findings on MRI in children after moderate to severe traumatic brain injury. *J Neurotrauma*, 22(3): 333-344.

Woodward SH, Kaloupek DG, Streeter CC, Martinez C, Schaer M, Eliez S (2006). Decreased anterior cingulate volume in combat-related PTSD. *Biol Psychiatry*, 59(7): 582-587.

Yamasaki S, Yamasue H, Abe O, Suga M, Yamada H, Inoue H, Kuwabara H, Kawakubo Y, Yahata N, Aoki S, Kano Y, Kato N, Kasai K (2010). Reduced gray matter volume of pars opercularis is associated with impaired social communication in high-functioning autism spectrum disorders. *Biol Psychiatry* 68(12): 1141-1147.

Yamasue H, Iwanami A, Hirayasu Y, Yamada H, Abe O, Kuroki N, Fukuda R, Tsujii K, Aoki S, Ohtomo K, Kato N, Kasai K (2004). Localized volume reduction in prefrontal, temporolimbic, and paralimbic regions in schizophrenia: an MRI parcellation study. *Psychiatry Res*, 131(3): 195-207.

Yücel M, McKinnon MC, Chahal R, Taylor VH, Macdonald K, Joffe R, MacQuenn GM (2008).

Anterior cingulate volumes in never-treated patients with major depressive disorder.

Neuropsychopharmacology, 33: 3157-3163.

Yücel M, Stuart GW, Maruff P, Velakoulis D, Crowe SF, Savage G, Pantelis, C (2001).

Hemispheric and gender-related differences in the gross morphology of the anterior cingulate/paracingulate cortex in normal volunteers: an MRI morphometric study. *Cereb*

Cortex 11(1): 17-25.

Zald DH (2007). Orbital versus dorsolateral prefrontal cortex: Anatomical insights into content

versus process differentiation models of the prefrontal cortex. *Ann NY Acad Scis*, 1121:

395-406.

Zhou S-Y, Suzuki M, Hagino H, Takahashi T, Kawasaki Y, Matsui M, Seto H, Kurachi M

(2005). Volumetric analysis of sulci/gyri defined in vivo frontal lobe regions in

schizophrenia: Precentral gyrus, cingulate gyrus, and prefrontal region. *Psychiatry Res:*

Neuroimaging, 139: 127-139.

Zilles, K, Amunts K (2010). Centenary of Brodmann's map--conception and fate. *Nature Rev*

Neurosci, 11(2): 139-145.

Zuffante P, Leonard CM, Kuldau JM, Bauer RM, Doty EG, Bilder RM (2001). Working memory

deficits in schizophrenia are not necessarily specific of associated with MRI-based

estimates of area 46 volumes. *Psychiatry Res Neuroimaging*, 108: 187-209.